

PATIENT

Koko Rafia al Qemzi

SPECIES

Feline

BREED

Mix

SEX

Female

AGE

7 years

WEIGHT

4.1 kg

INTERPRETED BY

Dr. Lawrence McGill,
DVM, Ph.D., Diplomate,
ACVP

IMAGING PERFORMED BY

Dr. Hamza

HOSPITAL NAME

Creekside VC

REFERRING VET

Dr. Hamza

INVOICE

69843

DATE

1/6/26

PRESENTING CLINICAL SIGNS

History: A 7-year-old spayed female domestic cat was presented for evaluation of a palpable mass located adjacent to the right caudal (last) mammary gland. Cat is losing weight as well, thyroid and fructosamine is normal, On and off cat has constipation. FCoV positive, FIV, FeLV negative. On physical examination, the mass was firm to hard on palpation, well circumscribed, and freely movable with no obvious attachment to underlying tissues or overlying skin. No ulceration or discharge was noted. A fine-needle aspirate of the mass was obtained and submitted for cytologic evaluation to characterize the lesion and guide further diagnostic and therapeutic planning.

CYTOLOGY SUBMISSION

FNA of the mammary area was submitted

OBSERVATIONS

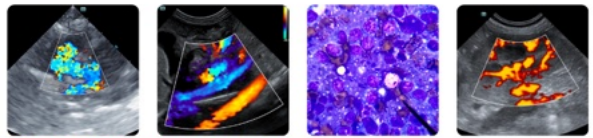
Mammary area aspirate: Submitted are 38 very good images of excellent collections of cells from the mammary area aspirate from Koko. The cellularity is rather consistent and prominent throughout these images. Where cells can be visualized, they are round cells with minimal cytoplasm. Where cytoplasm is present, it is blue gray. There are many cells that have minimal cytoplasm and occasionally these cells are aggregated. Smudge debris and scattered neutrophils and macrophages are observed. The major cellularity however appears to be round cells.

INTERPRETATION OF FINDINGS & FURTHER RECOMMENDATIONS

Mammary area aspirate - Round cell proliferation suggesting lymphoma or a possible severe lymphoid nodule.

COMMENTS

The cellularity on the collection submitted is almost all intermediate to large lymphoid cells with scattered small lymphocytes and minimal inflammation. I had expected to see large numbers of epithelial cells but I was unable to identify those in this collection. There are some aggregates of cells that could be aggregated lymphocytes in this collection. Many of the cells are large lymphoid cells suggesting a high-grade lymphoma. My concern is that there may be lymphoma internally and this is the first expression externally. Biopsy of the sample and evaluating the internal organs with radiography or ultrasound is encouraged to determine whether there is involvement of other organs with a potential lymphoma. A guarded to unfavorable prognosis is warranted until the cellularity in this collection can be confirmed. Again, I was expecting epithelial cells and a mammary carcinoma but those cells were not identified in this excellent collection. There are cases of carcinoma that have extensive inflammation and it could be lymphoid in nature but the cells in this collection appear to be more atypical suggesting lymphoma.



PATIENT

Koko Rafia al Qemzi

SPECIES

Feline

BREED

Mix

SEX

Female

AGE

7 years

WEIGHT

4.1 kg

INTERPRETED BY

Dr. Lawrence McGill,
DVM,Ph.D.,Diplomate,
ACVP

IMAGING PERFORMED BY

Dr. Hamza

HOSPITAL NAME

Creekside VC

REFERRING VET

Dr. Hamza

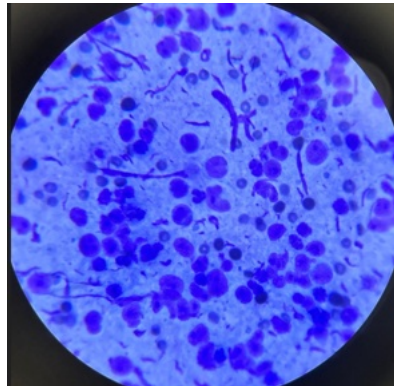
INVOICE

69843

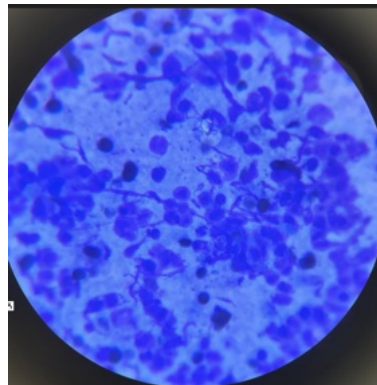
DATE

1/6/26

CYTOLOGY IMAGE



This is an image of cells spread out that have the appearance of lymphoid cells. There are smudge cells and scattered inflammatory cells in this collection from Koko.



This is a second image demonstrating large numbers of round cells collected from the abdominal mammary region on Koko. Even aggregates of cells appear to be round cells.

The information and recommendations provided are based on the images presented by the referring veterinarian/sonographer. No evaluation can be communicated regarding pathology that was not visible in the image/video clips provided.

Thank you for this referral. If the clinical or image interpretation does not parallel your findings or if I can be of any further assistance please contact me.

L.D. McGill, DVM, Ph.D., DACVP

8288 Top of the World Dr. Cottonwood Heights, UT 84121

Cell: 801-865-1220 Ldmcgill.vetpath@gmail.com