



## PATIENT

Nova 120409

## SPECIES

Feline

## BREED

Domestic Longhair

## SEX

Female

## AGE

6 years

## WEIGHT

4.65 lbs

## INTERPRETED BY

Dr. Lawrence McGill,  
DVM,Ph.D.,Diplomate,  
ACVP

## IMAGING PERFORMED BY

Dr. Inam

## HOSPITAL NAME

Pawsitive Veterinary  
Clinic Dubai Silicon  
Oasis

## REFERRING VET

Dr. Inam

## INVOICE

70855

## DATE

1/22/26

## PRESENTING CLINICAL SIGNS

- The patient was diagnosed with mass of the left caudal lung lobe. The RDVM requested FNA before lung lobectomy. Ultrasound guided FNA of the mass was done and submitted for interpretation

## CYTOLOGY SUBMISSION

FNA of the lung lobe masses were submitted

## OBSERVATIONS

Lung lobes mass: Submitted are 74 very good images of minimal numbers of cells collected from the lung lobes mass in Nova. The cellularity is mixed including good collections of macrophages that have a foamy cytoplasm. There are scattered lymphocytes and good numbers of neutrophils throughout the collection. I did not identify any bacteria. There are no changes that would support malignancy in this collection. Inflammation is the major process.

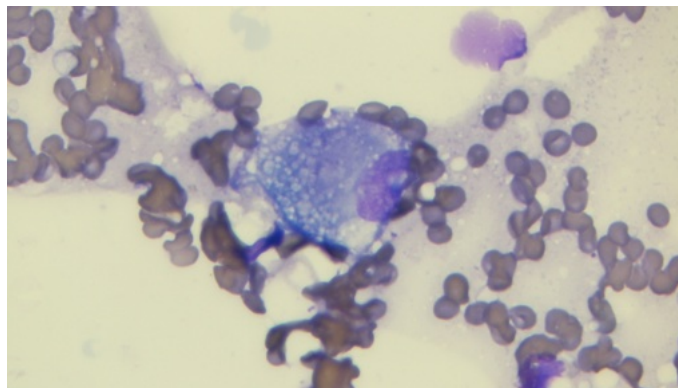
## INTERPRETATION OF FINDINGS & FURTHER RECOMMENDATIONS

Lung lobes mass - Pyogranulomatous inflammation with vacuolated macrophages.

## COMMENTS

The cellularity supports a chronic inflammatory process. This could be the result of aspiration pneumonia or could be the result of some type of inhalation of atypical material. I did not identify any bacteria but they could be involved. Malignancy is not identified in this cellular collection but inflammation is prominent. Treatment with anti-inflammatory products and antibiotics may be beneficial. Excision may be required particularly if this is some type of foreign material aspiration. A guarded prognosis is warranted in light of the chronic inflammation present.

## CYTOLOGY IMAGE



This is an image demonstrating one of the macrophages with the vacuolated cytoplasm collected from the lung in Nova.



## PATIENT

Nova 120409

## SPECIES

Feline

## BREED

Domestic Longhair

## SEX

Female

## AGE

6 years

## WEIGHT

4.65 lbs

## INTERPRETED BY

Dr. Lawrence McGill,  
DVM, Ph.D., Diplomate,  
ACVP

## IMAGING PERFORMED BY

Dr. Inam

## HOSPITAL NAME

Pawsitive Veterinary  
Clinic Dubai Silicon  
Oasis

## REFERRING VET

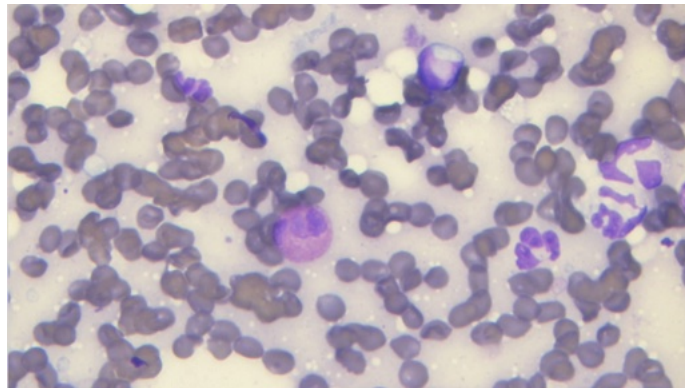
Dr. Inam

## INVOICE

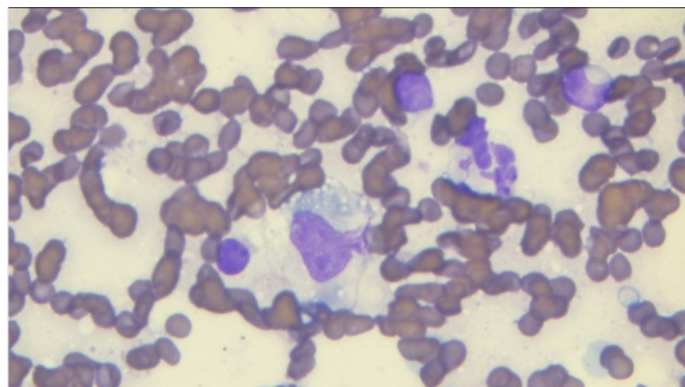
70855

## DATE

1/22/26



This is one of the images that demonstrates a hemodiluted collection with neutrophils and an eosinophil and lymphocytes collected from the lung mass in Nova.



This is an image of mixed cells with a macrophage with foamy cytoplasm including neutrophils and lymphocytes collected from the lung mass in Nova.

**The information and recommendations provided are based on the images presented by the referring veterinarian/sonographer. No evaluation can be communicated regarding pathology that was not visible in the image/video clips provided.**

Thank you for this referral. If the clinical or image interpretation does not parallel your findings or if I can be of any further assistance please contact me.

**L.D. McGill, DVM, Ph.D., DACVP**

8288 Top of the World Dr. Cottonwood Heights, UT 84121

Cell: 801-865-1220 [Ldmcgill.vetpath@gmail.com](mailto:Ldmcgill.vetpath@gmail.com)