



PATIENT

Simba Jeffery

SPECIES

Feline

BREED

Scottish Fold

SEX

Male

AGE

5 years

WEIGHT

5.4 lbs

INTERPRETED BY

Dr. Lawrence McGill,
DVM,Ph.D.,Diplomate,
ACVP

IMAGING PERFORMED BY

Dr. Waseem

HOSPITAL NAME

Pawsitive Veterinary
Clinic Dubai Silicon
Oasis

REFERRING VET

Dr. Waseem

INVOICE

70308

DATE

1/20/26

PRESENTING CLINICAL SIGNS

The patient has been diagnosed with meningoencephalitis .The patient became acutely anemic , HCT 22% . Blood smear has been submitted for evaluation

CYTOLOGY SUBMISSION

Blood smear was submitted

OBSERVATIONS

Blood smear: Submitted are 19 very good images and images that are slightly out of focus collected from the blood in Simba. There are excellent smears with scattered nucleated cells. The red blood cells demonstrate mild pleomorphism. There are scattered red blood cells that have structures suggesting hemotropic mycoplasma and one or two red blood cells that have structures that suggest babesia. The images are slightly out of focus and thus these structures are difficult to confirm but they are suggested. There is no suggestion of malignancy.

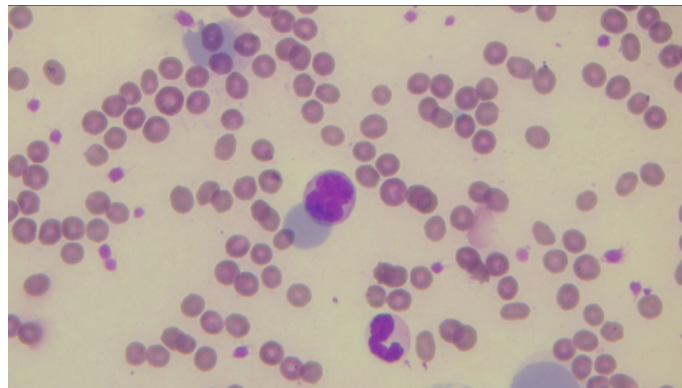
INTERPRETATION OF FINDINGS & FURTHER RECOMMENDATIONS

Blood smear - Structures suggesting Babesia and hemotropic mycoplasma.

COMMENTS

The structures observed and described suggest the possibility of heat parasites in Simba. Further evaluation is encouraged. The images are slightly out of focus and thus not as clear as I would like to see to make a specific diagnosis. Often it requires microscopic evidence going up and down through focusing. Further evaluation may require PCR testing for these organisms if desired. A guarded prognosis is warranted with the presence of these structures.

CYTOLOGY IMAGE



This is an image of red blood cells demonstrating adequate platelets and scattered leukocytes with structures suggestive of hemotropic mycoplasma collected from Simba.



PATIENT

Simba Jeffery

SPECIES

Feline

BREED

Scottish Fold

SEX

Male

AGE

5 years

WEIGHT

5.4 lbs

INTERPRETED BY

Dr. Lawrence McGill,
DVM, Ph.D., Diplomate,
ACVP

IMAGING PERFORMED BY

Dr. Waseem

HOSPITAL NAME

Pawsitive Veterinary
Clinic Dubai Silicon
Oasis

REFERRING VET

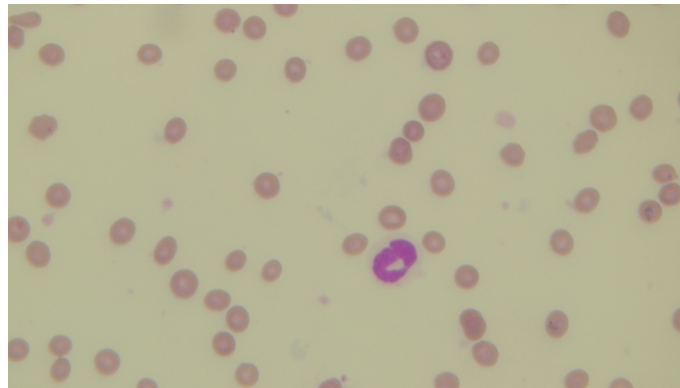
Dr. Waseem

INVOICE

70308

DATE

1/20/26



This is an image of the red blood cells Collected from Simba with a potential red blood cell infected with Babesia in the lower right.

The information and recommendations provided are based on the images presented by the referring veterinarian/sonographer. No evaluation can be communicated regarding pathology that was not visible in the image/video clips provided.

Thank you for this referral. If the clinical or image interpretation does not parallel your findings or if I can be of any further assistance please contact me.

L.D. McGill, DVM, Ph.D., DACVP

8288 Top of the World Dr. Cottonwood Heights, UT 84121

Cell: 801-865-1220 Ldmcgill.vetpath@gmail.com