

PATIENT

Bambino Cara

SPECIES

Canine

BREED

Maltese

SEX

Neutered male

AGE

13 years

WEIGHT

21.4 lbs

INTERPRETED BY

Dr. Lawrence McGill,
DVM, Ph.D., Diplomate,
ACVP

IMAGING PERFORMED BY

Christine LVT

HOSPITAL NAME

Rotterdam VH

REFERRING VET

Dr. Sarah Kopa

INVOICE

70276

DATE

1/19/26

PRESENTING CLINICAL SIGNS

- Large 10cm x 9.4cm x 4.5cm mass on back. Has grown in size.

CYTOLOGY SUBMISSION

FNA of the mass on the patient's back was submitted

OBSERVATIONS

Mass on back: Submitted are 10 good images of collections of cells and material from the back on Bambino. The cellularity is fairly consistent with elongated to rounded nuclear structures associated with prominent cytoplasm. There are scattered aggregates of red blood cells and apparent hemosiderin. Malignant characteristics are not confirmed in the collection and some of these cells are vacuolated. The vacuoles are irregular.

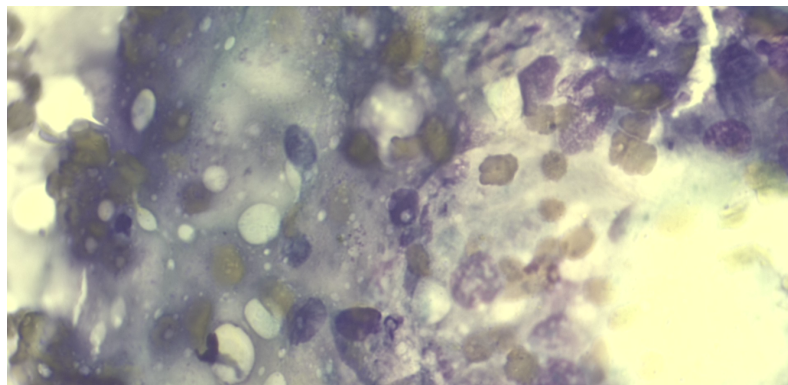
INTERPRETATION OF FINDINGS & FURTHER RECOMMENDATIONS

Mass on back - Good collections of cells suggesting macrophages and granulomatous inflammation or a possible irregular liposarcoma.

COMMENTS

The cellularity is very consistent throughout this collection. My concern is that there is inflammation and granulomatous change but this may be secondary to problems inside a neoplastic process. Some necrosis would go along with that change as well. I did not identify changes of malignancy but I cannot completely rule that diagnosis out since the mass is so large. Often the center of a mass is necrotic and easier to collect than the edges where the neoplastic cells are identified. Excision of the mass is definitely in order with a follow-up biopsy. These changes could be secondary or primary but with the size of this mass, excision is certainly in order. A guarded prognosis is warranted until the source of the mass can be confirmed.

CYTOLOGY IMAGE





PATIENT

Bambino Cara

This is an image demonstrating a representative field of cells which have the appearance of macrophages with degeneration. This could also be the result of a liposarcoma but I cannot make that diagnosis on this collection from Bambino.

SPECIES

Canine

The information and recommendations provided are based on the images presented by the referring veterinarian/sonographer. No evaluation can be communicated regarding pathology that was not visible in the image/video clips provided.

BREED

Maltese

Thank you for this referral. If the clinical or image interpretation does not parallel your findings or if I can be of any further assistance please contact me.

SEX

Neutered male

L.D. McGill, DVM, Ph.D., DACVP

AGE

13 years

8288 Top of the World Dr. Cottonwood Heights, UT 84121

Cell: 801-865-1220 Ldmcgill.vetpath@gmail.com

WEIGHT

21.4 lbs

INTERPRETED BY

Dr. Lawrence McGill,
DVM, Ph.D., Diplomate,
ACVP

IMAGING PERFORMED BY

Christine LVT

HOSPITAL NAME

Rotterdam VH

REFERRING VET

Dr. Sarah Kopa

INVOICE

70276

DATE

1/19/26