



**PATIENT**

Ruffian Parmar

**SPECIES**

Canine

**BREED**

Whippet

**SEX**

Spayed Female

**AGE**

9 Years

**WEIGHT**

18.8 kg

**INTERPRETED BY**

Laurent Locquet, DVM,  
MRCVS, GPCert, (VC)  
Diplomate, ECVIM-CA

**IMAGING PERFORMED BY**

Dave Stasiuk RDMS,  
RDCS, RTR

**HOSPITAL NAME**

Aspen AH

**REFERRING VET**

Dr. B. Ross

**INVOICE**

35677

**DATE**

11/27/25

**PRESENTING CLINICAL SIGNS**

History: Stage B1 disease in May 2024. Assess for progression. Previous echo reported by Dr. Machen Lamy. No symptoms. Not pre GA.

**ULTRASONOGRAPHIC EXAMINATION OF THE HEART**

CANINE CARDIAC PARAMETERS	MR VMAX (m/s)	TR VMAX (m/s)	LA/AO (M-Mode)	LA/AO (Heart Base; Swe)	FS (%)	EF (%)	EPSS (cm)
NORMAL PARAMETER	4.5-5.5	<2.7	1.3	Up to 1.6	28-40	40-100	<0.6
PATIENT	4.5	2.33	1.56	1.29	42	73	0.36
CANINE CARDIAC PARAMETERS	HR (BPM)	AV VMAX (m/s)	PV MAX (m/s)	BODY WEIGHT (kg)	LAD LA MAX 4 Chamber	LVIDd Avg; 2D and m-mode short axis (cm)	LVIDs Avg; 2D and m-mode short axis (cm)
NORMAL PARAMETER	50-100	0.7-1.7	0.7-1.6				
PATIENT	--	1.01	0.99	18.8	--	4.04	2.36

**Cardiac Presentation**

The mitral valve leaflets are mildly thickened with mild mitral regurgitation posteriorly directed. There is no prolapse of the mitral valve leaflet. The left atrial size is normal. Left ventricular internal dimensions during diastole are within normal limits and systolic function is preserved in the face of mitral regurgitation. There is normal right atrial size with mild tricuspid regurgitation. There is no prolapse of the tricuspid valve leaflets and no evidence of pulmonary hypertension based upon tricuspid regurgitant velocities. The right ventricle subjectively appears normal in structure and function. The aortic and pulmonic valves have normal morphology and the corresponding outflow velocities are within normal limits. There is no evidence of pulmonic or aortic insufficiency. The aorta appears normal. The pulmonary artery and associated branches appear normal. There is no evidence of pleural effusion, pericardial effusion, or intracardiac masses.

**ULTRASONOGRAPHIC FINDINGS**

- ACVIM myxomatous mitral valve disease, stage B1 with moderate to severe mitral regurgitation and mild tricuspid regurgitation, similar to last scan.

**INTERPRETATION OF THE FINDINGS & FURTHER RECOMMENDATIONS**

Recheck is recommended in one year. No medications are necessary.



**PATIENT**

Ruffian Parmar

**SPECIES**

Canine

**BREED**

Whippet

**SEX**

Spayed Female

**AGE**

9 Years

**WEIGHT**

18.8 kg

**INTERPRETED BY**

Laurent Locquet, DVM,  
MRCVS, GPCert, (VC)  
Diplomate, ECVIM-CA

**IMAGING PERFORMED BY**

Dave Stasiuk RDMS,  
RDCS, RTR

**HOSPITAL NAME**

Aspen AH

**REFERRING VET**

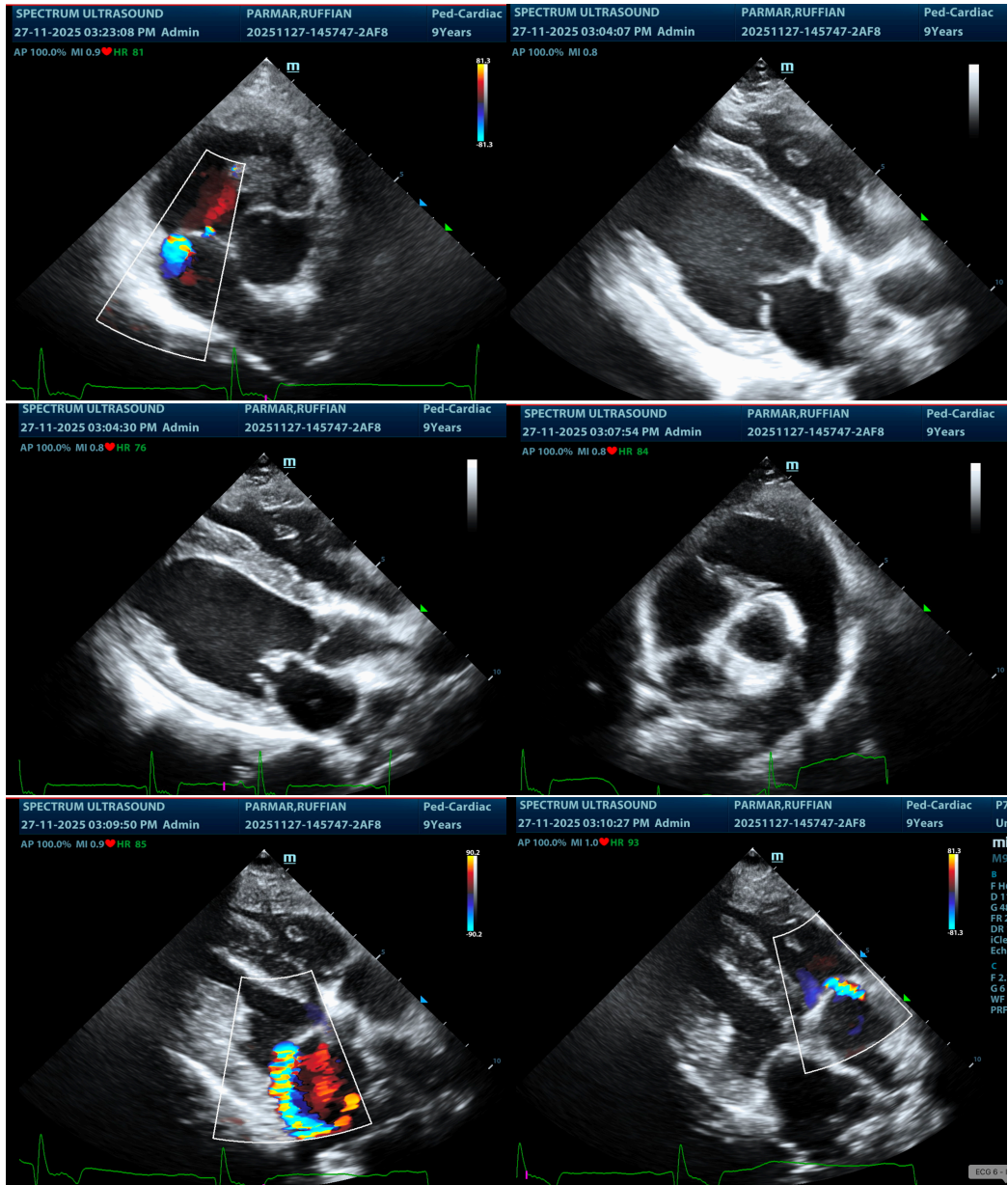
Dr. B. Ross

**INVOICE**

35677

**DATE**

11/27/25





## PATIENT

Ruffian Parmar

## SPECIES

Canine

## BREED

Whippet

## SEX

Spayed Female

## AGE

9 Years

## WEIGHT

18.8 kg

## INTERPRETED BY

Laurent Locquet, DVM,  
MRCVS, GPCert, (VC)  
Diplomate, ECVIM-CA

## IMAGING PERFORMED BY

Dave Stasiuk RDMS,  
RDCS, RTR

## HOSPITAL NAME

Aspen AH

## REFERRING VET

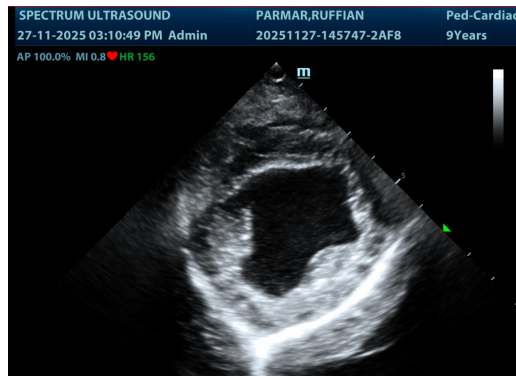
Dr. B. Ross

## INVOICE

35677

## DATE

11/27/25



The information and recommendations provided are based on the images presented by the referring veterinarian/sonographer. No evaluation can be communicated regarding pathology that was not visible in the image/video clips provided.

Thank you for this referral. If the clinical or image interpretation does not parallel your findings or if I can be of any further assistance please contact me.

Laurent Locquet, DVM, MRCVS, GPCert, (VC) Diplomate, ECVIM-CA

[info@SonoPath.com](mailto:info@SonoPath.com)