



PATIENT

Peat Bog Lenihan

SPECIES

Feline

BREED

DMH

SEX

Neutered Male

AGE

3 Years

WEIGHT

11.3 Pounds

INTERPRETED BY

Laurent Locquet, DVM,
MRCVS, GPCert, (VC)
Diplomate, ECVIM-CA

IMAGING PERFORMED BY

Karen Ebersole DVM
DABVP (Canine &
Feline)

HOSPITAL NAME

Scanvet

REFERRING VET

Dr. Golden

INVOICE

37326

DATE

6/3/26

PRESENTING CLINICAL SIGNS

History of a HM and asthma. Fluticasone inhaler BID, Albuterol prn/occasionally. No sedation for echo. Abnormal PE/Chem/CBC/UA Results: PE: Grade 3/6 systolic heart murmur. CBC/Chem - NSF Felv/FIV/HW - Neg x 3.

ULTRASONOGRAPHIC EXAMINATION OF THE HEART

FELINE CARDIAC PARAMETERS	BODY WEIGHT (lbs)	HR (BPM)	IVSd (cm)	LVIDd (cm)	LVWd (cm)	FS (%)	EF (%)
NORMAL PARAMETER	-----	150-240	0.3-0.6	1.0-2.1	0.25-0.6	35-67	80-100
PATIENT	11.3	NM	0.36	1.6	0.32	44	--
FELINE CARDIAC PARAMETERS	LA/AO (M-mode)	LA/AO HEART BASE (Sisson)	LAD LA MAX 4 Chamber	LVOT VEL. (m/s)	RVOT VEL. (m/s)	IVRT (m/)	
NORMAL PARAMETER	<1.5	1.6		<1.6	<1.3	40-60	
PATIENT	1.07	1.35	13.5 mm	1.18	1.13	NM	
Adapted from June Boon, Veterinary Echocardiography, 1998 Sisson D et al. JVIM 1991; 5: 232, Jacobs et al. Am J Vet Res 1985; 46:1705							

Cardiac Presentation

The echocardiogram demonstrated normal left atrial size based on three separate measurements, including LAD (left atrial diameter), and LA/Ao using both the Swedish method and the method described by Boon. The cranial and caudal mitral valve leaflets appeared normal in 2D, and color Doppler revealed no mitral valve insufficiency. The left ventricle appeared normal, with normal thickness of both the left ventricular free wall and the interventricular septum. The myocardium presented as normal, without subjective evidence of significant fibrotic or ischemic disease. Contractility of the ventricular walls was adequate and within the normal range for this patient, evidenced by fractional shortening measurements and subjective evaluation of the myocardium from multiple regions and imaging angles. The LVOT demonstrated normal structural appearance in 2D, including a normal aortic valve. Color Doppler and spectral Doppler showed non-turbulent flow with normal velocities. The right atrium and right ventricle were subjectively prominent. No evidence of masses was identified. The tricuspid valve appeared normal in 2D, and color Doppler showed no tricuspid insufficiency. The pulmonic tract assessment revealed no abnormalities. The pulmonic valve appeared subjectively normal in 2D; color Doppler identified no turbulent flow, and velocities were within reference ranges. No visible pericardial or pleural effusion was noted, and no extracardiac pathology was detected in the visible imaging planes. The cranial mediastinal and pericardial regions were free of visible masses.



PATIENT

Peat Bog Lenihan

SPECIES

Feline

BREED

DMH

SEX

Neutered Male

AGE

3 Years

WEIGHT

11.3 Pounds

INTERPRETED BY

Laurent Locquet, DVM,
MRCVS, GPCert, (VC)
Diplomate, ECVIM-CA

IMAGING PERFORMED BY

Karen Ebersole DVM
DABVP (Canine &
Feline)

HOSPITAL NAME

Scanvet

REFERRING VET

Dr. Golden

INVOICE

37326

DATE

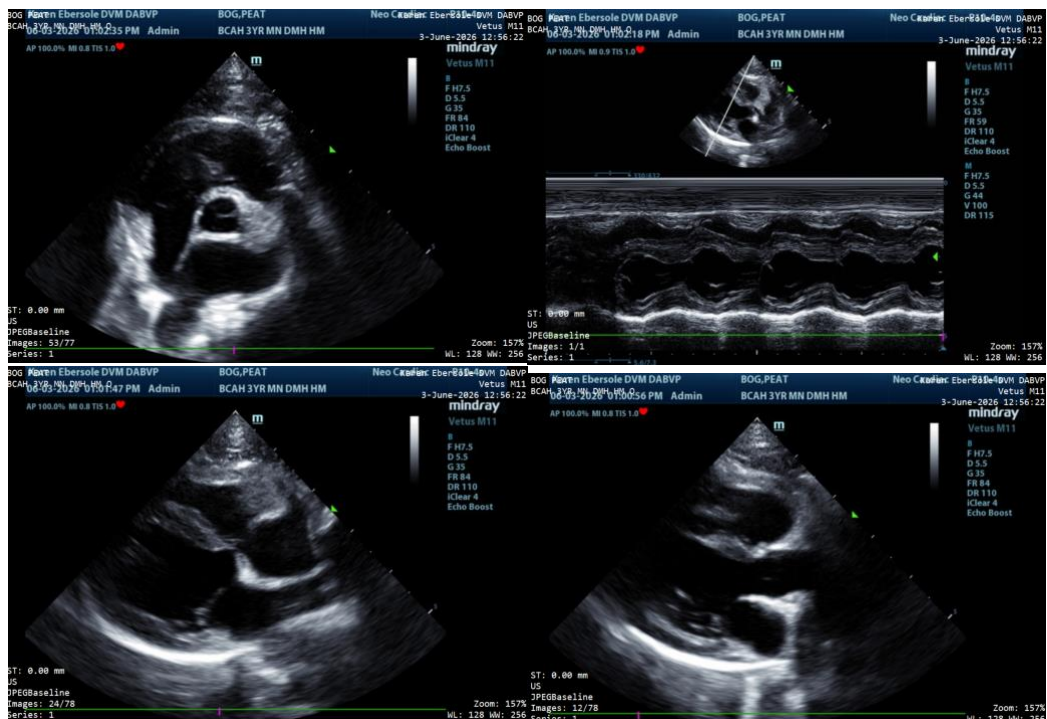
6/3/26

ULTRASONOGRAPHIC FINDINGS

- Subjectively prominent right atrium and right ventricle
- Possible idiopathic flow murmur, not hemodynamically significant

INTERPRETATION OF THE FINDINGS & FURTHER RECOMMENDATIONS

No strong contraindications to give inhaler therapy based on this examination. Recheck is recommended in one year, unless there are any concerns prior.



The information and recommendations provided are based on the images presented by the referring veterinarian/sonographer. No evaluation can be communicated regarding pathology that was not visible in the image/video clips provided.

Thank you for this referral. If the clinical or image interpretation does not parallel your findings or if I can be of any further assistance please contact me.

Laurent Locquet, DVM MRCVS GPCert (VC) Diplomate ECVIM-CA

info@SonoPath.com