



**PATIENT**

Luna Trause

**SPECIES**

Canine

**BREED**

Husky Mix

**SEX**

Spayed Female

**AGE**

15 Years 7 Months

**WEIGHT**

76 Pounds

**INTERPRETED BY**

Laurent Locquet, DVM,  
MRCVS, GPCert, (VC)  
Diplomate, ECVIM-CA

**IMAGING PERFORMED BY**

Rebecca Hamilton

**HOSPITAL NAME**

Farview AC

**REFERRING VET**

Dr. Mosaad

**INVOICE**

37298

**DATE**

6/2/26

**PRESENTING CLINICAL SIGNS**

History: Increased coughing, collapsed trachea. meds: Apoquel 16 mg 1 once a day, Cytopoint 80 mg SQ @ 9 AM.

**ULTRASONOGRAPHIC EXAMINATION OF THE HEART**

CANINE CARDIAC PARAMETERS	MR VMAX (m/s)	TR VMAX (m/s)	LA/AO (M-Mode)	LA/AO (Heart Base; Swe)	FS (%)	EF (%)	EPSS (cm)
<b>NORMAL PARAMETER</b>	4.5-5.5	<2.7	1.3	Up to 1.6	28-40	40-100	<0.6
<b>PATIENT</b>	--	--	1.00	1.10	40	72	NM
CANINE CARDIAC PARAMETERS	HR (BPM)	AV VMAX (m/s)	PV MAX (m/s)	BODY WEIGHT (lbs)	LAD LA MAX 4 Chamber	LVIDd Avg; 2D and m-mode short axis (cm)	LVIDs Avg; 2D and m-mode short axis (cm)
<b>NORMAL PARAMETER</b>	50-100	0.7-1.7	0.7-1.6				
<b>PATIENT</b>	--	1.91	0.83	76	34 mm	3.16	1.89

**Cardiac Presentation**

The left atrial size expressed both in the LA/AO ratio and LA-MAX was normal. Chamber volumes and echogenicity were normal. The mitral valve leaflets presented no abnormalities, and doppler showed no signs of insufficiency. There was no evidence of chordae tendineae rupture or mitral valve prolapse. The left ventricle presented with normal wall thicknesses, a linear contour, and was neither dilated nor restricted. The myocardium showed normal echogenicity without subjective evidence of significant fibrotic or ischemic disease. Contractility of the ventricular walls was adequate and within the normal range for this patient, supported by fractional shortening measurements and subjective evaluation of all myocardial regions. Moderate aortic valve regurgitation was noted. The right atrium and auricle revealed normal size, structure, and content. No masses or chamber overload were identified. Tricuspid valve assessment demonstrated a normal valvular structure with no signs of thickening or insufficiency on 2D or color Doppler. The right ventricle was normal in size (approximately one-third of LV diameter), with normal myocardial wall thickness and echogenicity. The pulmonary tract revealed normal valve structure, laminar flow, and a normal diameter. No pericardial or pleural effusion was noted. No echocardiographically detectable evidence of infiltrative disease was present. The cranial mediastinal and pericardial regions were free of visible masses.

**ULTRASONOGRAPHIC FINDINGS**

- Moderate aortic valve regurgitation



**PATIENT**

Luna Trause

**SPECIES**

Canine

**BREED**

Husky Mix

**SEX**

Spayed Female

**AGE**

15 Years 7 Months

**WEIGHT**

76 Pounds

**INTERPRETED BY**

Laurent Locquet, DVM,  
MRCVS, GPCert, (VC)  
Diplomate, ECVIM-CA

**IMAGING PERFORMED BY**

Rebecca Hamilton

**HOSPITAL NAME**

Farview AC

**REFERRING VET**

Dr. Mosaad

**INVOICE**

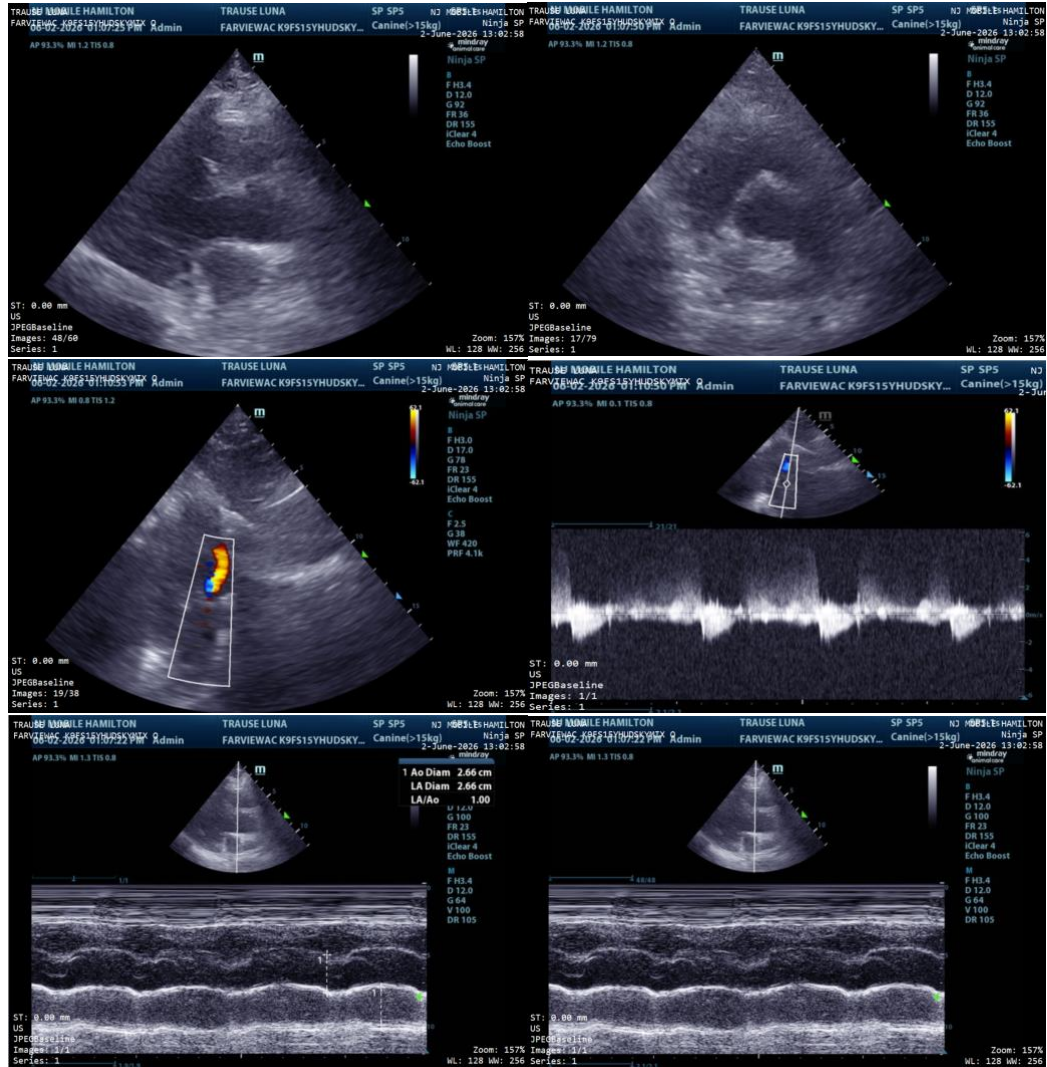
37298

**DATE**

6/2/26

**INTERPRETATION OF THE FINDINGS & FURTHER RECOMMENDATIONS**

There is no cardiac reason for the aforementioned clinical signs. No medication is necessary. Annual recheck is recommended.



The information and recommendations provided are based on the images presented by the referring veterinarian/sonographer. No evaluation can be communicated regarding pathology that was not visible in the image/video clips provided.

Thank you for this referral. If the clinical or image interpretation does not parallel your findings or if I can be of any further assistance please contact me.

**Laurent Locquet, DVM MRCVS GPCert (VC) Diplomate ECVIM-CA**



**PATIENT**

[info@SonoPath.com](mailto:info@SonoPath.com)

Luna Trause

**SPECIES**

Canine

**BREED**

Husky Mix

**SEX**

Spayed Female

**AGE**

15 Years 7 Months

**WEIGHT**

76 Pounds

**INTERPRETED BY**

Laurent Locquet, DVM,  
MRCVS, GPCert, (VC)  
Diplomate, ECVIM-CA

**IMAGING  
PERFORMED BY**

Rebecca Hamilton

**HOSPITAL NAME**

Farview AC

**REFERRING VET**

Dr. Mosaad

**INVOICE**

37298

**DATE**

6/2/26