



PATIENT

Milo Muscara

SPECIES

Feline

BREED

DSH

SEX

Neutered Male

AGE

13

WEIGHT

20.8

INTERPRETED BY

Laurent Locquet, DVM,
MRCVS, GPCert, (VC)
Diplomate, ECVIM-CA

IMAGING PERFORMED BY

Dr. Hesham Elakbawy

HOSPITAL NAME

Lincoln Avenue Cat
and Dog Hospital

REFERRING VET

Dr. Hesham Elakbawy

INVOICE

37237

DATE

5/28/26

PRESENTING CLINICAL SIGNS

History: CHF, Takes Vetmedin 1.2mg BID
furosemide 12.5 bid, abdominal ultrasound was not possible because of abdominal ascites.

ULTRASONOGRAPHIC EXAMINATION OF THE HEART

FELINE CARDIAC PARAMETERS	BODY WEIGHT	HR (BPM)	IVSd	LVIDd	LVWd	FS (%)	EF (%)
NORMAL PARAMETER	-----	150-240			0.25-0.6	35-67	80-100
PATIENT	20.8	NM	4.7 mm	13.2 mm	7.4 mm	45	--
FELINE CARDIAC PARAMETERS	LA/AO (M-mode)	LA/AO HEART BASE (Sisson)	LAD LA MAX 4 Chamber		LVOT VEL. (m/s)	RVOT VEL. (m/s)	IVRT (m/)
NORMAL PARAMETER	<1.5	1.6			<1.6	<1.3	40-60
PATIENT	2.5	--	25 mm		NM	NM	NM
Adapted from June Boon, Veterinary Echocardiography, 1998 Sisson D et al. JVIM 1991; 5: 232, Jacobs et al. Am J Vet Res 1985; 46:1705							

Cardiac Presentation

Left atrium was significantly enlarged. The mitral valve was normal. The left ventricle showed a hypertrophied free wall. The myocardium was normal. Contractility was normal. LVOT was normal. Right atrium was normal. No evidence of masses. Tricuspid valve was normal. Right ventricle was normal. Pulmonic tract was normal. No visible pericardial diffusion, but there was a lot of ascites. Cranial mediastinum and pericardial regions were free of mass in the visible windows.

ULTRASONOGRAPHIC FINDINGS

- Advanced cardiomyopathy
- Secondary significant left atrial enlargement
- Congestive heart failure with secondary ascites
- Free fluid in the abdomen.

INTERPRETATION OF THE FINDINGS & FURTHER RECOMMENDATIONS

Recommend draining the ascites. Recommend taking an ECG as well, because sometimes subjectively there seems to be a premature beat; I don't want to exclude arrhythmias. Then, recommend furosemide at a dose of 2.0 mg/kg twice per day. Then, recommend giving pimobendan at a dose of 0.25 mg/kg twice per day as well. Recommend starting clopidogrel 18.75 mg per cat, and then before



PATIENT

Milo Muscara

SPECIES

Feline

BREED

DSH

SEX

Neutered Male

AGE

13

WEIGHT

20.8

INTERPRETED BY

Laurent Locquet, DVM,
MRCVS, GPCert, (VC)
Diplomate, ECVIM-CA

IMAGING PERFORMED BY

Dr. Hesham Elakbawy

HOSPITAL NAME

Lincoln Avenue Cat
and Dog Hospital

REFERRING VET

Dr. Hesham Elakbawy

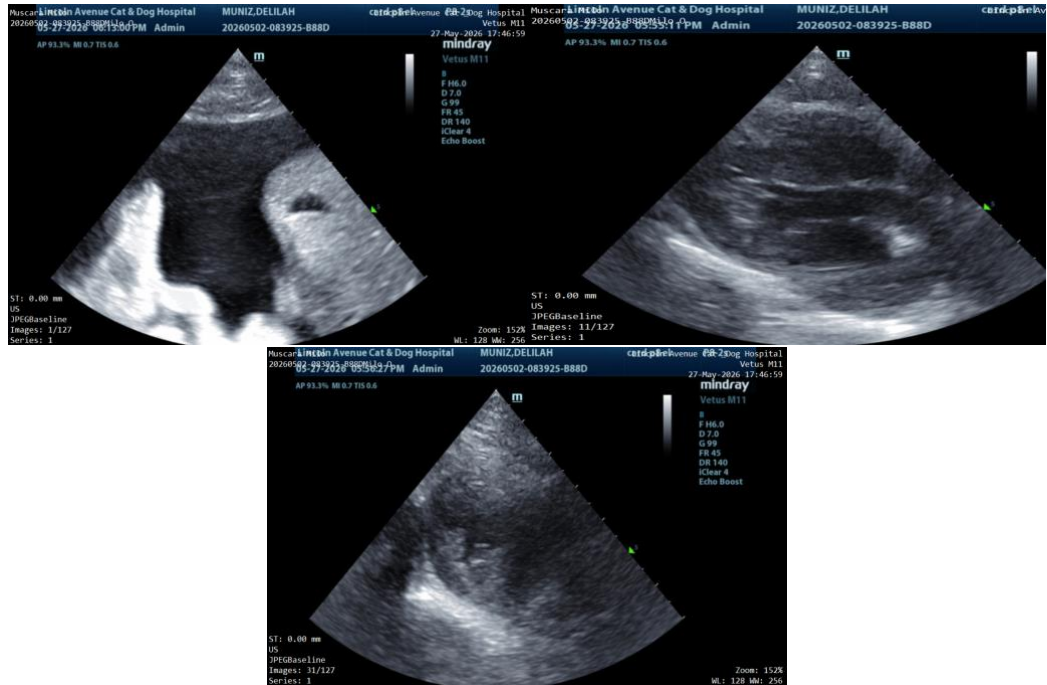
INVOICE

37237

DATE

5/28/26

sedating the cat for draining, I would take blood work, including electrolytes and creatinine values. Two weeks later, recommend rechecking for free fluid in the abdomen and rechecking the blood values.



The information and recommendations provided are based on the images presented by the referring veterinarian/sonographer. No evaluation can be communicated regarding pathology that was not visible in the image/video clips provided.

Thank you for this referral. If the clinical or image interpretation does not parallel your findings or if I can be of any further assistance please contact me.

Laurent Locquet, DVM MRCVS GPCert (VC) Diplomate ECVIM-CA

info@SonoPath.com