



PATIENT

Capone Muniz

SPECIES

Feline

BREED

Sphynx

SEX

Male

AGE

10

WEIGHT

12

INTERPRETED BY

Laurent Locquet, DVM,
MRCVS, GPCert, (VC)
Diplomate, ECVIM-CA

IMAGING PERFORMED BY

Dr. Hesham Elakbawy

HOSPITAL NAME

Lincoln Avenue Cat
and Dog Hospital

REFERRING VET

Dr. Hesham Elakbawy

INVOICE

37270

DATE

5/28/26

PRESENTING CLINICAL SIGNS

History: Has echo last year at different clinic had thickened LVW. LAW, no regurgitation, take clopidogrel 70mg 1/4 tab sid. BP 146/102 Hr 195.

ULTRASONOGRAPHIC EXAMINATION OF THE HEART

FELINE CARDIAC PARAMETERS	BODY WEIGHT	HR (BPM)	IVSd (cm)	LVIDd (cm)	LVWd (cm)	FS (%)	EF (%)
NORMAL PARAMETER	-----	150-240		1.0-2.1	0.25-0.6	35-67	80-100
PATIENT	12	NM	4.5 mm	1.51	0.58	33	--
FELINE CARDIAC PARAMETERS	LA/AO (M-mode)	LA/AO HEART BASE (Sisson)	LAD LA MAX 4 Chamber		LVOT VEL. (m/s)	RVOT VEL. (m/s)	IVRT (m/)
NORMAL PARAMETER	<1.5	1.6			<1.6	<1.3	40-60
PATIENT	NM	NM	14.9		NM	0.88	NM
Adapted from June Boon, Veterinary Echocardiography, 1998							
Sisson D et al. JVIM 1991; 5: 232, Jacobs et al. Am J Vet Res 1985; 46:1705							

Cardiac Presentation

The echocardiogram demonstrated normal left atrial size based on three separate measurements, including LAD (left atrial diameter), and LA/Ao using both the Swedish method and the method described by Boon. The cranial and caudal mitral valve leaflets appeared normal in 2D, and color Doppler revealed no mitral valve insufficiency. The left ventricle appeared normal, with normal thickness of both the left ventricular free wall and the interventricular septum. The myocardium presented as normal, without subjective evidence of significant fibrotic or ischemic disease. Contractility of the ventricular walls was adequate and within the normal range for this patient, evidenced by fractional shortening measurements and subjective evaluation of the myocardium from multiple regions and imaging angles. The LVOT demonstrated normal structural appearance in 2D, including a normal aortic valve. Color Doppler and spectral Doppler showed non-turbulent flow with normal velocities. The right atrium and auricle revealed no abnormalities. No evidence of masses was identified. The tricuspid valve appeared normal in 2D, and color Doppler showed no tricuspid insufficiency. The right ventricle was normal in size (approximately one third of the left ventricular diameter) with normal chordae structure, myocardial echogenicity, and wall thickness. The pulmonic tract assessment revealed no abnormalities. The pulmonic valve appeared subjectively normal in 2D; color Doppler identified no turbulent flow, and velocities were within reference ranges. No visible pericardial or pleural effusion was noted, and no extracardiac pathology was detected in the visible imaging planes. The cranial mediastinal and pericardial regions were free of visible masses.



PATIENT

Capone Muniz

SPECIES

Feline

BREED

Sphynx

SEX

Male

AGE

10

WEIGHT

12

INTERPRETED BY

Laurent Locquet, DVM,
MRCVS, GPCert, (VC)
Diplomate, ECVIM-CA

IMAGING PERFORMED BY

Dr. Hesham Elakbawy

HOSPITAL NAME

Lincoln Avenue Cat
and Dog Hospital

REFERRING VET

Dr. Hesham Elakbawy

INVOICE

37270

DATE

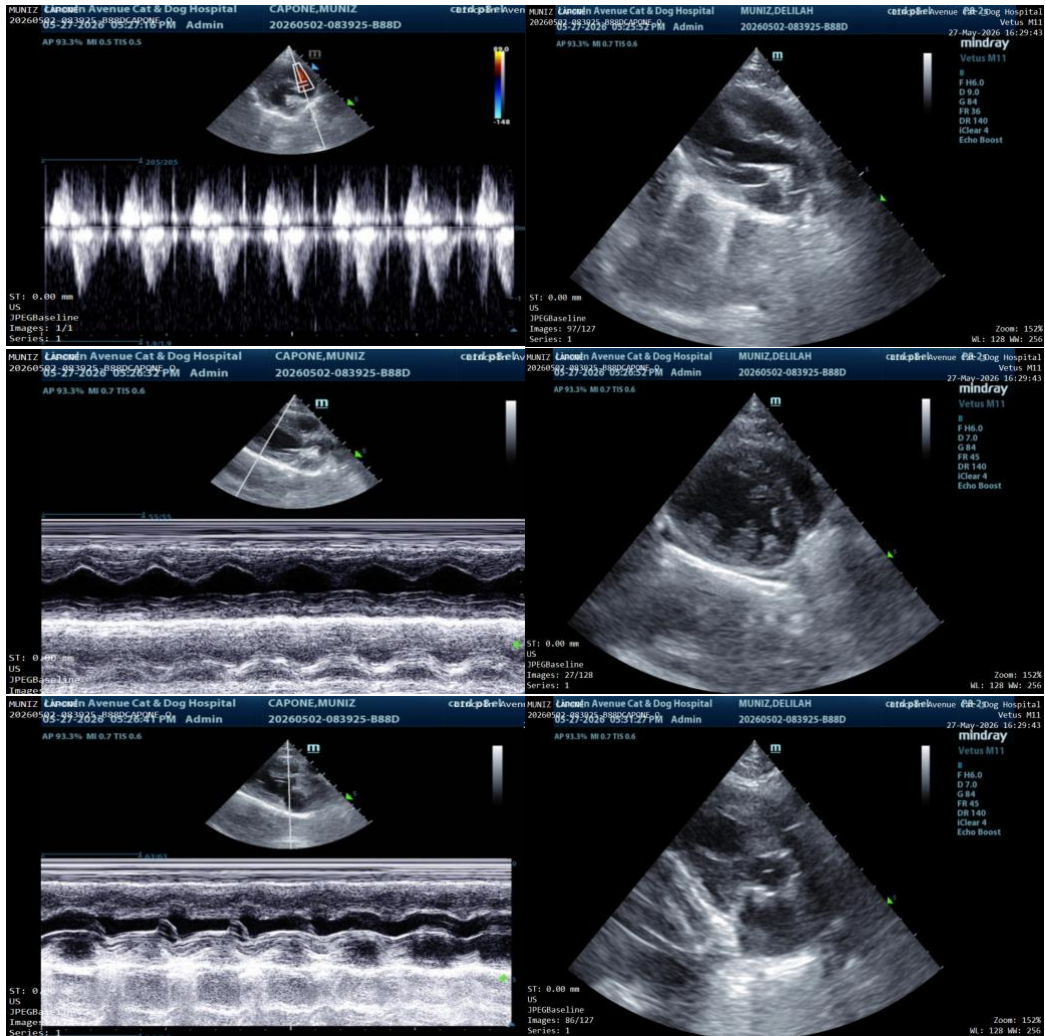
5/28/26

ULTRASONOGRAPHIC FINDINGS

- Based on this echo, there are no significant structural changes.

INTERPRETATION OF THE FINDINGS & FURTHER RECOMMENDATIONS

The medication can be stopped. Recheck is recommended in one year unless there are any concerns.





PATIENT

Capone Muniz

SPECIES

Feline

BREED

Sphynx

SEX

Male

AGE

10

WEIGHT

12

INTERPRETED BY

Laurent Locquet, DVM,
MRCVS, GPCert, (VC)
Diplomate, ECVIM-CA

IMAGING PERFORMED BY

Dr. Hesham Elakbawy

HOSPITAL NAME

Lincoln Avenue Cat
and Dog Hospital

REFERRING VET

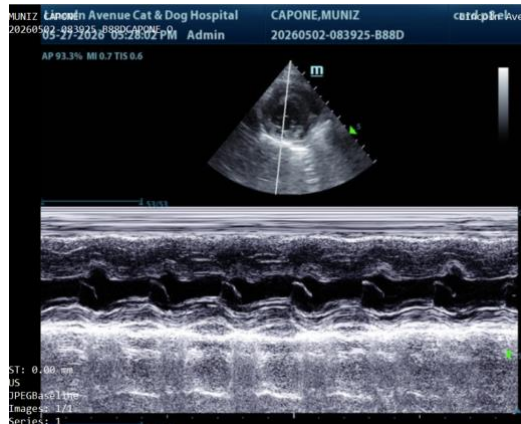
Dr. Hesham Elakbawy

INVOICE

37270

DATE

5/28/26



The information and recommendations provided are based on the images presented by the referring veterinarian/sonographer. No evaluation can be communicated regarding pathology that was not visible in the image/video clips provided.

Thank you for this referral. If the clinical or image interpretation does not parallel your findings or if I can be of any further assistance please contact me.

Laurent Locquet, DVM MRCVS GPCert (VC) Diplomate ECVIM-CA

info@SonoPath.com