



PATIENT

Tater Hunter

SPECIES

Canine

BREED

Boxer

SEX

Spayed Female

AGE

6 Years

WEIGHT

76 lbs

INTERPRETED BY

Laurent Locquet, DVM,
MRCVS, GPCert, (VC)
Diplomate, ECVIM-CA
(Cardiology)

IMAGING PERFORMED BY

Brandon Holmes

HOSPITAL NAME

Scottsdale Veterinary
Clinic

REFERRING VET

Dr. Chez Giacompetti

INVOICE

16411

DATE

05/21/26

PRESENTING CLINICAL SIGNS

History of ARVC from previous veterinarian. Requesting routine echo.

Abnormal PE/Chem/CBC/UA Results: Wellness panel attached. Only abnormality was the BNP = 913.

ULTRASONOGRAPHIC EXAMINATION OF THE HEART

CANINE CARDIAC PARAMETERS	MR VMAX (m/s)	TR VMAX (m/s)	LA/AO (M-Mode)	LA/AO (Heart Base; Swe)	FS (%)	EF (%)	EPSS (cm)
NORMAL PARAMETER	4.5-5.5	<2.7	1.3	Up to 1.6	28-40	40-100	<0.6
PATIENT	--	--	1.07	1.0	31	--	NM
CANINE CARDIAC PARAMETERS	HR (BPM)	AV VMAX (m/s)	PV MAX (m/s)	BODY WEIGHT (lbs)	LAD LA MAX 4 Chamber	LVIDd Avg; 2D and m-mode short axis (cm)	LVIDs Avg; 2D and m-mode short axis (cm)
NORMAL PARAMETER	50-100	0.7-1.7	0.7-1.6				
PATIENT	NM	1.01	0.66	76.0	3.9	4.2	2.9

Cardiac Presentation

The left atrium was normal in all 3 views. The mitral valve was normal. The left ventricle was normal. The myocardium was normal. Contractility was normal. Left ventricular outflow tract was normal. The right atrium was normal. No evidence of masses. The tricuspid valve was normal. The right ventricle was normal. The pulmonic tract was normal. No visible pericardial effusion or pleural effusion. The cranial mediastinum and pericardial regions were free of masses in the visible windows.

ULTRASONOGRAPHIC FINDINGS

- Normal cardiac structure/function.

INTERPRETATION OF THE FINDINGS & FURTHER RECOMMENDATIONS

Based on this echocardiography, there are no obvious structural or functional changes. The history reports ARVC. ARVC can be purely characterized by arrhythmia results. Therefore, a Holter monitor should be considered. Annual recheck is recommended unless there are any concerns prior. No medications are necessary at the moment.



PATIENT

Tater Hunter

SPECIES

Canine

BREED

Boxer

SEX

Spayed Female

AGE

6 Years

WEIGHT

76 lbs

INTERPRETED BY

Laurent Locquet, DVM,
MRCVS, GPCert, (VC)
Diplomate, ECVIM-CA
(Cardiology)

IMAGING PERFORMED BY

Brandon Holmes

HOSPITAL NAME

Scottsdale Veterinary
Clinic

REFERRING VET

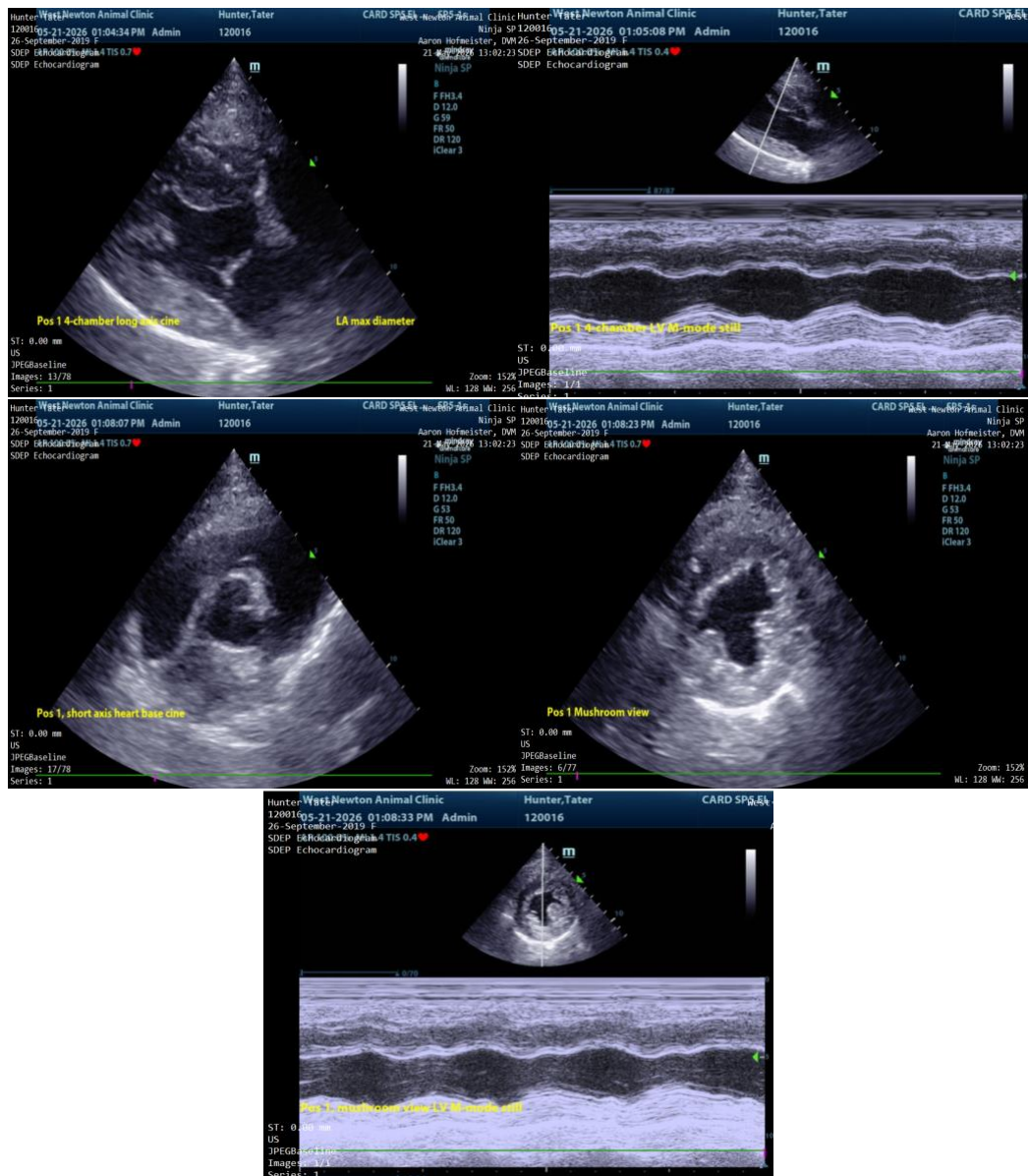
Dr. Chez Giacometti

INVOICE

16411

DATE

05/21/26



The information and recommendations provided are based on the images presented by the referring veterinarian/sonographer. No evaluation can be communicated regarding pathology that was not visible in the image/video clips provided.

Thank you for this referral. If the clinical or image interpretation does not parallel your findings or if I can be of any further assistance please contact me.

Laurent Locquet, DVM, MRCVS, GPCert, (VC) Diplomate, ECVIM-CA (Cardiology)

info@SonoPath.com