

PATIENT PRESENTING CLINICAL SIGNS

Neon Narr Hacking cough, wheezing, grade 3 heart murmur, rads show rounded heart/ slightly enlarged, shifting trachea

SPECIES Meds: Doxycycline 100 1/4 once a day, Temaril P 1/2 every other day

Canine

ULTRASONOGRAPHIC EXAMINATION OF THE HEART

BREED

Shih Tzu

SEX

Spayed Female

AGE

10 Years 3 Months

WEIGHT

7.8 lbs

INTERPRETED BY

Laurent Locquet, DVM,
MRCVS, GPCert, (VC)
Diplomate, ECVIM-CA
(Cardiology)

CANINE CARDIAC PARAMETERS	MR VMAX (m/s)	TR VMAX (m/s)	LA/AO (M-Mode)	LA/AO (Heart Base; Swe)	FS (%)	EF (%)	EPSS (cm)
NORMAL PARAMETER	4.5-5.5	<2.7	1.3	Up to 1.6	28-40	40-100	<0.6
PATIENT	5.18	--	1.15	1.3	41	73	0.19
CANINE CARDIAC PARAMETERS	HR (BPM)	AV VMAX (m/s)	PV MAX (m/s)	BODY WEIGHT (lbs)	LAD LA MAX 4 Chamber	LVIDd Avg; 2D and m-mode short axis (cm)	LVIDs Avg; 2D and m-mode short axis (cm)
NORMAL PARAMETER	50-100	0.7-1.7	0.7-1.6				
PATIENT	NM	1.12	0.61	7.8	2.46	2.2	1.3

Cardiac Presentation

The left atrium was normal in all 3 views. The mitral valve shows myxomatous changes compatible with myxomatous mitral valve disease and severe mitral valve regurgitation. The left ventricle was normal. The myocardium was normal. Contractility was normal. Left ventricular outflow tract was normal. The right atrium was normal. No evidence of masses. The tricuspid valve was normal. The right ventricle was normal. The pulmonic tract was normal. No visible pericardial effusion or pleural effusion. The cranial mediastinum and pericardial regions were free of masses in the visible windows.

ULTRASONOGRAPHIC FINDINGS

- ACVIM myxomatous mitral valve disease, stage B1.

INTERPRETATION OF THE FINDINGS & FURTHER RECOMMENDATIONS

The thoracic radiographs showed cardiomegaly, but based on this examination, the cardiac dimensions are within normal limits and further investigations might be considered. For example, CT scan or endoscopy of the airways to look for further causes of the coughing and wheezing. Annual recheck is recommended. No medications are necessary.

IMAGING PERFORMED BY

Rebecca Hamilton

HOSPITAL NAME

Farview Animal Clinic

REFERRING VET

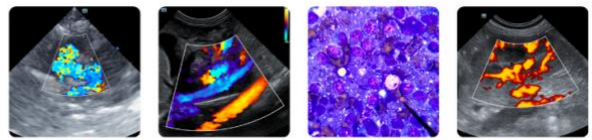
Dr. Mosaad

INVOICE

16413

DATE

05/21/26



PATIENT

Neon Narr

SPECIES

Canine

BREED

Shih Tzu

SEX

Spayed Female

AGE

10 Years 3 Months

WEIGHT

7.8 lbs

INTERPRETED BY

Laurent Locquet, DVM,
 MRCVS, GPCert, (VC)
 Diplomate, ECVIM-CA
 (Cardiology)

IMAGING PERFORMED BY

Rebecca Hamilton

HOSPITAL NAME

Farview Animal Clinic

REFERRING VET

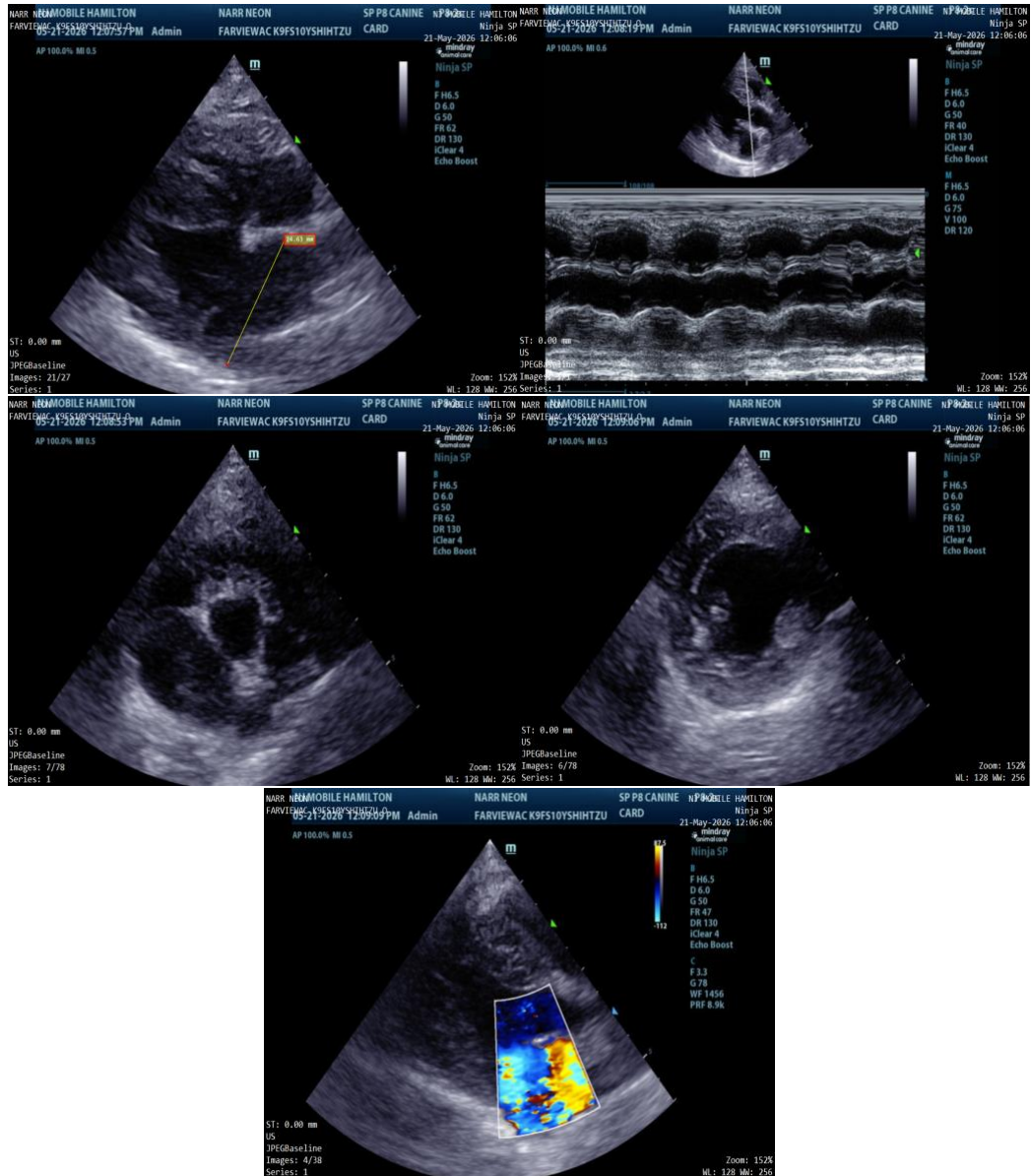
Dr. Mosaad

INVOICE

16413

DATE

05/21/26



The information and recommendations provided are based on the images presented by the referring veterinarian/sonographer. No evaluation can be communicated regarding pathology that was not visible in the image/video clips provided.

Thank you for this referral. If the clinical or image interpretation does not parallel your findings or if I can be of any further assistance please contact me.

Laurent Locquet, DVM, MRCVS, GPCert, (VC) Diplomate, ECVIM-CA (Cardiology)

info@SonoPath.com