



PATIENT

Jr Heard

SPECIES

Feline

BREED

DMH

SEX

Neutered Male

AGE

17 Years

WEIGHT

11.6 lbs

PRESENTING CLINICAL SIGNS

Soft heart murmur heard at last visit. Asymptomatic

Abnormal PE/Chem/CBC/UA Results: Euthyroid Blood pressure normal CKD IRIS stage 2/4

ULTRASONOGRAPHIC EXAMINATION OF THE HEART

FELINE CARDIAC PARAMETERS	BODY WEIGHT (lbs)	HR (BPM)	IVSd (cm)	LVIDd (cm)	LVWd (cm)	FS (%)	EF (%)
NORMAL PARAMETER	-----	150-240	0.3-0.6	1.0-2.1	0.25-0.6	35-67	80-100
PATIENT	11.6	NM	0.43	1.54	0.38	70	86
FELINE CARDIAC PARAMETERS	LA/AO (M-mode)	LA/AO HEART BASE (Sisson)	LAD LA MAX 4 Chamber		LVOT VEL. (m/s)	RVOT VEL. (m/s)	IVRT (m/)
NORMAL PARAMETER	<1.5	1.6	0.7-1.7		<1.6	<1.3	40-60
PATIENT	1.3	1.33	1.36		0.86	1.2	NM
Adapted from June Boon, Veterinary Echocardiography, 1998							
Sisson D et al. JVIM 1991; 5: 232, Jacobs et al. Am J Vet Res 1985; 46:1705							

INTERPRETED BY

Laurent Locquet, DVM, MRCVS, GPCert, (VC) Diplomate, ECVIM-CA (Cardiology)

IMAGING PERFORMED BY

Dr. Gudrun Gunther

HOSPITAL NAME

New Frontier Animal Medical Center

REFERRING VET

Dr. Gudrun Gunther

INVOICE

16408

DATE

05/21/26

Cardiac Presentation

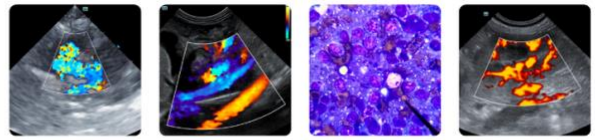
The left atrium was normal in all 3 views. The mitral valve was normal. The left ventricle was normal. The myocardium was normal. Contractility was normal. Left ventricular outflow tract was normal. The right atrium was normal. No evidence of masses. The tricuspid valve was normal. The right ventricle was normal. The pulmonic tract was normal. No visible pericardial effusion or pleural effusion. The cranial mediastinum and pericardial regions were free of masses in the visible windows.

ULTRASONOGRAPHIC FINDINGS

- Normal cardiac structure/function.

INTERPRETATION OF THE FINDINGS & FURTHER RECOMMENDATIONS

This is possibly an idiopathic flow murmur and does not appear hemodynamically significant.



PATIENT

Jr Heard

SPECIES

Feline

BREED

DMH

SEX

Neutered Male

AGE

17 Years

WEIGHT

11.6 lbs

INTERPRETED BY

Laurent Locquet, DVM,
MRCVS, GPCert, (VC)
Diplomate, ECVIM-CA
(Cardiology)

IMAGING PERFORMED BY

Dr. Gudrun Gunther

HOSPITAL NAME

New Frontier Animal
Medical Center

REFERRING VET

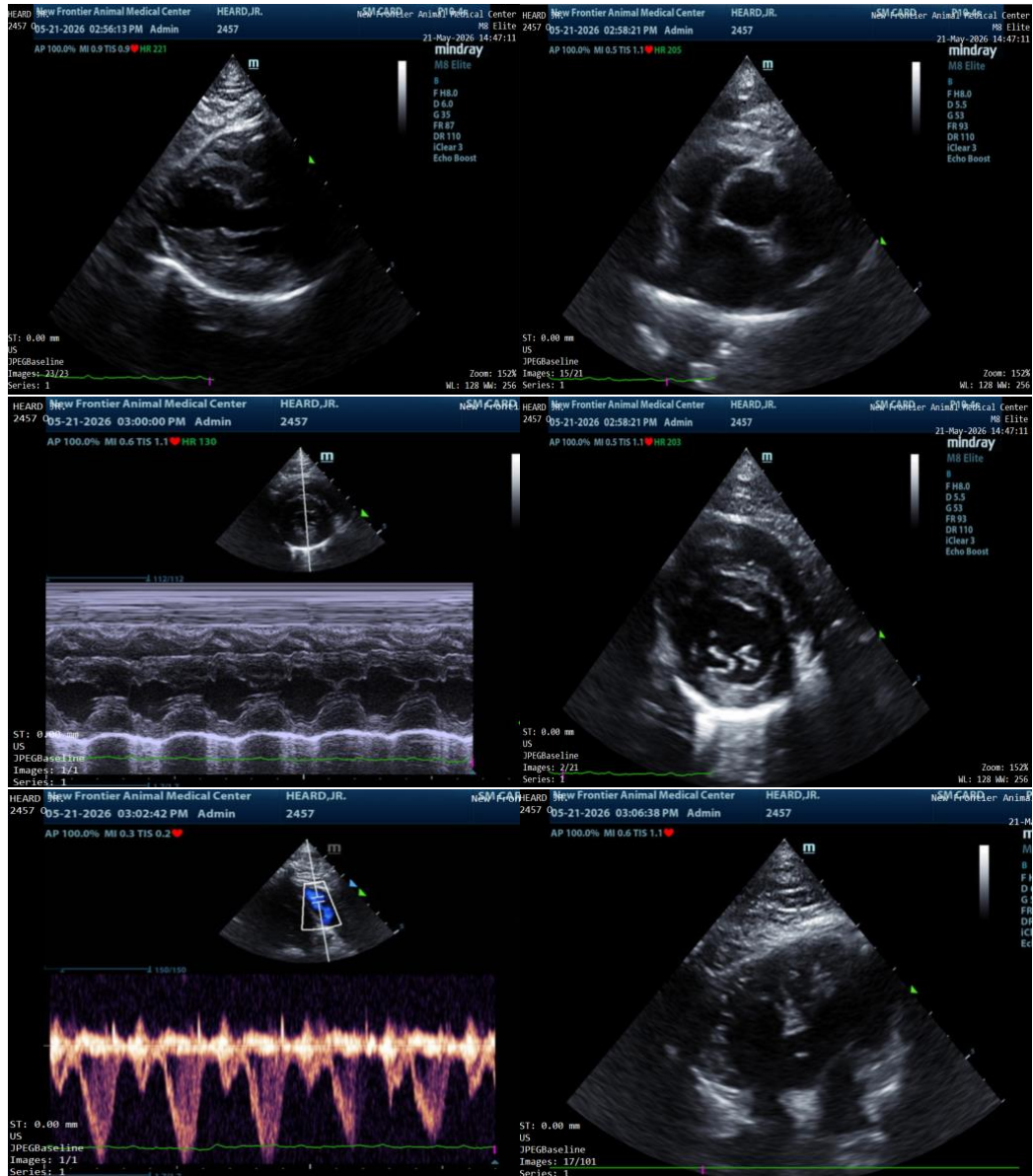
Dr. Gudrun Gunther

INVOICE

16408

DATE

05/21/26



The information and recommendations provided are based on the images presented by the referring veterinarian/sonographer. No evaluation can be communicated regarding pathology that was not visible in the image/video clips provided.

Thank you for this referral. If the clinical or image interpretation does not parallel your findings or if I can be of any further assistance please contact me.

Laurent Locquet, DVM, MRCVS, GPCert, (VC) Diplomate, ECVIM-CA (Cardiology)

info@SonoPath.com



PATIENT

Jr Heard

SPECIES

Feline

BREED

DMH

SEX

Neutered Male

AGE

17 Years

WEIGHT

11.6 lbs

INTERPRETED BY

Laurent Locquet, DVM,
MRCVS, GPCert, (VC)
Diplomate, ECVIM-CA
(Cardiology)

IMAGING PERFORMED BY

Dr. Gudrun Gunther

HOSPITAL NAME

New Frontier Animal
Medical Center

REFERRING VET

Dr. Gudrun Gunther

INVOICE

16408

DATE

05/21/26