

PATIENT

Mia Pennington

SPECIES

Canine

BREED

Labrador Retriever

SEX

Spayed Female

AGE

12 Years

WEIGHT

85 pounds

INTERPRETED BY

Laurent Locquet, DVM,
 MRCVS, GPCert, (VC)
 Diplomate, ECVIM-CA
 (Cardiology)

IMAGING PERFORMED BY

Meghan Morse LVT
 CVT

HOSPITAL NAME

Farview Animal Clinic

REFERRING VET

Dr. Mosaad

INVOICE

14926

DATE

04/07/26

PRESENTING CLINICAL SIGNS

Difficulty breathing, possible seizure. Muffled heart sounds, bilateral wheezes in lungs, labored abdominal breathing, rads- bronchial pattern w/ densities left lung lobe and cardiomegaly

Current meds: Gabapentin for US

Abnormal PE/Chem/CBC/UA Results: MCHC 30.9, Lym 0.98, ALP 287, BUN 29, glu 173

ULTRASONOGRAPHIC EXAMINATION OF THE HEART

CANINE CARDIAC PARAMETERS	MR VMAX (m/s)	TR VMAX (m/s)	LA/AO (M-Mode)	LA/AO (Heart Base; Swe)	FS (%)	EF (%)	EPSS (cm)
NORMAL PARAMETER	4.5-5.5	<2.7	1.3	Up to 1.6	28-40	40-100	<0.6
PATIENT	--	--	1.22	1.36	31	NM	NM
CANINE CARDIAC PARAMETERS	HR (BPM)	AV VMAX (m/s)	PV MAX (m/s)	BODY WEIGHT (lbs)	LAD LA MAX 4 Chamber	LVIDd Avg; 2D and m-mode short axis (cm)	LVIDs Avg; 2D and m-mode short axis (cm)
NORMAL PARAMETER	50-100	0.7-1.7	0.7-1.6				
PATIENT	NM	1.3	0.91	85.0	4.1	3.6	2.5

Cardiac Presentation

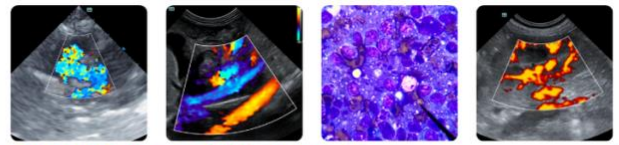
The left atrium was normal in all 3 views. The mitral valve was normal. The left ventricle was normal. The myocardium was normal. Contractility was normal. Left ventricular outflow tract was normal. The right atrium was normal. No evidence of masses. The tricuspid valve was normal. The right ventricle was normal. The pulmonic tract was normal. No visible pericardial effusion or pleural effusion. The cranial mediastinum and pericardial regions were free of masses in the visible windows.

ULTRASONOGRAPHIC FINDINGS

- Normal cardiac structure/function.

INTERPRETATION OF THE FINDINGS & FURTHER RECOMMENDATIONS

There are no structural nor functional abnormalities. Further investigations could include a CT scan or a bronchoalveolar lavage to further investigate the reported respiratory distress.



PATIENT

Mia Pennington

SPECIES

Canine

BREED

Labrador Retriever

SEX

Spayed Female

AGE

12 Years

WEIGHT

85 pounds

INTERPRETED BY

Laurent Locquet, DVM,
 MRCVS, GPCert, (VC)
 Diplomate, ECVIM-CA
 (Cardiology)

IMAGING PERFORMED BY

Meghan Morse LVT
 CVT

HOSPITAL NAME

Farview Animal Clinic

REFERRING VET

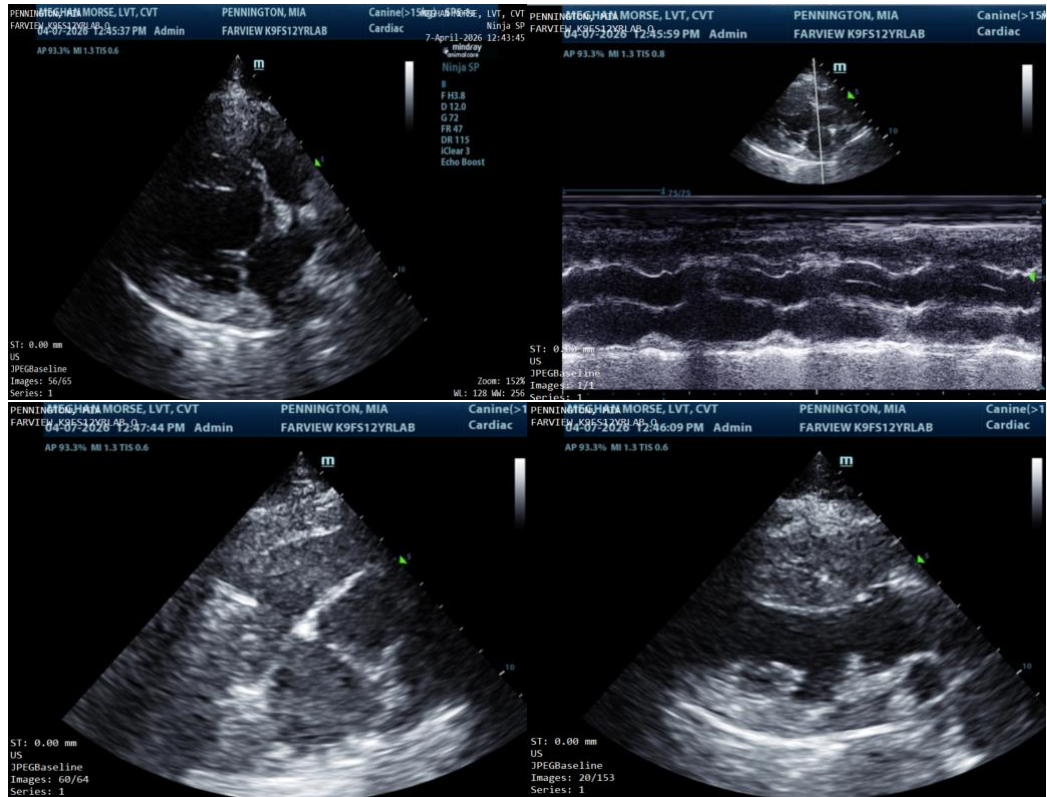
Dr. Mosaad

INVOICE

14926

DATE

04/07/26



The information and recommendations provided are based on the images presented by the referring veterinarian/sonographer. No evaluation can be communicated regarding pathology that was not visible in the image/video clips provided.

Thank you for this referral. If the clinical or image interpretation does not parallel your findings or if I can be of any further assistance please contact me.

Laurent Locquet, DVM, MRCVS, GPCert, (VC) Diplomate, ECVIM-CA (Cardiology)

info@SonoPath.com