



PATIENT

Midnite Nerone

SPECIES

Feline

BREED

DSH

SEX

Spayed Female

AGE

5 Years

WEIGHT

9.6 Pounds

INTERPRETED BY

Laurent Locquet, DVM,
MRCVS, GPCert, (VC)
Diplomate, ECVIM-CA

IMAGING PERFORMED BY

Meghan Morse, LVT,
CVT

HOSPITAL NAME

Anima General Hudson

REFERRING VET

Dr. DiGiuseppi

INVOICE

36844

DATE

4/27/26

PRESENTING CLINICAL SIGNS

History: Pre dental echo, severe dental dz, grade IV/VI sternal HM
Abnormal PE/Chem/CBC/UA Results: CBC/CHEM/T4 WNL

ULTRASONOGRAPHIC EXAMINATION OF THE HEART

FELINE CARDIAC PARAMETERS	BODY WEIGHT (lbs)	HR (BPM)	IVSd (cm)	LVIDd (cm)	LVWd (cm)	FS (%)	EF (%)
NORMAL PARAMETER	-----	150-240	0.3-0.6	1.0-2.1	0.25-0.6	35-67	80-100
PATIENT	9.6	NM	0.56	1.28	0.55	0.54	88
FELINE CARDIAC PARAMETERS	LA/AO (M-mode)	LA/AO HEART BASE (Sisson)	LAD LA MAX 4 Chamber		LVOT VEL (m/s)	RVOT VEL (m/s)	IVRT (m/)
NORMAL PARAMETER	<1.5	1.6	0.7-1.7		<1.6	<1.3	40-60
PATIENT	1.43	1.31	--		0.95	0.96	NM

Adapted from June Boon, Veterinary Echocardiography, 1998
Sisson D et al. JVIM 1991; 5: 232, Jacobs et al. Am J Vet Res 1985; 46:1705

Cardiac Presentation

The echocardiogram demonstrated normal left atrial size based on three separate measurements, including LAD (left atrial diameter), and LA/Ao using both the Swedish method and the method described by Boon. The cranial and caudal mitral valve leaflets appeared normal in 2D, and color Doppler revealed no mitral valve insufficiency. The left ventricle appeared normal, with normal thickness of both the left ventricular free wall and the interventricular septum. The myocardium presented as normal, without subjective evidence of significant fibrotic or ischemic disease. Contractility of the ventricular walls was adequate and within the normal range for this patient, evidenced by fractional shortening measurements and subjective evaluation of the myocardium from multiple regions and imaging angles. The LVOT demonstrated normal structural appearance in 2D, including a normal aortic valve. Color Doppler and spectral Doppler showed non-turbulent flow with normal velocities. The right atrium and auricle revealed no abnormalities. No evidence of masses was identified. The tricuspid valve appeared normal in 2D, and color Doppler showed no tricuspid insufficiency. The right ventricle was normal in size (approximately one third of the left ventricular diameter) with normal chordae structure, myocardial echogenicity, and wall thickness. The pulmonic tract assessment revealed no abnormalities. The pulmonic valve appeared subjectively normal in 2D; color Doppler identified no turbulent flow, and velocities were within reference ranges. No visible pericardial or pleural effusion was noted, and no extracardiac pathology was detected in the visible imaging planes. The cranial mediastinal and pericardial regions were free of visible masses.

ULTRASONOGRAPHIC FINDINGS



PATIENT

Midnite Nerone

SPECIES

Feline

BREED

DSH

SEX

Spayed Female

AGE

5 Years

WEIGHT

9.6 Pounds

INTERPRETED BY

Laurent Locquet, DVM,
 MRCVS, GPCert, (VC)
 Diplomate, ECVIM-CA

IMAGING PERFORMED BY

Meghan Morse, LVT,
 CVT

HOSPITAL NAME

Anima General Hudson

REFERRING VET

Dr. DiGiuseppi

INVOICE

36844

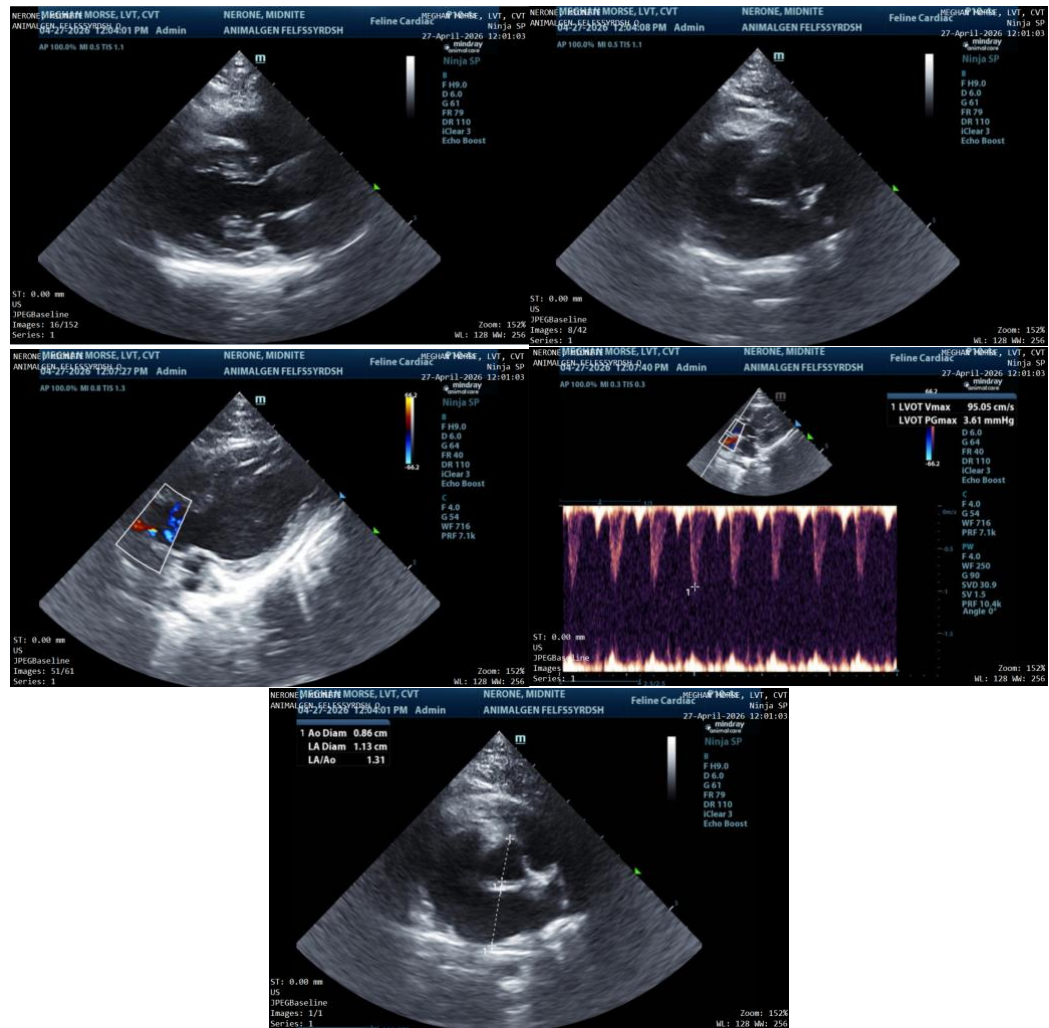
DATE

4/27/26

- This heart is functionally and structurally normal based on today's echocardiographic examination
- Possibly idiopathic flow murmur, not hemodynamically significant

INTERPRETATION OF THE FINDINGS & FURTHER RECOMMENDATIONS

Based on this echo, the anesthetic risk should not be significantly increased. Recheck is not necessary unless there are any concerns.



The information and recommendations provided are based on the images presented by the referring veterinarian/sonographer. No evaluation can be communicated regarding pathology that was not visible in the image/video clips provided.

Thank you for this referral. If the clinical or image interpretation does not parallel your findings or if I can be of any further assistance please contact me.



PATIENT

Laurent Locquet, DVM MRCVS GPCert (VC) Diplomate ECVIM-CA

Midnite Nerone

info@SonoPath.com

SPECIES

Feline

BREED

DSH

SEX

Spayed Female

AGE

5 Years

WEIGHT

9.6 Pounds

INTERPRETED BY

Laurent Locquet, DVM,
MRCVS, GPCert, (VC)
Diplomate, ECVIM-CA

**IMAGING
PERFORMED BY**

Meghan Morse, LVT,
CVT

HOSPITAL NAME

Anima General Hudson

REFERRING VET

Dr. DiGiuseppi

INVOICE

36844

DATE

4/27/26