

PATIENT

Sadie Pavese

SPECIES

Canine

BREED

Mini Schnauzer

SEX

Spayed Female

AGE

9 Years 7 Months

WEIGHT

14.8 pounds

INTERPRETED BY

Laurent Locquet, DVM,
MRCVS, GPCert, (VC)
Diplomate, ECVIM-CA
(Cardiology)

IMAGING PERFORMED BY

Kerri Becker

HOSPITAL NAME

Park Ridge Animal
Hospital

REFERRING VET

Dr. Doyle

INVOICE

15100

DATE

04/14/26

PRESENTING CLINICAL SIGNS

Cardiomegaly on pre op rads, dermal cyst bothering pet. VHS-11.7 with flattening of caudal waist. No murmur/arrhythmia ausculted.

ULTRASONOGRAPHIC EXAMINATION OF THE HEART

CANINE CARDIAC PARAMETERS	MR VMAX (m/s)	TR VMAX (m/s)	LA/AO (M-Mode)	LA/AO (Heart Base; Swe)	FS (%)	EF (%)	EPSS (cm)
NORMAL PARAMETER	4.5-5.5	<2.7	1.3	Up to 1.6	28-40	40-100	<0.6
PATIENT	--	--	NM	1.39	41	75	0.11
CANINE CARDIAC PARAMETERS	HR (BPM)	AV VMAX (m/s)	PV MAX (m/s)	BODY WEIGHT (lbs)	LAD LA MAX 4 Chamber	LVIDd Avg; 2D and m-mode short axis (cm)	LVIDs Avg; 2D and m-mode short axis (cm)
NORMAL PARAMETER	50-100	0.7-1.7	0.7-1.6				
PATIENT	NM	1.48	1.2	14.8	2.3	2.38	1.39

Cardiac Presentation

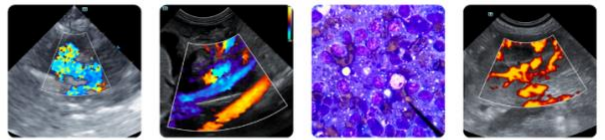
The left atrium was normal in all 3 views. The mitral valve was normal. The left ventricle was normal. The myocardium was normal. Contractility was normal. Left ventricular outflow tract was normal. The right atrium was normal. No evidence of masses. The tricuspid valve was normal. The right ventricle was normal. The pulmonic tract was normal. No visible pericardial effusion or pleural effusion. The cranial mediastinum and pericardial regions were free of masses in the visible windows.

ULTRASONOGRAPHIC FINDINGS

- Structurally normal heart.

INTERPRETATION OF THE FINDINGS & FURTHER RECOMMENDATIONS

No rechecks are necessary unless there are any concerns.



PATIENT

Sadie Pavese

SPECIES

Canine

BREED

Mini Schnauzer

SEX

Spayed Female

AGE

9 Years 7 Months

WEIGHT

14.8 pounds

INTERPRETED BY

Laurent Locquet, DVM,
 MRCVS, GPCert, (VC)
 Diplomate, ECVIM-CA
 (Cardiology)

IMAGING PERFORMED BY

Kerri Becker

HOSPITAL NAME

Park Ridge Animal
 Hospital

REFERRING VET

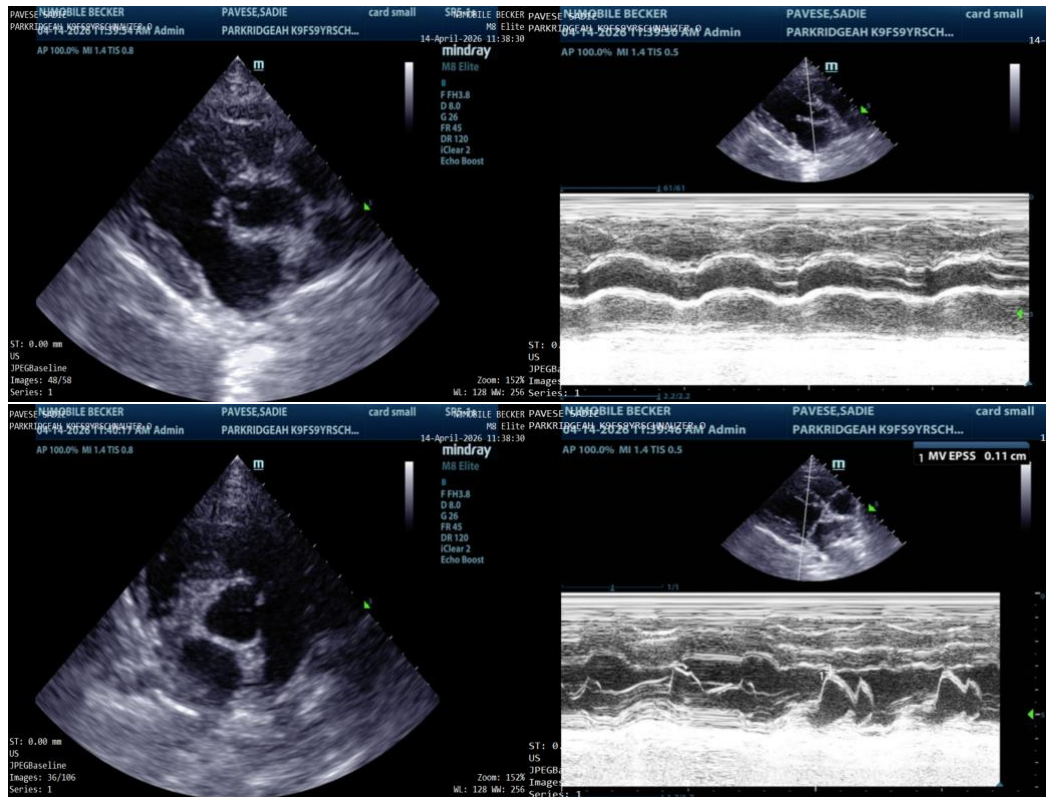
Dr. Doyle

INVOICE

15100

DATE

04/14/26



The information and recommendations provided are based on the images presented by the referring veterinarian/sonographer. No evaluation can be communicated regarding pathology that was not visible in the image/video clips provided.

Thank you for this referral. If the clinical or image interpretation does not parallel your findings or if I can be of any further assistance please contact me.

Laurent Locquet, DVM, MRCVS, GPCert, (VC) Diplomate, ECVIM-CA (Cardiology)

info@SonoPath.com