

PATIENT

Vader Stroble

SPECIES

Canine

BREED

Chihuahua

SEX

Neutered Male

AGE

10 Years

WEIGHT

10 pounds

INTERPRETED BY

Laurent Locquet, DVM,
 MRCVS, GPCert, (VC)
 Diplomate, ECVIM-CA
 (Cardiology)

IMAGING PERFORMED BY

Meghan Morse LVT,
 CVT

HOSPITAL NAME

Kingston Animal
 Hospital

REFERRING VET

Dr. Alden

INVOICE

14774

DATE

04/01/26

PRESENTING CLINICAL SIGNS

Coughing at night, murmur now 5/6 was 3/6

Abnormal PE/Chem/CBC/UA Results: Anaplasma +

ULTRASONOGRAPHIC EXAMINATION OF THE HEART

CANINE CARDIAC PARAMETERS	MR VMAX (m/s)	TR VMAX (m/s)	LA/AO (M-Mode)	LA/AO (Heart Base; Swe)	FS (%)	EF (%)	EPSS (cm)
NORMAL PARAMETER	4.5-5.5	<2.7	1.3	Up to 1.6	28-40	40-100	<0.6
PATIENT	4.8	NM	1.32	1.41	50.50	83	NM
CANINE CARDIAC PARAMETERS	HR (BPM)	AV VMAX (m/s)	PV MAX (m/s)	BODY WEIGHT (lbs)	LAD LA MAX 4 Chamber	LVIDd Avg; 2D and m-mode short axis (cm)	LVIDs Avg; 2D and m-mode short axis (cm)
NORMAL PARAMETER	50-100	0.7-1.7	0.7-1.6				
PATIENT	NM	1.19	0.87	10.0	22 mm	2.74	1.38

Cardiac Presentation

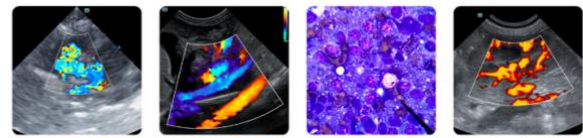
The left atrium was normal in all 3 views. The mitral valve shows myxomatous changes compatible with myxomatous mitral valve disease and moderate mitral valve regurgitation. The left ventricle was normal. The myocardium was normal. Contractility was normal. Left ventricular outflow tract was normal. The right atrium was normal. No evidence of masses. The tricuspid valve was normal. The right ventricle was normal. The pulmonic tract was normal. No visible pericardial effusion or pleural effusion. The cranial mediastinum and pericardial regions were free of masses in the visible windows.

ULTRASONOGRAPHIC FINDINGS

- Myxomatous mitral valve disease stage B1.

INTERPRETATION OF THE FINDINGS & FURTHER RECOMMENDATIONS

Recheck in one year. No medications unless there are any concerns prior.



PATIENT

Vader Stroble

SPECIES

Canine

BREED

Chihuahua

SEX

Neutered Male

AGE

10 Years

WEIGHT

10 pounds

INTERPRETED BY

Laurent Locquet, DVM,
 MRCVS, GPCert, (VC)
 Diplomate, ECVIM-CA
 (Cardiology)

IMAGING PERFORMED BY

Meghan Morse LVT,
 CVT

HOSPITAL NAME

Kingston Animal
 Hospital

REFERRING VET

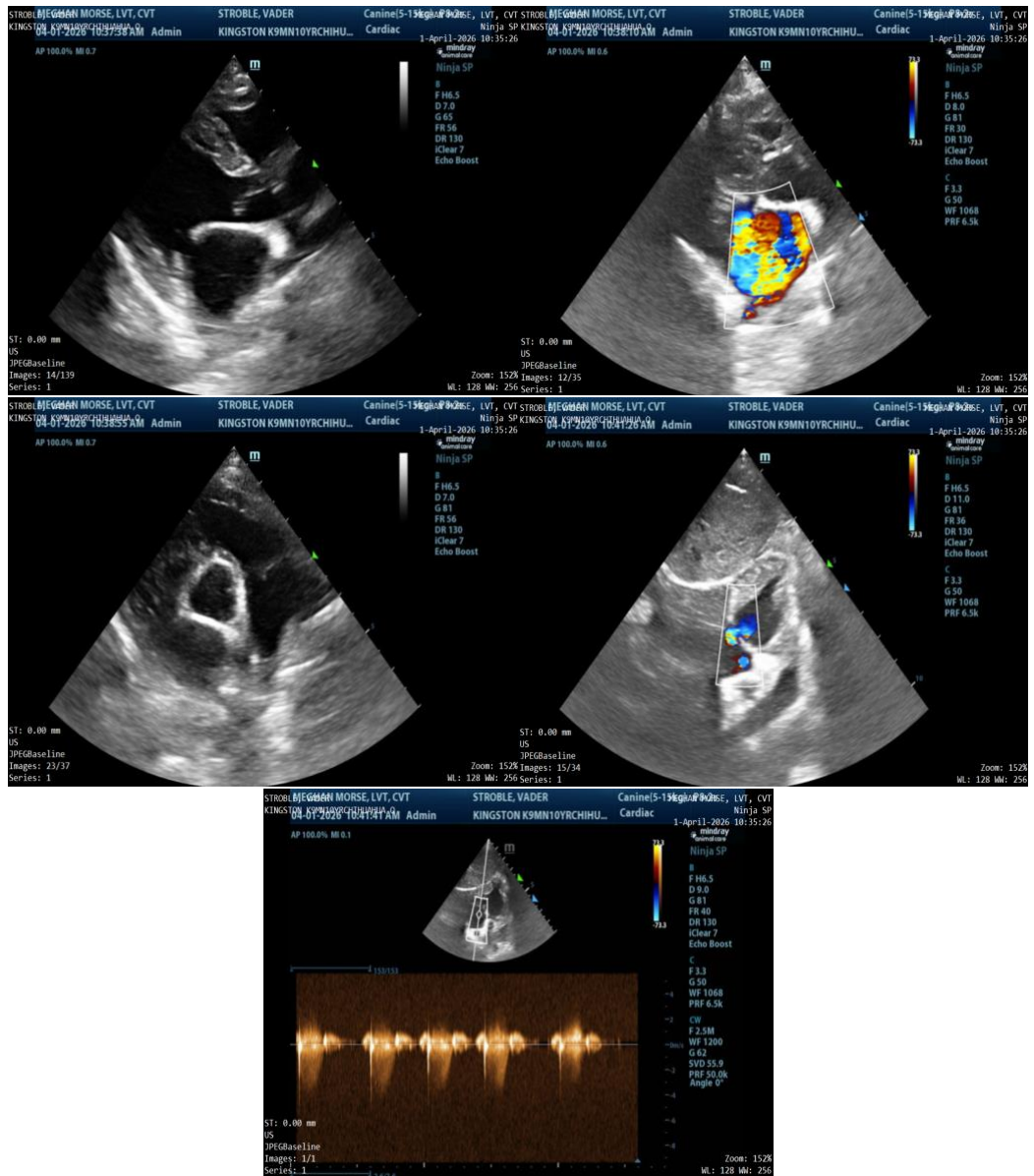
Dr. Alden

INVOICE

14774

DATE

04/01/26



The information and recommendations provided are based on the images presented by the referring veterinarian/sonographer. No evaluation can be communicated regarding pathology that was not visible in the image/video clips provided.

Thank you for this referral. If the clinical or image interpretation does not parallel your findings or if I can be of any further assistance please contact me.

Laurent Locquet, DVM, MRCVS, GPCert, (VC) Diplomate, ECVIM-CA (Cardiology)

info@SonoPath.com