

**PATIENT**

Bailey Cornell

**SPECIES**

Canine

**BREED**

Portugese Water Dog

**SEX**

Neutered Male

**AGE**

7 Years

**WEIGHT**

50.5 pounds

**INTERPRETED BY**

Laurent Locquet, DVM,  
 MRCVS, GPCert, (VC)  
 Diplomate, ECVIM-CA  
 (Cardiology)

**IMAGING PERFORMED BY**

Meghan Morse LVT,  
 CVT

**HOSPITAL NAME**

Kingston Animal  
 Hospital

**REFERRING VET**

Dr. Alden

**INVOICE**

14775

**DATE**

04/01/26

**PRESENTING CLINICAL SIGNS**

Monitor Heart Murmur, O requested abdominal ultrasound

**ULTRASONOGRAPHIC EXAMINATION OF THE HEART**

CANINE CARDIAC PARAMETERS	MR VMAX (m/s)	TR VMAX (m/s)	LA/AO (M-Mode)	LA/AO (Heart Base; Swe)	FS (%)	EF (%)	EPSS (cm)
NORMAL PARAMETER	4.5-5.5	<2.7	1.3	Up to 1.6	28-40	40-100	<0.6
PATIENT	--	--	1.48	1.59	26	--	NM
CANINE CARDIAC PARAMETERS	HR (BPM)	AV VMAX (m/s)	PV MAX (m/s)	BODY WEIGHT (lbs)	LAD LA MAX 4 Chamber	LVIDd Avg; 2D and m-mode short axis (cm)	LVIDs Avg; 2D and m-mode short axis (cm)
NORMAL PARAMETER	50-100	0.7-1.7	0.7-1.6				
PATIENT	NM	2.31	1.31	50.5	--	3.5	2.6

**Cardiac Presentation**

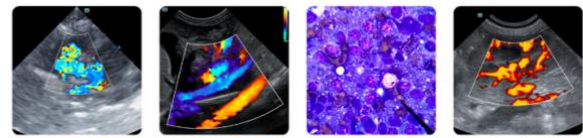
The left atrium was normal in all 3 views. The mitral valve shows myxomatous changes compatible with myxomatous mitral valve disease and moderate mitral valve regurgitation. The left ventricle was normal. The myocardium was normal. Contractility was normal. Left ventricular outflow tract was normal. The right atrium was normal. No evidence of masses. Concurrent very mild tricuspid disease was evident. The right ventricle was normal. The pulmonic tract was normal. No visible pericardial effusion or pleural effusion. The cranial mediastinum and pericardial regions were free of masses in the visible windows.

**ULTRASONOGRAPHIC FINDINGS**

- Myxomatous mitral valve disease stage B1 with concurrent mild tricuspid disease.

**INTERPRETATION OF THE FINDINGS & FURTHER RECOMMENDATIONS**

Annual recheck is recommended unless there are any concerns prior. No medications are necessary.



**PATIENT**

Bailey Cornell

**SPECIES**

Canine

**BREED**

Portugese Water Dog

**SEX**

Neutered Male

**AGE**

7 Years

**WEIGHT**

50.5 pounds

**INTERPRETED BY**

Laurent Locquet, DVM,  
 MRCVS, GPCert, (VC)  
 Diplomate, ECVIM-CA  
 (Cardiology)

**IMAGING PERFORMED BY**

Meghan Morse LVT,  
 CVT

**HOSPITAL NAME**

Kingston Animal  
 Hospital

**REFERRING VET**

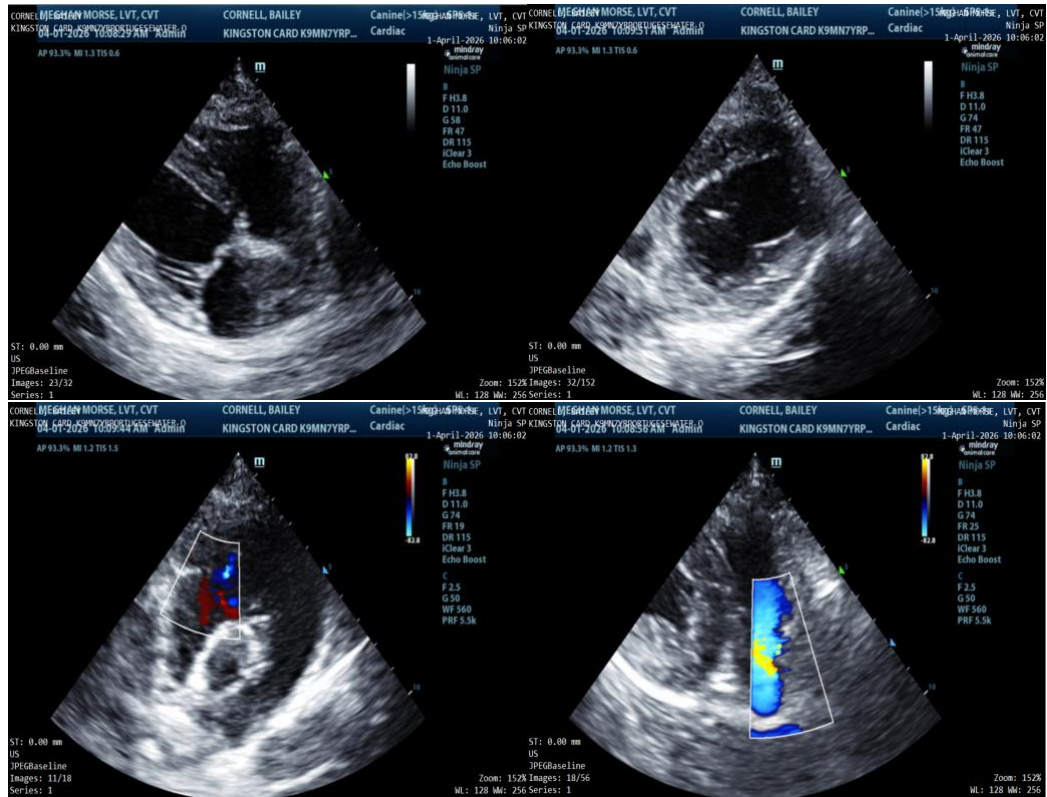
Dr. Alden

**INVOICE**

14775

**DATE**

04/01/26



The information and recommendations provided are based on the images presented by the referring veterinarian/sonographer. No evaluation can be communicated regarding pathology that was not visible in the image/video clips provided.

Thank you for this referral. If the clinical or image interpretation does not parallel your findings or if I can be of any further assistance please contact me.

Laurent Locquet, DVM, MRCVS, GPCert, (VC) Diplomate, ECVIM-CA (Cardiology)

[info@SonoPath.com](mailto:info@SonoPath.com)