



PATIENT

Charlie Diamond

SPECIES

Canine

BREED

Mini Golden Poodle
Mix

SEX

Spayed Female

AGE

10 Years

WEIGHT

9 Pounds

INTERPRETED BY

Laurent Locquet, DVM,
MRCVS, GPCert, (VC)
Diplomate, ECVIM-CA
(Cardiology)

IMAGING PERFORMED BY

Meghan Morse, LVT,
CVT

HOSPITAL NAME

Park Ridge AH

REFERRING VET

Dr. Rosenblum

INVOICE

36110

DATE

3/5/26

PRESENTING CLINICAL SIGNS

- New HM grade III-IV/VI
- No cough, normal activity
- Current meds: Simp Trio

ULTRASONOGRAPHIC EXAMINATION OF THE HEART

CANINE CARDIAC PARAMETERS	MR VMAX (m/s)	TR VMAX (m/s)	LA/AO (M-Mode)	LA/AO (Heart Base; Swe)	FS (%)	EF (%)	EPSS (cm)
NORMAL PARAMETER	4.5-5.5	<2.7	1.3	Up to 1.6	28-40	40-100	<0.6
PATIENT	5.1	--	NM	1.37	55	88	NM
CANINE CARDIAC PARAMETERS	HR (BPM)	AV VMAX (m/s)	PV MAX (m/s)	BODY WEIGHT (lbs)	LAD LA MAX 4 Chamber	LVIDd Avg; 2D and m-mode short axis (cm)	LVIDs Avg; 2D and m-mode short axis (cm)
NORMAL PARAMETER	50-100	0.7-1.7	0.7-1.6				
PATIENT	--	1.57	0.89	9 lbs	28.13 mm	2.32	1.04

Cardiac Presentation

The mitral valve leaflets are mildly thickened with moderate mitral regurgitation posteriorly directed. There is no prolapse of the mitral valve leaflets. The left atrial size is normal. Left ventricular internal dimensions during diastole are within normal limits and systolic function is preserved in the face of mitral regurgitation. There is normal right atrial size without tricuspid regurgitation. There is no prolapse of the tricuspid valve leaflets and no evidence of pulmonary hypertension based upon tricuspid regurgitant velocities. The right ventricle subjectively appears normal in structure and function. The aortic and pulmonic valves have normal morphology and the corresponding outflow velocities are within normal limits. There is no evidence of pulmonic insufficiency. There is moderate aortic insufficiency. The aorta appears normal. The pulmonary artery and associated branches appear normal. There is no evidence of pleural effusion, pericardial effusion, or intracardiac masses.

ULTRASONOGRAPHIC FINDINGS

- Myxomatous mitral valve disease, ACVIM stage B-1
- Moderate mitral valve regurgitation
- Moderate aortic insufficiency

INTERPRETATION OF THE FINDINGS & FURTHER RECOMMENDATIONS



PATIENT

Charlie Diamond

SPECIES

Canine

BREED

Mini Golden Poodle Mix

SEX

Spayed Female

AGE

10 Years

WEIGHT

9 Pounds

INTERPRETED BY

Laurent Locquet, DVM,
 MRCVS, GPCert, (VC)
 Diplomate, ECVIM-CA
 (Cardiology)

IMAGING PERFORMED BY

Meghan Morse, LVT,
 CVT

HOSPITAL NAME

Park Ridge AH

REFERRING VET

Dr. Rosenblum

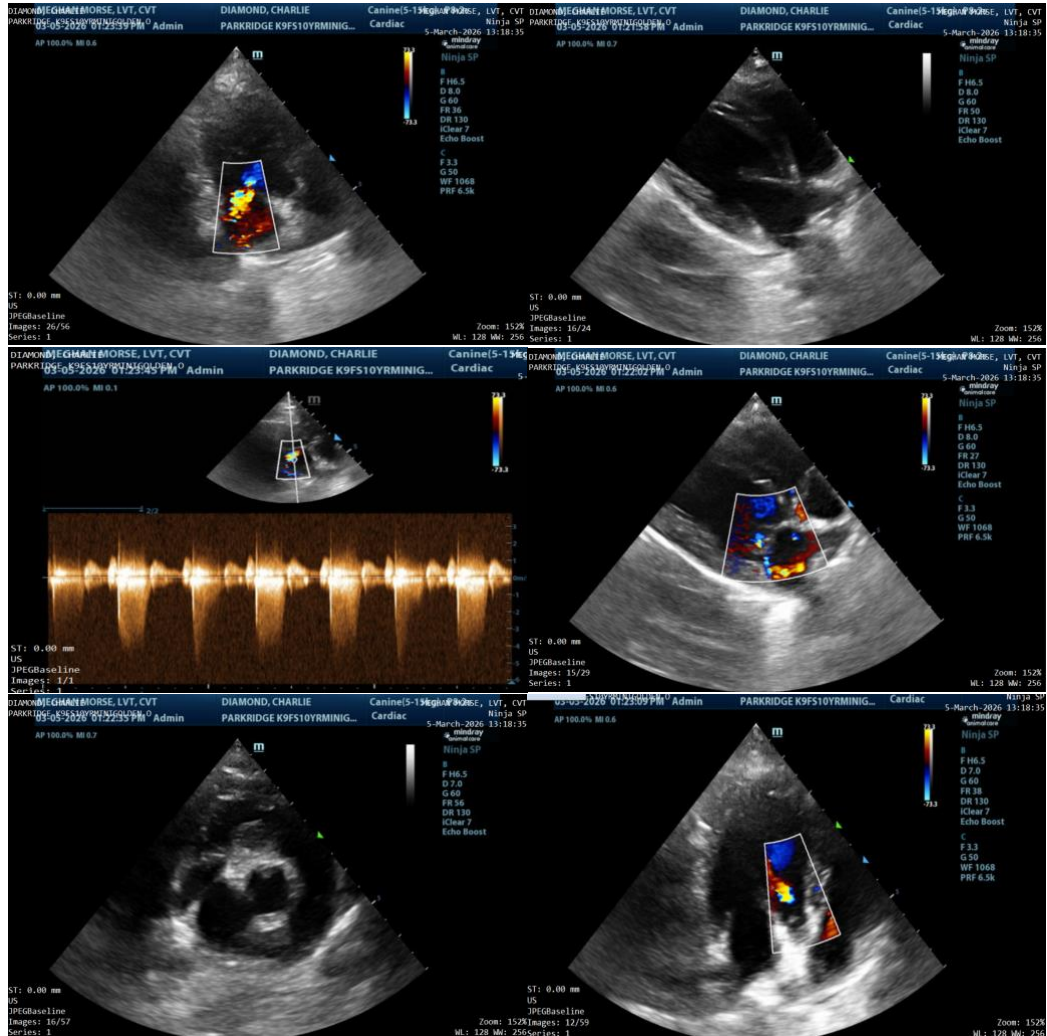
INVOICE

36110

DATE

3/5/26

No medications are necessary. Recheck is recommended in one year, unless there are any concerns prior.



The information and recommendations provided are based on the images presented by the referring veterinarian/sonographer. No evaluation can be communicated regarding pathology that was not visible in the image/video clips provided.

Thank you for this referral. If the clinical or image interpretation does not parallel your findings or if I can be of any further assistance please contact me.

Laurent Locquet, DVM MRCVS GPCert (VC) Diplomate ECVIM-CA

info@SonoPath.com