

PATIENT PRESENTING CLINICAL SIGNS

Sadie Grigg

- recent h/o heart murmur

SPECIES

Canine

Abnormal PE/Chem/CBC/UA Results: BCS 5/9, mm pink cat < 2 sec, Grade 3-4/6 L basilar diastolic murmur and L 4-5/6 apical systolic murmur, no pulse deficits

BREED

Chihuahua

ULTRASONOGRAPHIC EXAMINATION OF THE HEART

SEX

Spayed Female

AGE

5.9

WEIGHT

7.2 pounds

CANINE CARDIAC PARAMETERS	MR VMAX (m/s)	TR VMAX (m/s)	LA/AO (M-Mode)	LA/AO (Heart Base; Swe)	FS (%)	EF (%)	EPSS (cm)
NORMAL PARAMETER	4.5-5.5	<2.7	1.3	Up to 1.6	28-40	40-100	<0.6
PATIENT	5.02	--	1.27	1.2	32	NM	0.15
CANINE CARDIAC PARAMETERS	HR (BPM)	AV VMAX (m/s)	PV MAX (m/s)	BODY WEIGHT (lbs)	LAD LA MAX 4 Chamber	LVIDd Avg; 2D and m-mode short axis (cm)	LVIDs Avg; 2D and m-mode short axis (cm)
NORMAL PARAMETER	50-100	0.7-1.7	0.7-1.6				
PATIENT	NM	2.09	0.9	7.2	2.0	2.0	1.35

INTERPRETED BY

Laurent Locquet, DVM, MRCVS, GPCert, (VC)
 Diplomate, ECVIM-CA (Cardiology)

IMAGING PERFORMED BY

Ginny Dodd, DVM, D, ABVP-CFP

HOSPITAL NAME

Ironton Animal Hospital

REFERRING VET

Dr. Tony Levine

INVOICE

14626

DATE

03/26/26

Cardiac Presentation

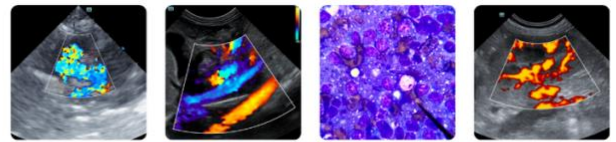
The left atrium was normal in all 3 views. The mitral valve shows myxomatous changes compatible with myxomatous mitral valve disease and moderate to severe mitral valve regurgitation. The left ventricle was normal. The myocardium was normal. Contractility was normal. Severe aortic insufficiency was noted. The right atrium was normal. No evidence of masses. The tricuspid valve was normal. The right ventricle was normal. The pulmonic tract was normal. No visible pericardial effusion or pleural effusion. The cranial mediastinum and pericardial regions were free of masses in the visible windows.

ULTRASONOGRAPHIC FINDINGS

- Myxomatous mitral valve disease stage B1 with moderate to severe MR and severe aortic insufficiency.

INTERPRETATION OF THE FINDINGS & FURTHER RECOMMENDATIONS

Annual recheck is recommended. No medications are necessary.



PATIENT

Sadie Grigg

SPECIES

Canine

BREED

Chihuahua

SEX

Spayed Female

AGE

5.9

WEIGHT

7.2 pounds

INTERPRETED BY

Laurent Locquet, DVM,
 MRCVS, GPCert, (VC)
 Diplomate, ECVIM-CA
 (Cardiology)

IMAGING PERFORMED BY

Ginny Dodd, DVM, D,
 ABVP-CFP

HOSPITAL NAME

Ironton Animal
 Hospital

REFERRING VET

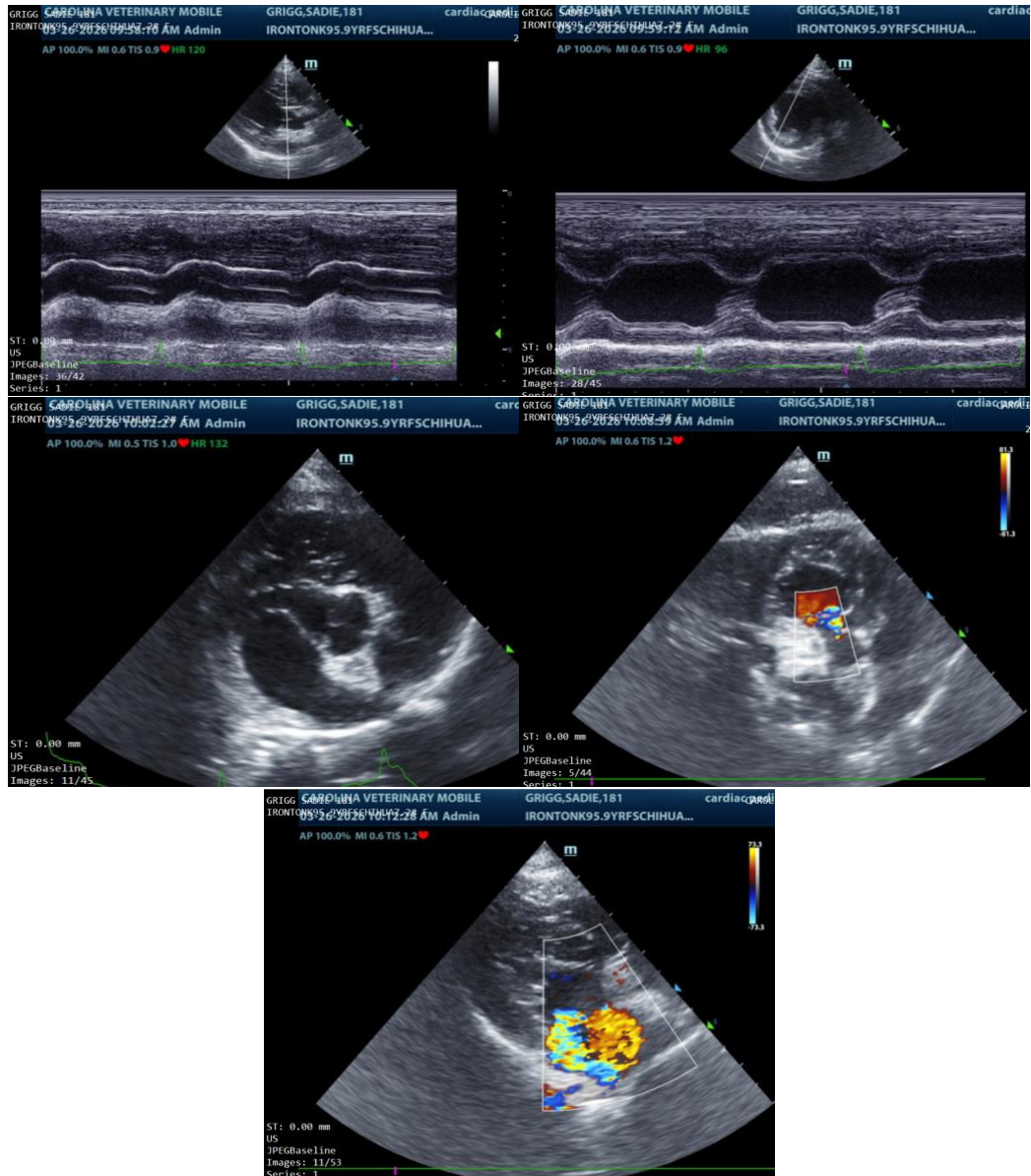
Dr. Tony Levine

INVOICE

14626

DATE

03/26/26

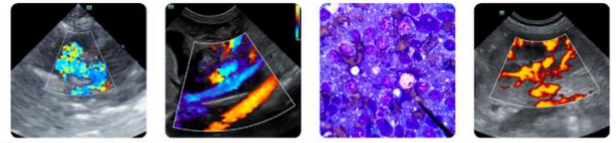


The information and recommendations provided are based on the images presented by the referring veterinarian/sonographer. No evaluation can be communicated regarding pathology that was not visible in the image/video clips provided.

Thank you for this referral. If the clinical or image interpretation does not parallel your findings or if I can be of any further assistance please contact me.

Laurent Locquet, DVM, MRCVS, GPCert, (VC) Diplomate, ECVIM-CA (Cardiology)

info@SonoPath.com



PATIENT

Sadie Grigg

SPECIES

Canine

BREED

Chihuahua

SEX

Spayed Female

AGE

5.9

WEIGHT

7.2 pounds

INTERPRETED BY

Laurent Locquet, DVM,
MRCVS, GPCert, (VC)
Diplomate, ECVIM-CA
(Cardiology)

**IMAGING
PERFORMED BY**

Ginny Dodd, DVM, D,
ABVP-CFP

HOSPITAL NAME

Ironton Animal
Hospital

REFERRING VET

Dr. Tony Levine

INVOICE

14626

DATE

03/26/26