

PATIENT

Betsy Mertz

SPECIES

Canine

BREED

Chihuahua

SEX

Spayed Female

AGE

14 Years 1 Months

WEIGHT

5.3 kg

INTERPRETED BY

Laurent Locquet, DVM,
 MRCVS, GPCert, (VC)
 Diplomate, ECVIM-CA
 (Cardiology)

IMAGING PERFORMED BY

Shari Reffi CVT

HOSPITAL NAME

Abby Road Veterinary
 Hospital

REFERRING VET

Dr. Gerenser

INVOICE

14577

DATE

03/24/26

PRESENTING CLINICAL SIGNS

- BCS 5/9
- Recently worsening heart murmur. Grade III murmur x 3years.
- Avg. systolic BP of 165
- Current Meds: Gabapentin pre-procedure

Abnormal PE/Chem/CBC/UA Results: WNL. USG: 1.029 (not 1st AM)

ULTRASONOGRAPHIC EXAMINATION OF THE HEART

CANINE CARDIAC PARAMETERS	MR VMAX (m/s)	TR VMAX (m/s)	LA/AO (M-Mode)	LA/AO (Heart Base; Swe)	FS (%)	EF (%)	EPSS (cm)
NORMAL PARAMETER	4.5-5.5	<2.7	1.3	Up to 1.6	28-40	40-100	<0.6
PATIENT	5.85	2.36	NM	1.48	40	72	0.31
CANINE CARDIAC PARAMETERS	HR (BPM)	AV VMAX (m/s)	PV MAX (m/s)	BODY WEIGHT (kg)	LAD LA MAX 4 Chamber	LVIDd Avg; 2D and m-mode short axis (cm)	LVIDs Avg; 2D and m-mode short axis (cm)
NORMAL PARAMETER	50-100	0.7-1.7	0.7-1.6				
PATIENT	NM	1.21	0.64	5.3	2.47	3.19	1.9

Cardiac Presentation

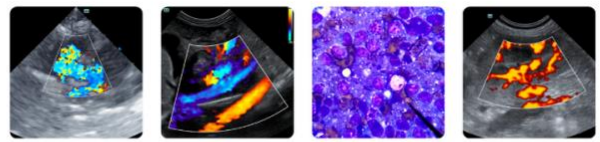
The left atrium was normal in all 3 views. The mitral valve shows myxomatous changes compatible with myxomatous mitral valve disease and moderate mitral valve regurgitation. The left ventricle was normal. The myocardium was normal. Contractility was normal. Left ventricular outflow tract was normal. The right atrium was normal. No evidence of masses. The tricuspid valve revealed mild tricuspid regurgitation. The right ventricle was normal. The pulmonic tract was normal. No visible pericardial effusion or pleural effusion. The cranial mediastinum and pericardial regions were free of masses in the visible windows.

ULTRASONOGRAPHIC FINDINGS

- Myxomatous mitral valve disease with moderate MR and mild TR.

INTERPRETATION OF THE FINDINGS & FURTHER RECOMMENDATIONS

No medication necessary. Recheck echo in one year unless there are any concerns prior.



PATIENT

Betsy Mertz

SPECIES

Canine

BREED

Chihuahua

SEX

Spayed Female

AGE

14 Years 1 Months

WEIGHT

5.3 kg

INTERPRETED BY

Laurent Locquet, DVM,
 MRCVS, GPCert, (VC)
 Diplomate, ECVIM-CA
 (Cardiology)

IMAGING PERFORMED BY

Shari Reffi CVT

HOSPITAL NAME

Abby Road Veterinary
 Hospital

REFERRING VET

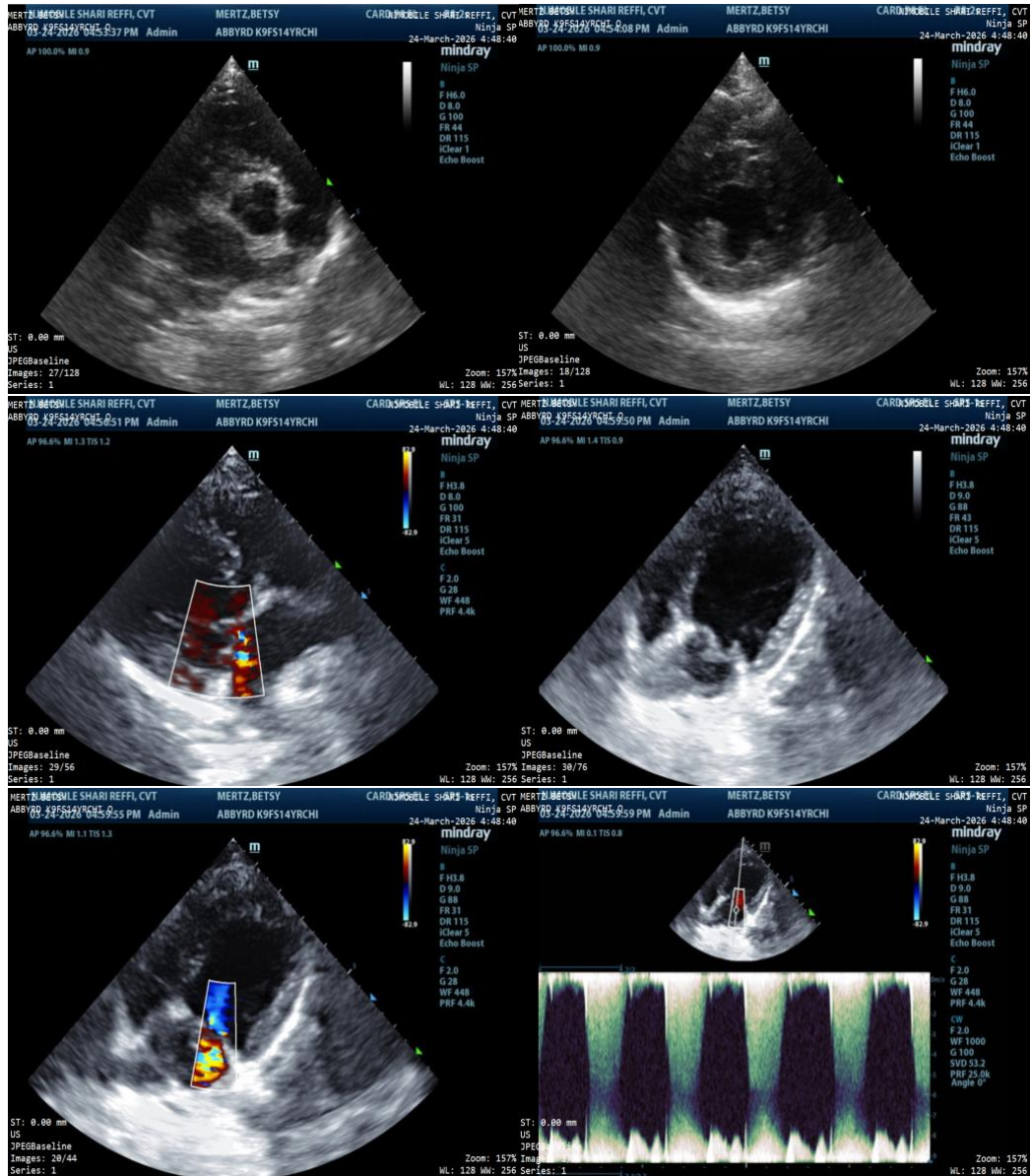
Dr. Gerenser

INVOICE

14577

DATE

03/24/26



The information and recommendations provided are based on the images presented by the referring veterinarian/sonographer. No evaluation can be communicated regarding pathology that was not visible in the image/video clips provided.

Thank you for this referral. If the clinical or image interpretation does not parallel your findings or if I can be of any further assistance please contact me.

Laurent Locquet, DVM, MRCVS, GPCert, (VC) Diplomate, ECVIM-CA (Cardiology)

info@SonoPath.com