



PATIENT

Chewie Erlichman

SPECIES

Canine

BREED

Shih Tzu Mix

SEX

Neutered Male

AGE

9 Years

WEIGHT

18.6 Pounds

INTERPRETED BY

Laurent Locquet, DVM,
 MRCVS, GPCert, (VC)
 Diplomate, ECVIM-CA
 (Cardiology)

IMAGING PERFORMED BY

Rebecca Hamilton

HOSPITAL NAME

Animal General
 Hudson

REFERRING VET

Dr. DiGiuseppi

INVOICE

36064

DATE

3/2/26

PRESENTING CLINICAL SIGNS

- New Asymptomatic HM
- pre echo for dental anesthesia
- Dermatitis, cystic growths,
- grade 2/6 L sided murmur

ULTRASONOGRAPHIC EXAMINATION OF THE HEART

CANINE CARDIAC PARAMETERS	MR VMAX (m/s)	TR VMAX (m/s)	LA/AO (M-Mode)	LA/AO (Heart Base; Swe)	FS (%)	EF (%)	EPSS (cm)
NORMAL PARAMETER	4.5-5.5	<2.7	1.3	Up to 1.6	28-40	40-100	<0.6
PATIENT	6.46	2.10	1.29	1.56	38	70	0.55
CANINE CARDIAC PARAMETERS	HR (BPM)	AV VMAX (m/s)	PV MAX (m/s)	BODY WEIGHT (lbs)	LAD LA MAX 4 Chamber	LVIDd Avg; 2D and m-mode short axis (cm)	LVIDs Avg; 2D and m-mode short axis (cm)
NORMAL PARAMETER	50-100	0.7-1.7	0.7-1.6				
PATIENT	--	1.23	0.98	18.6 lbs	2.51	3.04	1.87

Cardiac Presentation

The mitral valve leaflets are mildly thickened with moderate mitral regurgitation posteriorly directed. There is no prolapse of the mitral valve leaflet. The left atrial size is normal. Left ventricular internal dimensions during diastole are within normal limits and systolic function is preserved in the face of mitral regurgitation. There is normal right atrial size with mild tricuspid regurgitation. There is no prolapse of the tricuspid valve leaflets and no evidence of pulmonary hypertension based upon tricuspid regurgitant velocities. The right ventricle subjectively appears normal in structure and function. The aortic and pulmonic valves have normal morphology and the corresponding outflow velocities are within normal limits. There is no evidence of pulmonic or aortic insufficiency. The aorta appears normal. The pulmonary artery and associated branches appear normal. There is no evidence of pleural effusion, pericardial effusion, or intracardiac masses.

ULTRASONOGRAPHIC FINDINGS

- Myxomatous mitral valve disease, stage B-1

INTERPRETATION OF THE FINDINGS & FURTHER RECOMMENDATIONS



PATIENT

No medications are necessary. Recheck is recommended in one year, unless there are any concerns prior.

Chewie Erlichman

SPECIES

Canine

BREED

Shih Tzu Mix

SEX

Neutered Male

AGE

9 Years

WEIGHT

18.6 Pounds

INTERPRETED BY

Laurent Locquet, DVM,
 MRCVS, GPCert, (VC)
 Diplomate, ECVIM-CA
 (Cardiology)

IMAGING PERFORMED BY

Rebecca Hamilton

HOSPITAL NAME

Animal General
 Hudson

REFERRING VET

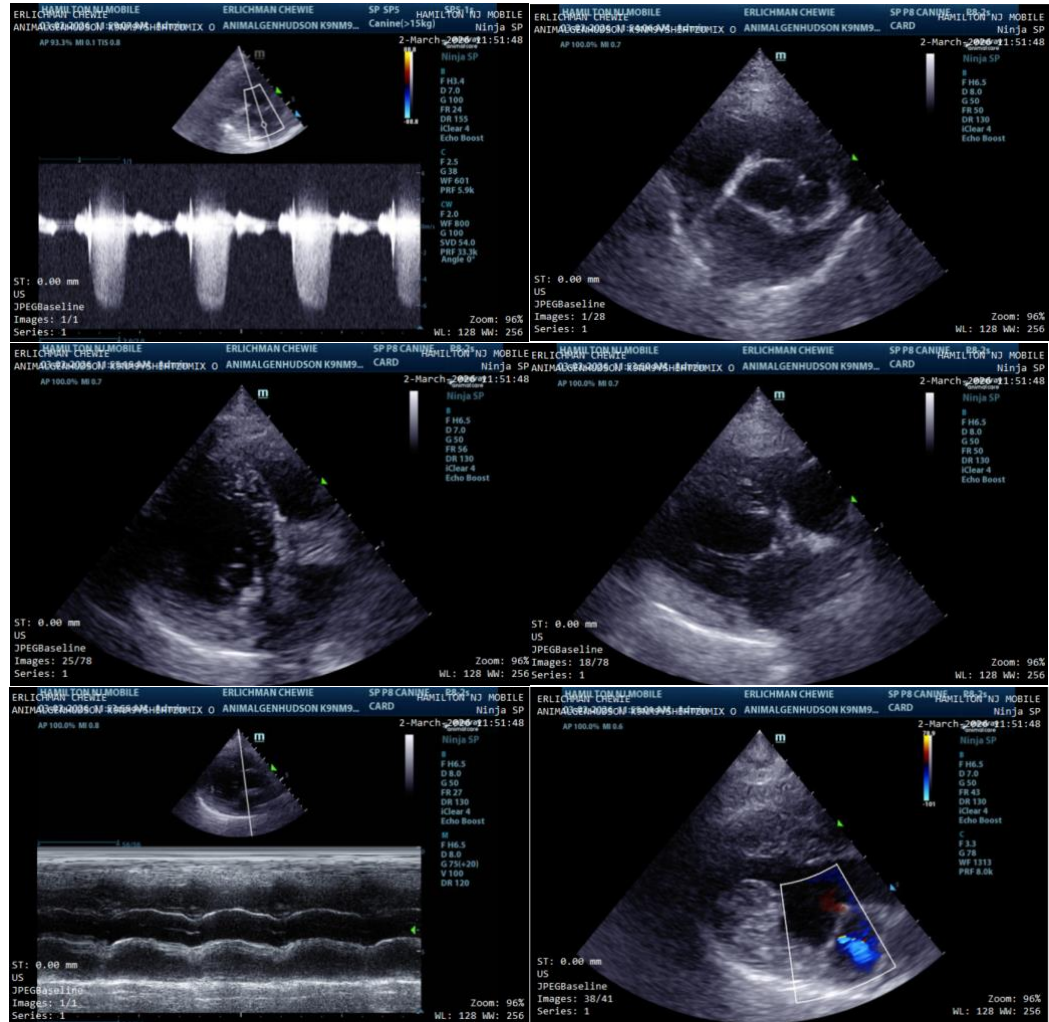
Dr. DiGiuseppi

INVOICE

36064

DATE

3/2/26



The information and recommendations provided are based on the images presented by the referring veterinarian/sonographer. No evaluation can be communicated regarding pathology that was not visible in the image/video clips provided.

Thank you for this referral. If the clinical or image interpretation does not parallel your findings or if I can be of any further assistance please contact me.

Laurent Locquet, DVM MRCVS GPCert (VC) Diplomate ECVIM-CA

info@SonoPath.com