



## PATIENT

Hunter Brandis

## SPECIES

Canine

## BREED

Lab Mix

## SEX

Neutered Male

## AGE

11.7 Years

## WEIGHT

79

## INTERPRETED BY

Laurent Locquet, DVM,  
MRCVS, GPCert, (VC)  
Diplomate, ECVIM-CA  
(Cardiology)

## IMAGING PERFORMED BY

Dr. Becky Meier-Gast

## HOSPITAL NAME

Meier Veterinary Clinic  
PC

## REFERRING VET

Dr. Becky Meier-Gast

## INVOICE

14429

## DATE

03/18/26

## PRESENTING CLINICAL SIGNS

- Hunter presented for routine vaccines and exam. Alex mentioned that Hunter has had an intermittent cough which has been progressively increasing for the last couple of months

Abnormal PE/Chem/CBC/UA Results: Radiographs- mixed interstitial/ bronchial pattern , DV view- minimal amount of pleural fluid possible

## ULTRASONOGRAPHIC EXAMINATION OF THE HEART

CANINE CARDIAC PARAMETERS	MR VMAX (m/s)	TR VMAX (m/s)	LA/AO (M-Mode)	LA/AO (Heart Base; Swe)	FS (%)	EF (%)	EPSS (cm)
NORMAL PARAMETER	4.5-5.5	<2.7	1.3	Up to 1.6	28-40	40-100	<0.6
PATIENT	6.18	2.71	1.02	1.58	27	53	NM
CANINE CARDIAC PARAMETERS	HR (BPM)	AV VMAX (m/s)	PV MAX (m/s)	BODY WEIGHT	LAD LA MAX 4 Chamber	LVIDd Avg; 2D and m-mode short axis (cm)	LVIDs Avg; 2D and m-mode short axis (cm)
NORMAL PARAMETER	50-100	0.7-1.7	0.7-1.6				
PATIENT	NM	1.02	.050	79	39.7 mm	4.43	3.23

## Cardiac Presentation

The left atrium was normal in all 3 views. The mitral valve shows myxomatous changes compatible with myxomatous mitral valve disease and moderate mitral valve regurgitation. The left ventricle was normal. The myocardium was normal. Contractility was normal. Left ventricular outflow tract was normal. The right atrium was normal. No evidence of masses. Severe tricuspid valve regurgitation was evident. The right ventricle was normal. The pulmonic tract was normal. No visible pericardial effusion or pleural effusion. The cranial mediastinum and pericardial regions were free of masses in the visible windows.

## ULTRASONOGRAPHIC FINDINGS

- Myxomatous mitral valve disease with moderate MR and concurrent severe TR.

## INTERPRETATION OF THE FINDINGS & FURTHER RECOMMENDATIONS

No medication is necessary. Recheck is suggested in one year unless there are any concerns prior.



**PATIENT**

Hunter Brandis

**SPECIES**

Canine

**BREED**

Lab Mix

**SEX**

Neutered Male

**AGE**

11.7 Years

**WEIGHT**

79

**INTERPRETED BY**

Laurent Locquet, DVM,  
MRCVS, GPCert, (VC)  
Diplomate, ECVIM-CA  
(Cardiology)

**IMAGING  
PERFORMED BY**

Dr. Becky Meier-Gast

**HOSPITAL NAME**

Meier Veterinary Clinic  
PC

**REFERRING VET**

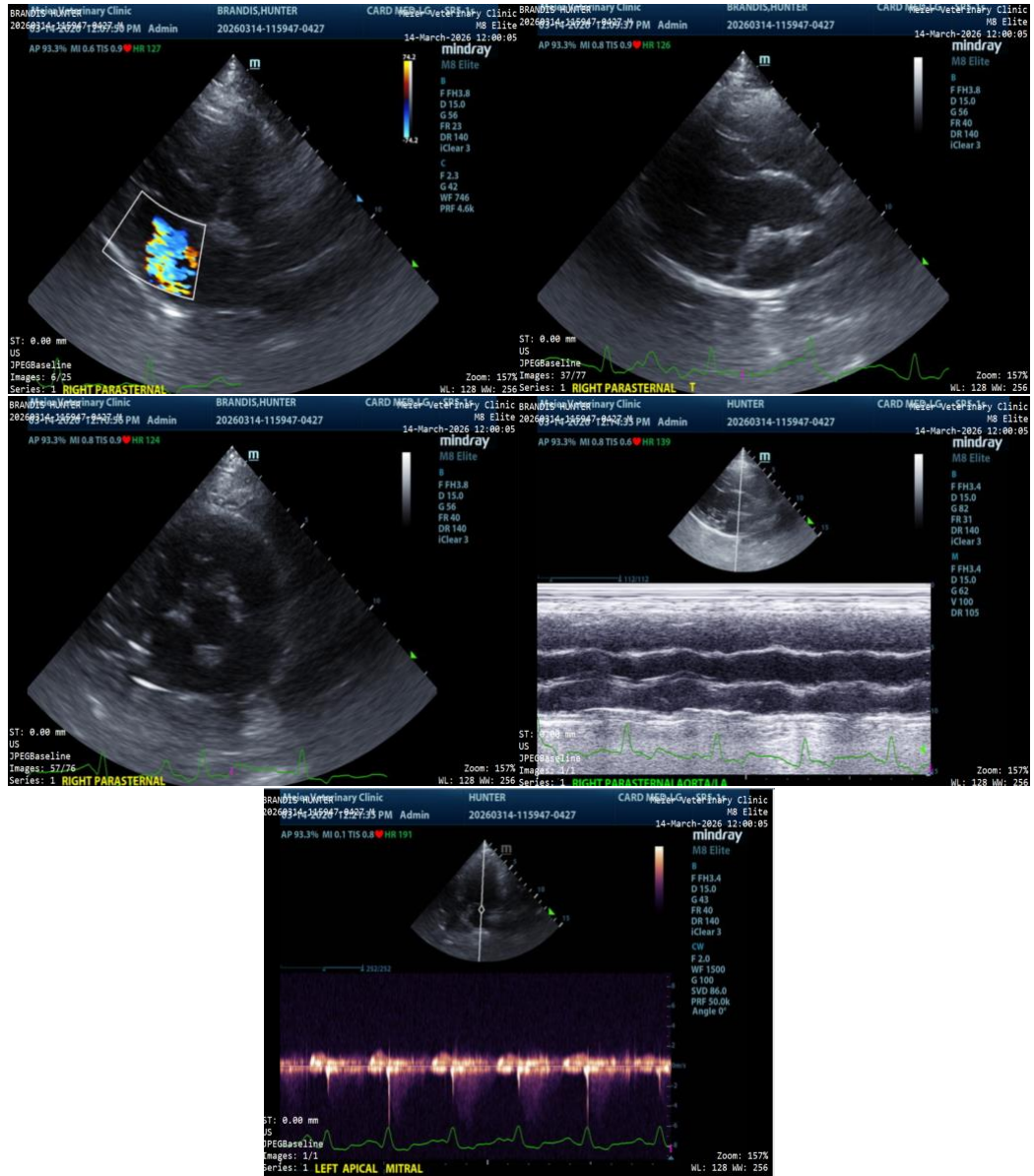
Dr. Becky Meier-Gast

**INVOICE**

14429

**DATE**

03/18/26



The information and recommendations provided are based on the images presented by the referring veterinarian/sonographer. No evaluation can be communicated regarding pathology that was not visible in the image/video clips provided.

Thank you for this referral. If the clinical or image interpretation does not parallel your findings or if I can be of any further assistance please contact me.

Laurent Locquet, DVM, MRCVS, GPCert, (VC) Diplomate, ECVIM-CA (Cardiology)

[info@SonoPath.com](mailto:info@SonoPath.com)