

PATIENT

Murphy Zerykier

SPECIES

Canine

BREED

Cavalier

SEX

Neutered Male

AGE

11 Years

WEIGHT

20.9 pounds

INTERPRETED BY

Laurent Locquet, DVM,
MRCVS, GPCert, (VC)
Diplomate, ECVIM-CA
(Cardiology)

IMAGING PERFORMED BY

Meghan Morse LVT
CVT

HOSPITAL NAME

Farview Animal Clinic

REFERRING VET

Dr. Mosaad

INVOICE

13643

DATE

02/09/26

PRESENTING CLINICAL SIGNS

- Grade III heart murmur, coughing daily
- No current meds

ULTRASONOGRAPHIC EXAMINATION OF THE HEART

CANINE CARDIAC PARAMETERS	MR VMAX (m/s)	TR VMAX (m/s)	LA/AO (M-Mode)	LA/AO (Heart Base; Swe)	FS (%)	EF (%)	EPSS (cm)
NORMAL PARAMETER	4.5-5.5	<2.7	1.3	Up to 1.6	28-40	40-100	<0.6
PATIENT	5.58	--	1.12	1.58	33	62	0.33
CANINE CARDIAC PARAMETERS	HR (BPM)	AV VMAX (m/s)	PV MAX (m/s)	BODY WEIGHT (lbs)	LAD LA MAX 4 Chamber	LVIDd Avg; 2D and m-mode short axis (cm)	LVIDs Avg; 2D and m-mode short axis (cm)
NORMAL PARAMETER	50-100	0.7-1.7	0.7-1.6				
PATIENT	NM	1.18	0.73	20.9	2.35	3.24	2.18

Cardiac Presentation

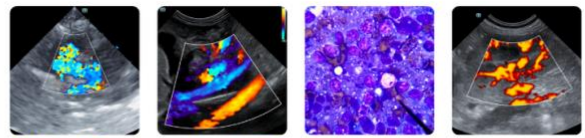
The mitral valve leaflets are mildly thickened with severe mitral regurgitation posteriorly directed. There is **no** prolapse of the mitral valve leaflets. The left atrial size is normal. Left ventricular internal dimensions during diastole are within normal limits and systolic function is preserved in the face of mitral regurgitation. There is normal right atrial size without tricuspid regurgitation. There is no prolapse of the tricuspid valve leaflets and no evidence of pulmonary hypertension based upon tricuspid regurgitant velocities. The right ventricle subjectively appears normal in structure and function. The aortic and pulmonic valves have normal morphology and the corresponding outflow velocities are within normal limits. There is no evidence of pulmonic or aortic insufficiency. The aorta appears normal. The pulmonary artery and associated branches appear normal. There is no evidence of pleural effusion, pericardial effusion, or intracardiac masses.

ULTRASONOGRAPHIC FINDINGS

- Myxomatous mitral valve disease stage B1 with severe mitral valve regurgitation.

INTERPRETATION OF THE FINDINGS & FURTHER RECOMMENDATIONS

A thoracic radiograph is recommended for further investigation of the coughing. Medical management should be adjusted accordingly. Annual recheck is recommended.



PATIENT

Murphy Zerykier

SPECIES

Canine

BREED

Cavalier

SEX

Neutered Male

AGE

11 Years

WEIGHT

20.9 pounds

INTERPRETED BY

Laurent Locquet, DVM,
 MRCVS, GPCert, (VC)
 Diplomate, ECVIM-CA
 (Cardiology)

IMAGING PERFORMED BY

Meghan Morse LVT
 CVT

HOSPITAL NAME

Farview Animal Clinic

REFERRING VET

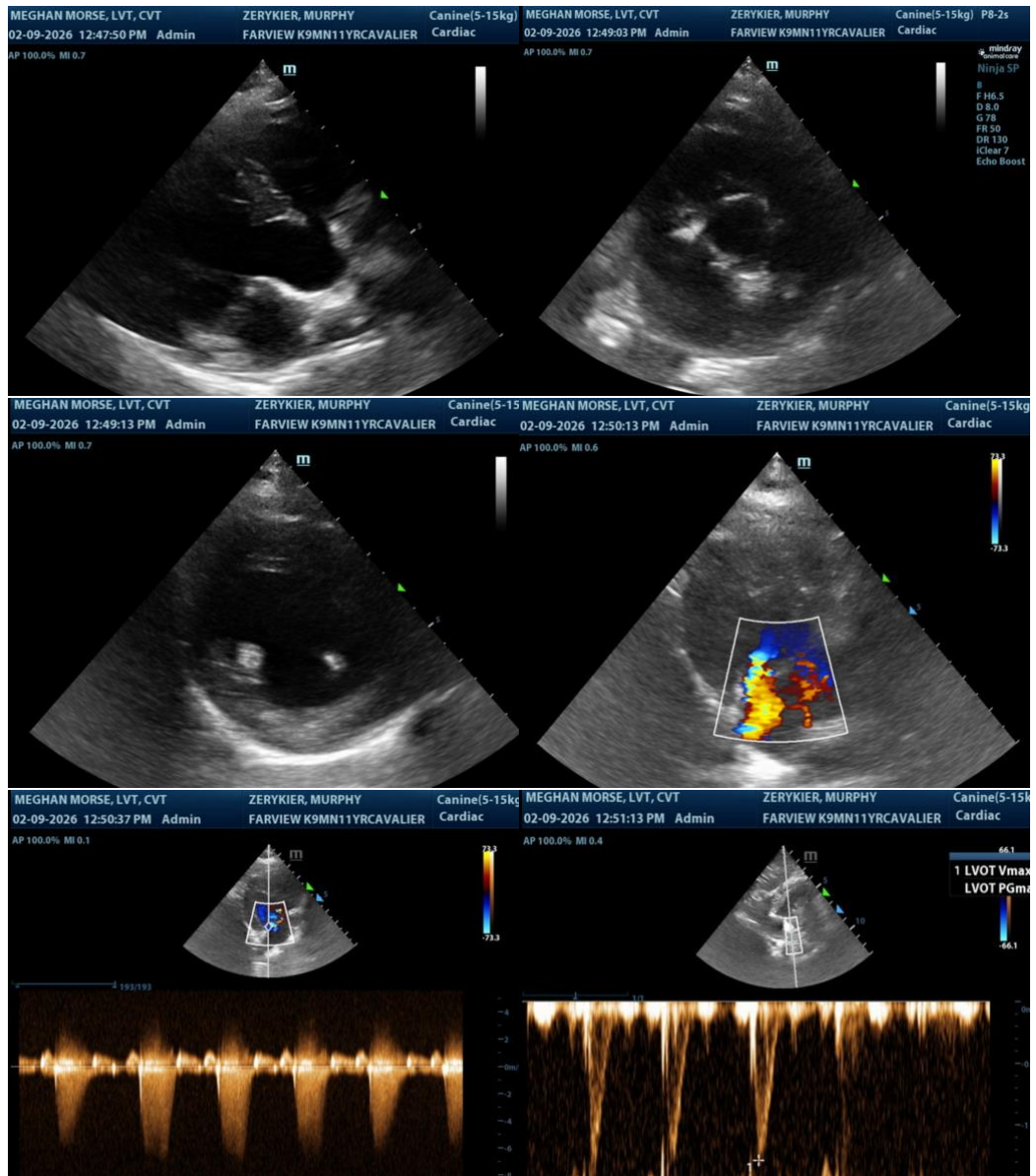
Dr. Mosaad

INVOICE

13643

DATE

02/09/26



The information and recommendations provided are based on the images presented by the referring veterinarian/sonographer. No evaluation can be communicated regarding pathology that was not visible in the image/video clips provided.

Thank you for this referral. If the clinical or image interpretation does not parallel your findings or if I can be of any further assistance please contact me.

Laurent Locquet, DVM, MRCVS, GPCert, (VC) Diplomate, ECVIM-CA (Cardiology)

info@SonoPath.com