



**PATIENT PRESENTING CLINICAL SIGNS**

- Bear Gummer**
- New murmur on exam
- SPECIES**
- Grade I/VI L apex, mid systolic click
- Canine**
- Current meds: Zenrelia

**BREED ULTRASONOGRAPHIC EXAMINATION OF THE HEART**

Beagle

**SEX**

Neutered Male

**AGE**

11 Years

**WEIGHT**

47 Pounds

**INTERPRETED BY**

Laurent Locquet, DVM  
 MRCVS GPCert (VC)  
 Diplomate ECVIM-CA

CANINE CARDIAC PARAMETERS	MR VMAX (m/s)	TR VMAX (m/s)	LA/AO (M-Mode)	LA/AO (Heart Base; Swe)	FS (%)	EF (%)	EPSS (cm)
<b>NORMAL PARAMETER</b>	4.5-5.5	<2.7	1.3	Up to 1.6	28-40	40-100	<0.6
<b>PATIENT</b>	5.1	--	1.18	1.20	23	46	NM
CANINE CARDIAC PARAMETERS	HR (BPM)	AV VMAX (m/s)	PV MAX (m/s)	BODY WEIGHT (lbs)	LAD LA MAX 4 Chamber	LVIDd Avg; 2D and m-mode short axis (cm)	LVIDs Avg; 2D and m-mode short axis (cm)
<b>NORMAL PARAMETER</b>	50-100	0.7-1.7	0.7-1.6				
<b>PATIENT</b>	--	1.45	1.20	47 lbs	36 mm	4.66	3.57

**IMAGING PERFORMED BY**

Meghan Turner, LVT,  
 CVT

**HOSPITAL NAME**

Kingston AH

**REFERRING VET**

Dr. Turner

**INVOICE**

35969

**DATE**

2/25/26

**Cardiac Presentation**

The mitral valve leaflets are mildly thickened with moderate mitral regurgitation posteriorly directed. There is no prolapse of the mitral valve leaflet. The left atrial size is normal. Left ventricular internal dimensions during diastole are within normal limits and systolic function is preserved in the face of mitral regurgitation. There is normal right atrial size with very mild tricuspid regurgitation. There is no prolapse of the tricuspid valve leaflets and no evidence of pulmonary hypertension based upon tricuspid regurgitant velocities. The right ventricle subjectively appears normal in structure and function. The aortic and pulmonic valves have normal morphology and the corresponding outflow velocities are within normal limits. There is no evidence of pulmonic or aortic insufficiency. The aorta appears normal. The pulmonary artery and associated branches appear normal. There is no evidence of pleural effusion, pericardial effusion, or intracardiac masses.

**ULTRASONOGRAPHIC FINDINGS**

- Myxomatous mitral valve disease, stage B-1
- Moderate mitral regurgitation
- Concurrent very mild tricuspid valve regurgitation

**INTERPRETATION OF THE FINDINGS & FURTHER RECOMMENDATIONS**



**PATIENT**

No medications are necessary. Recommend recheck in one year, unless there are any concerns prior.

Bear Gummer

**SPECIES**

Canine

**BREED**

Beagle

**SEX**

Neutered Male

**AGE**

11 Years

**WEIGHT**

47 Pounds

**INTERPRETED BY**

Laurent Locquet, DVM  
 MRCVS GPCert (VC)  
 Diplomate ECVIM-CA

**IMAGING PERFORMED BY**

Meghan Turner, LVT,  
 CVT

**HOSPITAL NAME**

Kingston AH

**REFERRING VET**

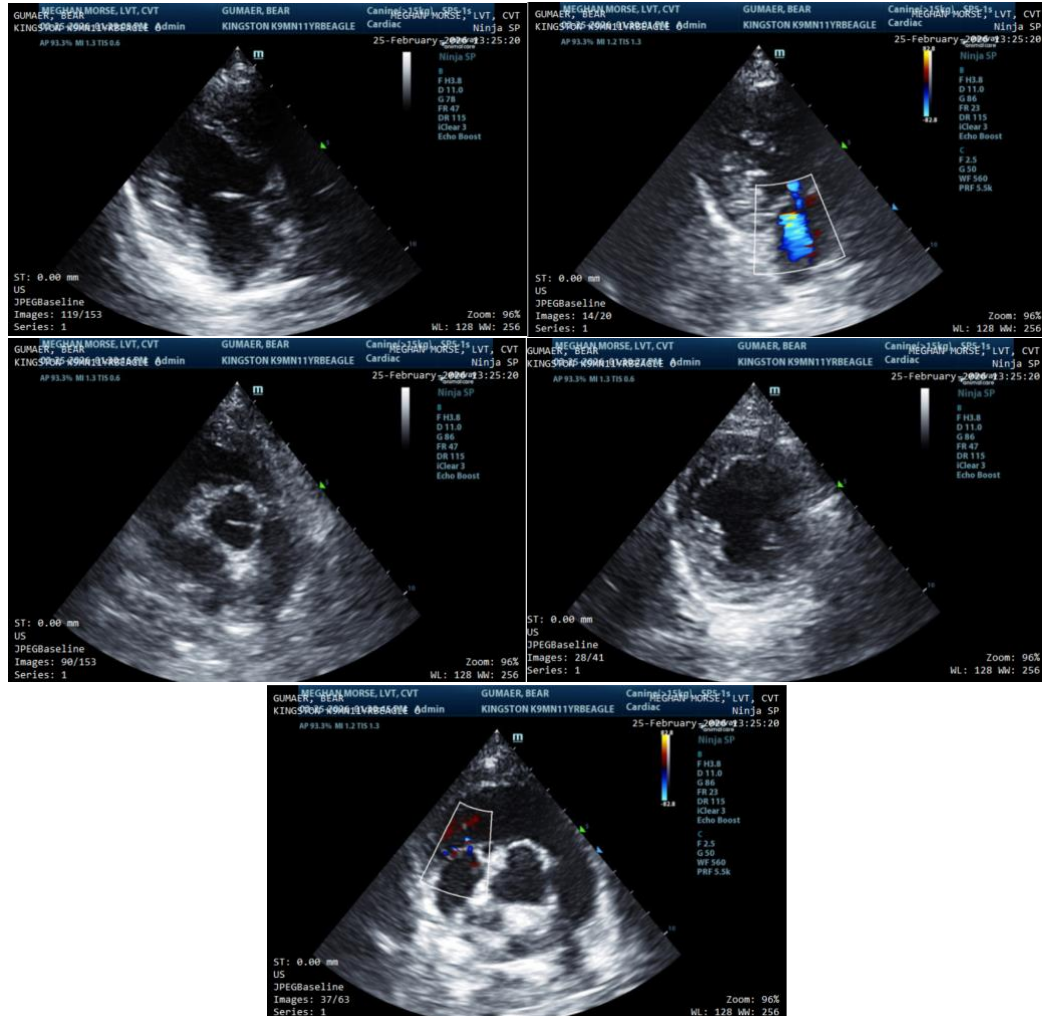
Dr. Turner

**INVOICE**

35969

**DATE**

2/25/26



The information and recommendations provided are based on the images presented by the referring veterinarian/sonographer. No evaluation can be communicated regarding pathology that was not visible in the image/video clips provided.

Thank you for this referral. If the clinical or image interpretation does not parallel your findings or if I can be of any further assistance please contact me.

Laurent Locquet, DVM MRCVS GPCert (VC) Diplomate ECVIM-CA

[info@SonoPath.com](mailto:info@SonoPath.com)