



**PATIENT**

Kali Colon

**SPECIES**

Feline

**BREED**

DSH

**SEX**

Spayed Female

**AGE**

17

**WEIGHT**

3.46

**INTERPRETED BY**

Laurent Locquet, DVM,  
MRCVS, GPCert, (VC)  
Diplomate, ECVIM-CA

**IMAGING PERFORMED BY**

Lauren Kuzimski, DVM

**HOSPITAL NAME**

AEH Deland

**REFERRING VET**

Lauren Kuzimski, DVM

**INVOICE**

35155

**DATE**

12/30/25

**PRESENTING CLINICAL SIGNS**

History: Patient has been having some on and off vomiting the last few days. unknown if she is eating but has been defecating normally. owner noticed leaking from her rear this morning Patient did have a gallop rhythm. Bloodwork did reveal pancreatitis and hyperthyroidism.

Abnormal PE/Chem/CBC/UA Results: CBC. lymphopenia - Chemistry. glucose 164, calcium 8.2 - EPOC. sodium 147, potassium 3.1, glucose 150, BE -9 Other: FpLi. abnormal T4. 5 (elevated) ProBNP. negative/normal.

**ULTRASONOGRAPHIC EXAMINATION OF THE HEART**

FELINE CARDIAC PARAMETERS	BODY WEIGHT	HR (BPM)	IVSd (cm)	LVIDd (cm)	LVWd (cm)	FS (%)	EF (%)
<b>NORMAL PARAMETER</b>	-----	150-240	0.3-0.6	1.0-2.1	0.25-0.6	35-67	80-100
<b>PATIENT</b>	3.46	NM	4.4	1.38	4.1	44	NM
FELINE CARDIAC PARAMETERS	LA/AO (M-mode)	LA/AO HEART BASE (Sisson)	LAD LA MAX 4 Chamber		LVOT VEL. (m/s)	RVOT VEL. (m/s)	IVRT (m/)
<b>NORMAL PARAMETER</b>	<1.5	1.6	0.7-1.7		<1.6	<1.3	40-60
<b>PATIENT</b>	--	1.04	1.33		NM	0.76	NM

Adapted from June Boon, Veterinary Echocardiography, 1998  
Sisson D et al. JVIM 1991; 5: 232, Jacobs et al. Am J Vet Res 1985; 46:1705

**Cardiac Presentation**

The echocardiogram demonstrated normal left atrial size based on three separate measurements, including LAD (left atrial diameter), and LA/Ao using both the Swedish method and the method described by Boon. The cranial and caudal mitral valve leaflets appeared normal in 2D, and color Doppler revealed no mitral valve insufficiency. The left ventricle appeared normal, with normal thickness of both the left ventricular free wall and the interventricular septum. The myocardium presented as normal, without subjective evidence of significant fibrotic or ischemic disease. Contractility of the ventricular walls was adequate and within the normal range for this patient, evidenced by fractional shortening measurements and subjective evaluation of the myocardium from multiple regions and imaging angles. The LVOT demonstrated normal structural appearance in 2D, including a normal aortic valve. Color Doppler and spectral Doppler showed non-turbulent flow with normal velocities. The right atrium and auricle revealed no abnormalities. No evidence of masses was identified. The tricuspid valve appeared normal in 2D, and color Doppler showed no tricuspid insufficiency. The right ventricle was normal in size (approximately one third of the left ventricular diameter) with normal chordae structure, myocardial echogenicity, and wall thickness. The pulmonic tract assessment revealed no abnormalities. The pulmonic valve appeared subjectively normal in 2D;



## PATIENT

Kali Colon

## SPECIES

Feline

## BREED

DSH

## SEX

Spayed Female

## AGE

17

## WEIGHT

3.46

## INTERPRETED BY

Laurent Locquet, DVM,  
MRCVS, GPCert, (VC)  
Diplomate, ECVIM-CA

## IMAGING PERFORMED BY

Lauren Kuzimski, DVM

## HOSPITAL NAME

AEH Deland

## REFERRING VET

Lauren Kuzimski, DVM

## INVOICE

35155

## DATE

12/30/25

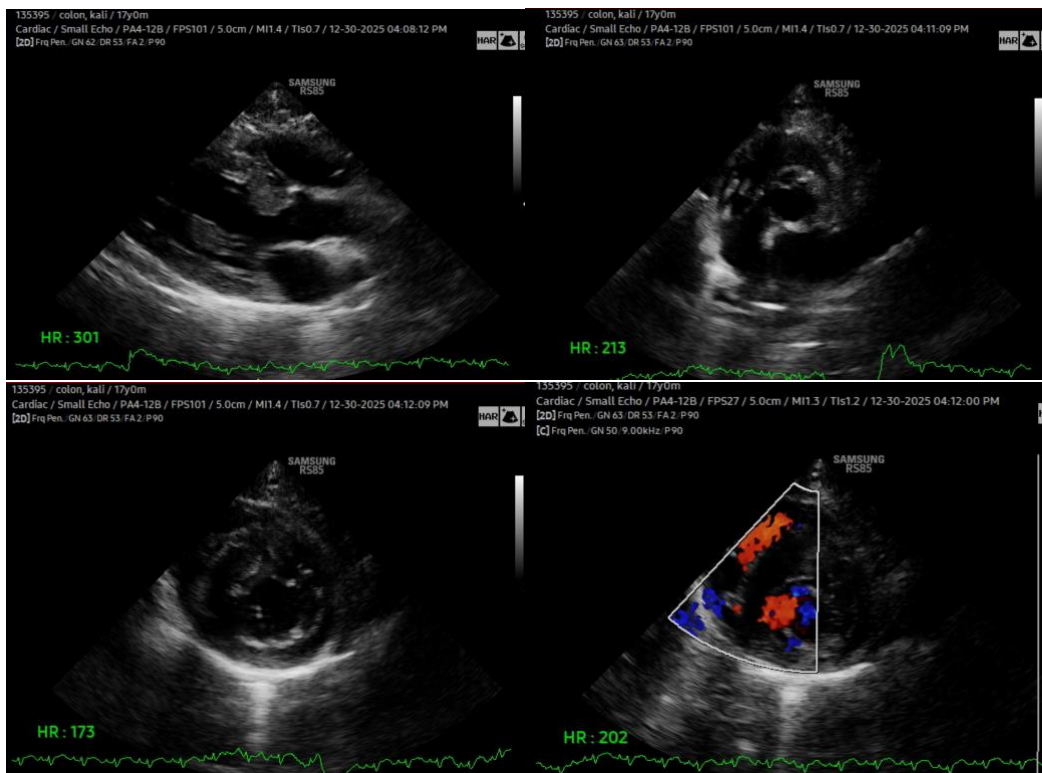
color Doppler identified no turbulent flow, and velocities were within reference ranges. No visible pericardial or pleural effusion was noted, and no extracardiac pathology was detected in the visible imaging planes. The cranial mediastinal and pericardial regions were free of visible masses.

## ULTRASONOGRAPHIC FINDINGS

- Normal feline echocardiogram

## INTERPRETATION OF THE FINDINGS & FURTHER RECOMMENDATIONS

No recheck is necessary, unless there are concerns.



The information and recommendations provided are based on the images presented by the referring veterinarian/sonographer. No evaluation can be communicated regarding pathology that was not visible in the image/video clips provided.

Thank you for this referral. If the clinical or image interpretation does not parallel your findings or if I can be of any further assistance please contact me.

**Laurent Locquet, DVM MRCVS GPCert (VC) Diplomate ECVIM-CA**

[info@SonoPath.com](mailto:info@SonoPath.com)



## PATIENT

Kali Colon

## SPECIES

Feline

## BREED

DSH

## SEX

Spayed Female

## AGE

17

## WEIGHT

3.46

## INTERPRETED BY

Laurent Locquet, DVM,  
MRCVS, GPCert, (VC)  
Diplomate, ECVIM-CA

## IMAGING PERFORMED BY

Lauren Kuzimski, DVM

## HOSPITAL NAME

AEH Deland

## REFERRING VET

Lauren Kuzimski, DVM

## INVOICE

35155

## DATE

12/30/25