



PATIENT

Herr Hoffmann
Westerhorstmann

SPECIES

Feline

BREED

Sphynx

SEX

Neutered Male

AGE

8 Years

WEIGHT

6.95

INTERPRETED BY

Laurent Locquet, DVM
MRCVS GPCert (VC)
Diplomate ECVIM-CA

IMAGING PERFORMED BY

Dr. Kuzimski

HOSPITAL NAME

AEH Deland

REFERRING VET

Dr. Kuzimski

INVOICE

35156

DATE

12/30/35

PRESENTING CLINICAL SIGNS

History: Newly diagnosed heart murmur

Abnormal PE/Chem/CBC/UA Results: Blood pressure. 143mmHg (#2 cuff, right front, sternal) ECG sent with consultation.

ULTRASONOGRAPHIC EXAMINATION OF THE HEART

FELINE CARDIAC PARAMETERS	BODY WEIGHT	HR (BPM)	IVSd (cm)	LVIDd (cm)	LVWd (cm)	FS (%)	EF (%)
NORMAL PARAMETER	-----	150-240	0.3-0.6	1.0-2.1	0.25-0.6	35-67	80-100
PATIENT	6.95	NM	5.4	1.45	5.5	29	--
FELINE CARDIAC PARAMETERS	LA/AO (M-mode)	LA/AO HEART BASE (Sisson)	LAD LA MAX 4 Chamber		LVOT VEL. (m/s)	RVOT VEL. (m/s)	IVRT (m/)
NORMAL PARAMETER	<1.5	1.6	0.7-1.7		<1.6	<1.3	40-60
PATIENT	--	1.19	1.53		NM	NM	NM

Adapted from June Boon, Veterinary Echocardiography, 1998
Sisson D et al. JVIM 1991; 5: 232, Jacobs et al. Am J Vet Res 1985; 46:1705

ECG Interpretation

Every p-wave was followed by a qrs complex. Every qrs complex was preceded by a p-wave. The qrs complexes are broad with a deep s-wave. Heart rhythm was regular. The heart rate was approximately 200 b/p/m. This is compatible with a sinus tachycardia with a right bundle branch block morphology. This is most likely a coincidental finding. No further tests are necessary.

Cardiac Presentation

The echocardiogram demonstrated normal left atrial size based on three separate measurements, including LAD (left atrial diameter), and LA/Ao using both the Swedish method and the method described by Boon. The cranial and caudal mitral valve leaflets appeared normal in 2D, and color Doppler revealed no mitral valve insufficiency. The left ventricle appeared normal, with normal thickness of both the left ventricular free wall and the interventricular septum. The myocardium presented as normal, without subjective evidence of significant fibrotic or ischemic disease. Contractility of the ventricular walls was adequate and within the normal range for this patient, evidenced by fractional shortening measurements and subjective evaluation of the myocardium from multiple regions and imaging angles. The LVOT demonstrated normal structural appearance in 2D, including a normal aortic valve. Color Doppler and spectral Doppler showed non-turbulent flow with



PATIENT

Herr Hoffmann
Westerhorstmann

SPECIES

Feline

BREED

Sphynx

SEX

Neutered Male

AGE

8 Years

WEIGHT

6.95

INTERPRETED BY

Laurent Locquet, DVM
MRCVS GPCert (VC)
Diplomate ECVIM-CA

IMAGING PERFORMED BY

Dr. Kuzimski

HOSPITAL NAME

AEH Deland

REFERRING VET

Dr. Kuzimski

INVOICE

35156

DATE

12/30/35

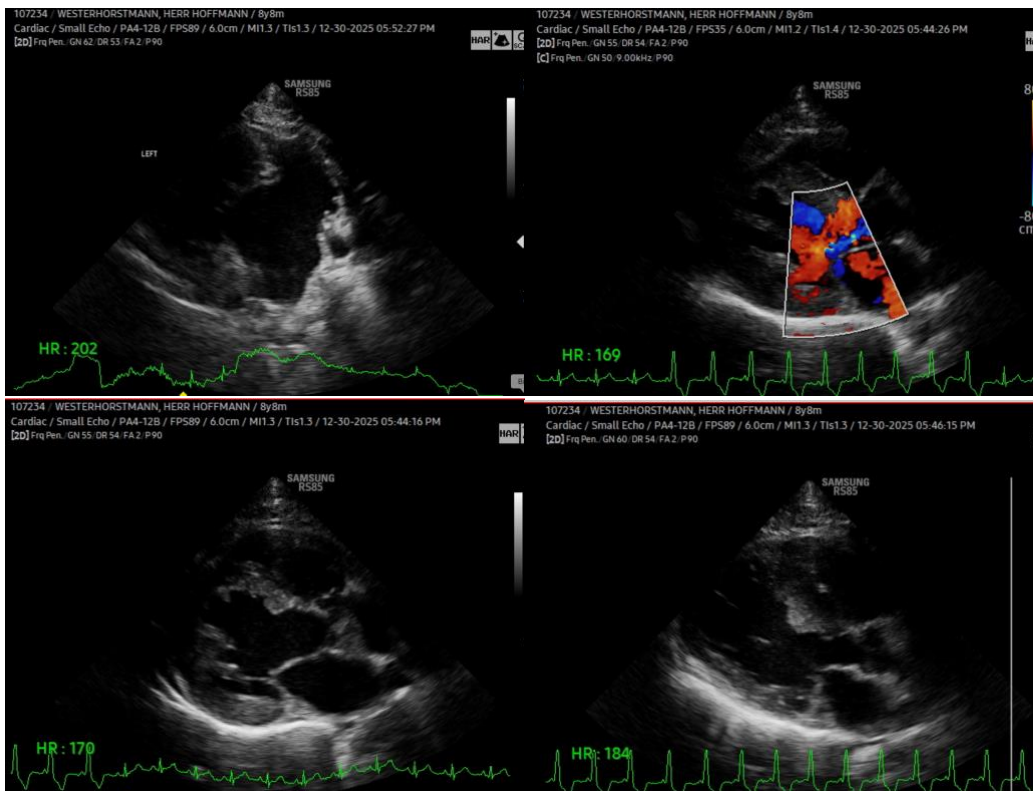
normal velocities. The right atrium and auricle revealed no abnormalities. No evidence of masses was identified. The tricuspid valve appeared normal in 2D, and color Doppler showed no tricuspid insufficiency. The right ventricle was normal in size (approximately one third of the left ventricular diameter) with normal chordae structure, myocardial echogenicity, and wall thickness. The pulmonic tract assessment revealed no abnormalities. The pulmonic valve appeared subjectively normal in 2D; color Doppler identified no turbulent flow, and velocities were within reference ranges. No visible pericardial or pleural effusion was noted, and no extracardiac pathology was detected in the visible imaging planes. The cranial mediastinal and pericardial regions were free of visible masses.

ULTRASONOGRAPHIC FINDINGS

- Sinus tachycardia with a right bundle branch block morphology. This is most likely a coincidental finding.

INTERPRETATION OF THE FINDINGS & FURTHER RECOMMENDATIONS

No further tests are necessary. Recheck is recommended in one year, or earlier in the case of concerns.





PATIENT

Herr Hoffmann
Westerhorstmann

SPECIES

Feline

BREED

Sphynx

SEX

Neutered Male

AGE

8 Years

WEIGHT

6.95

INTERPRETED BY

Laurent Locquet, DVM
MRCVS GPCert (VC)
Diplomate ECVIM-CA

IMAGING PERFORMED BY

Dr. Kuzimski

HOSPITAL NAME

AEH Deland

REFERRING VET

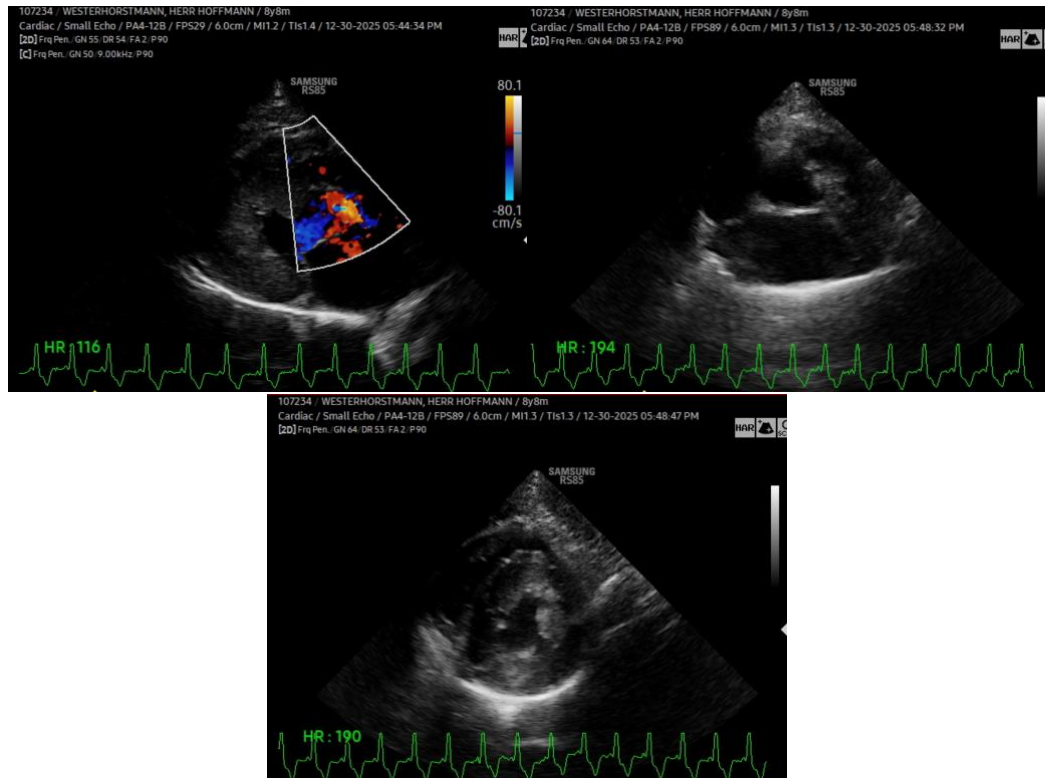
Dr. Kuzimski

INVOICE

35156

DATE

12/30/35



The information and recommendations provided are based on the images presented by the referring veterinarian/sonographer. No evaluation can be communicated regarding pathology that was not visible in the image/video clips provided.

Thank you for this referral. If the clinical or image interpretation does not parallel your findings or if I can be of any further assistance please contact me.

Laurent Locquet, DVM MRCVS GPCert (VC) Diplomate ECVIM-CA

info@SonoPath.com