



PATIENT

Moose Morrongiello

SPECIES

Canine

BREED

Terrier Mix

SEX

Neutered Male

AGE

8 Years

WEIGHT

71 Pounds

INTERPRETED BY

Laurent Locquet, DVM,
 MRCVS, GPCert, (VC)
 Diplomate, ECVIM-CA
 (Cardiology)

IMAGING PERFORMED BY

Rebecca Hamilton

HOSPITAL NAME

Animal General on Hudson

REFERRING VET

Dr. Lang

INVOICE

35038

DATE

12/22/25

PRESENTING CLINICAL SIGNS

History: Grade 2/6 murmur ausculted during pre-dental exam. The owner reports no signs of heart disease.

ULTRASONOGRAPHIC EXAMINATION OF THE HEART

CANINE CARDIAC PARAMETERS	MR VMAX (m/s)	TR VMAX (m/s)	LA/AO (M-Mode)	LA/AO (Heart Base; Swe)	FS (%)	EF (%)	EPSS (cm)
NORMAL PARAMETER	4.5-5.5	<2.7	1.3	Up to 1.6	28-40	40-100	<0.6
PATIENT	--	--	NM	1.26	45	78	0.58
CANINE CARDIAC PARAMETERS	HR (BPM)	AV VMAX (m/s)	PV MAX (m/s)	BODY WEIGHT (lbs)	LAD LA MAX 4 Chamber	LVIDd Avg; 2D and m-mode short axis (cm)	LVIDs Avg; 2D and m-mode short axis (cm)
NORMAL PARAMETER	50-100	0.7-1.7	0.7-1.6				
PATIENT	--	1.74	0.85	71 lbs	3.52	3.57	1.95

Cardiac Presentation

The mitral valve leaflets are mildly thickened with trivial mitral regurgitation posteriorly directed. There is no prolapse of the mitral valve leaflets. The left atrial size is normal. Left ventricular internal dimensions during diastole are within normal limits and systolic function is preserved in the face of mitral regurgitation. There is normal right atrial size without tricuspid regurgitation. There is no prolapse of the tricuspid valve leaflets and no evidence of pulmonary hypertension based upon tricuspid regurgitant velocities. The right ventricle subjectively appears normal in structure and function. The aortic and pulmonic valves have normal morphology and the corresponding outflow velocities are within normal limits. There is no evidence of pulmonic or aortic insufficiency. The aorta appears normal. The pulmonary artery and associated branches appear normal. There is no evidence of pleural effusion, pericardial effusion, or intracardiac masses.

ULTRASONOGRAPHIC FINDINGS

- Myxomatous mitral valve disease, stage B-1 with trivial mitral regurgitation

INTERPRETATION OF THE FINDINGS & FURTHER RECOMMENDATIONS

No medication is necessary. Annual recheck is recommended. The risk for general anesthesia, from a cardiovascular point of view, is not significantly increased based on this examination.



PATIENT

Moose Morrongiello

SPECIES

Canine

BREED

Terrier Mix

SEX

Neutered Male

AGE

8 Years

WEIGHT

71 Pounds

INTERPRETED BY

Laurent Locquet, DVM,
MRCVS, GPCert, (VC)
Diplomate, ECVIM-CA
(Cardiology)

IMAGING PERFORMED BY

Rebecca Hamilton

HOSPITAL NAME

Animal General on Hudson

REFERRING VET

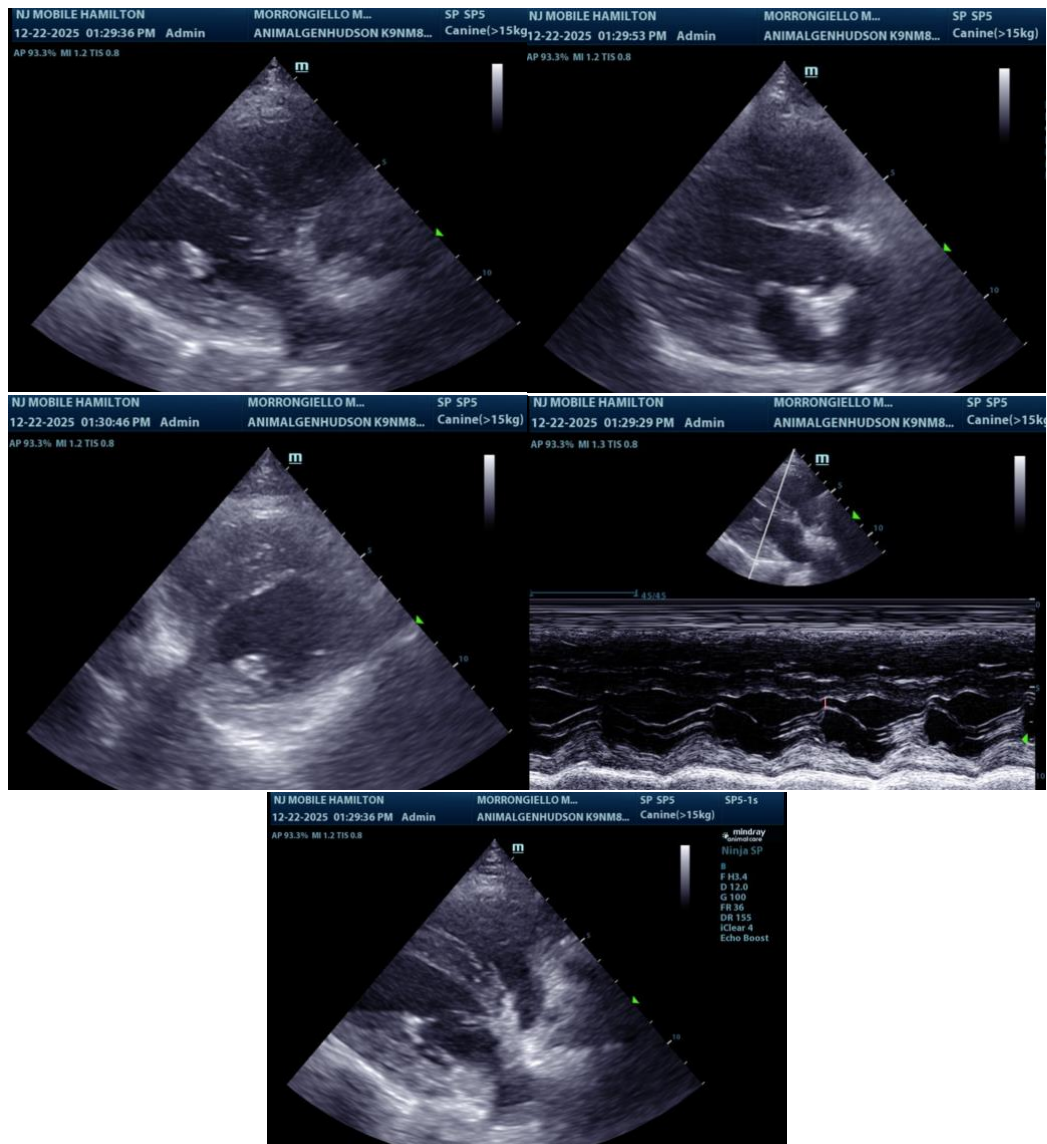
Dr. Lang

INVOICE

35038

DATE

12/22/25



The information and recommendations provided are based on the images presented by the referring veterinarian/sonographer. No evaluation can be communicated regarding pathology that was not visible in the image/video clips provided.

Thank you for this referral. If the clinical or image interpretation does not parallel your findings or if I can be of any further assistance please contact me.

Laurent Locquet, DVM MRCVS GPCert (VC) Diplomate ECVIM-CA

info@SonoPath.com