



PATIENT

Daisy Mayo

SPECIES

Canine

BREED

Terrier Mix

SEX

Spayed Female

AGE

6 Years 2 Months

WEIGHT

11.3 Pounds

INTERPRETED BY

Laurent Locquet, DVM
MRCVS GPCert (VC)
Diplomate ECVIM-CA

IMAGING PERFORMED BY

Rebecca Hamilton

HOSPITAL NAME

Advanced VC

REFERRING VET

Dr. Talile

INVOICE

36851

DATE

12/11/25

PRESENTING CLINICAL SIGNS

History: New heart murmur, Grade 3/6 L sided murmur- no clinical signs at this time. MEDS: Neopolybac ointment for conjunctivitis.

ULTRASONOGRAPHIC EXAMINATION OF THE HEART

CANINE CARDIAC PARAMETERS	MR VMAX (m/s)	TR VMAX (m/s)	LA/AO (M-Mode)	LA/AO (Heart Base; Swe)	FS (%)	EF (%)	EPSS (cm)
NORMAL PARAMETER	4.5-5.5	<2.7	1.3	Up to 1.6	28-40	40-100	<0.6
PATIENT	5.12	--	NM	1.49	50	--	0.2
CANINE CARDIAC PARAMETERS	HR (BPM)	AV VMAX (m/s)	PV MAX (m/s)	BODY WEIGHT (lbs)	LAD LA MAX 4 Chamber	LVIDd Avg; 2D and m-mode short axis (cm)	LVIDs Avg; 2D and m-mode short axis (cm)
NORMAL PARAMETER	50-100	0.7-1.7	0.7-1.6				
PATIENT	--	1.46	1.27	11.3	2.34	2.80	1.40

Cardiac Presentation

The mitral valve leaflets are mildly thickened with mild mitral regurgitation posteriorly directed. There is no prolapse of the mitral valve leaflets. There is very mild left atrial dilation. Left ventricular internal dimensions during diastole are within normal limits and systolic function is preserved in the face of mitral regurgitation. There is normal right atrial size without tricuspid regurgitation. There is no prolapse of the tricuspid valve leaflets and no evidence of pulmonary hypertension based upon tricuspid regurgitant velocities. The right ventricle subjectively appears normal in structure and function. The aortic and pulmonic valves have normal morphology and the corresponding outflow velocities are within normal limits. There is no evidence of pulmonic or aortic insufficiency. The aorta appears normal. The pulmonary artery and associated branches appear normal. There is no evidence of pleural effusion, pericardial effusion, or intracardiac masses.

ULTRASONOGRAPHIC FINDINGS

- Degenerative valve disease, ACVIM stage B-1
- Very mild left atrial dilation

INTERPRETATION OF THE FINDINGS & FURTHER RECOMMENDATIONS

No medications are necessary. Recheck is recommended in 6 months.



PATIENT

Daisy Mayo

SPECIES

Canine

BREED

Terrier Mix

SEX

Spayed Female

AGE

6 Years 2 Months

WEIGHT

11.3 Pounds

INTERPRETED BY

Laurent Locquet, DVM
 MRCVS GPCert (VC)
 Diplomate ECVIM-CA

IMAGING PERFORMED BY

Rebecca Hamilton

HOSPITAL NAME

Advanced VC

REFERRING VET

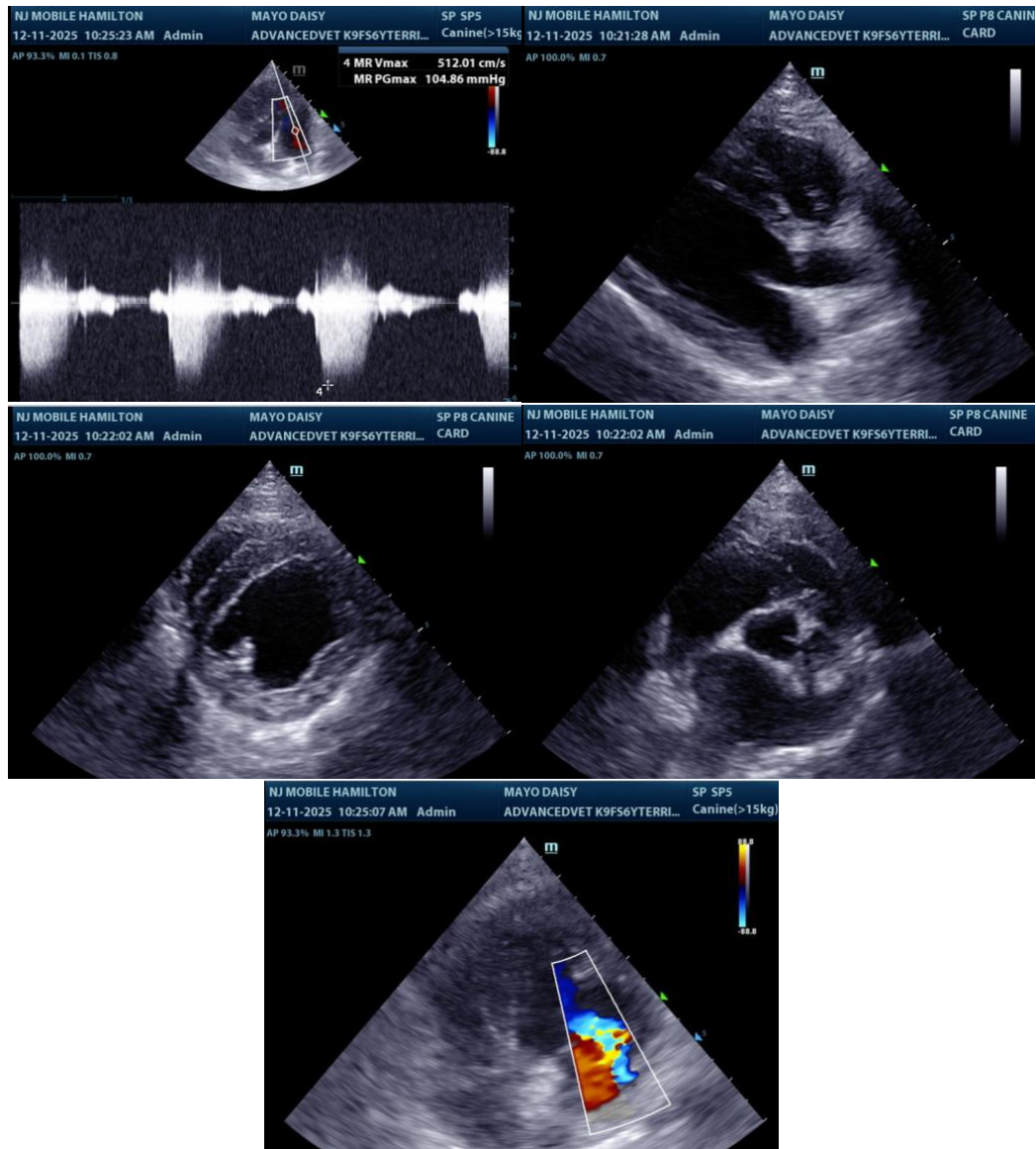
Dr. Talile

INVOICE

36851

DATE

12/11/25



The information and recommendations provided are based on the images presented by the referring veterinarian/sonographer. No evaluation can be communicated regarding pathology that was not visible in the image/video clips provided.

Thank you for this referral. If the clinical or image interpretation does not parallel your findings or if I can be of any further assistance, please contact me.

Laurent Locquet, DVM MRCVS GPCert (VC) Diplomate ECVIM-CA

info@SonoPath.com



PATIENT

Daisy Mayo

SPECIES

Canine

BREED

Terrier Mix

SEX

Spayed Female

AGE

6 Years 2 Months

WEIGHT

11.3 Pounds

INTERPRETED BY

Laurent Locquet, DVM
MRCVS GPCert (VC)
Diplomate ECVIM-CA

**IMAGING
PERFORMED BY**

Rebecca Hamilton

HOSPITAL NAME

Advanced VC

REFERRING VET

Dr. Talile

INVOICE

36851

DATE

12/11/25