



**PATIENT**

Taz Cordero

**SPECIES**

Canine

**BREED**

Mini Schnauzer

**SEX**

Neutered Male

**AGE**

8 Years 10 Months

**WEIGHT**

25 Pounds

**INTERPRETED BY**

Laurent Locquet, DVM,  
 MRCVS, GPCert, (VC)  
 Diplomate, ECVIM-CA  
 (Cardiology)

**IMAGING PERFORMED BY**

Rebecca Hamilton

**HOSPITAL NAME**

North Jersey AH

**REFERRING VET**

Dr. Chiu

**INVOICE**

35418

**DATE**

11/6/25

**PRESENTING CLINICAL SIGNS**

History: HM recheck and coughing (new) HM 5/6, lungs clear. Meds: Pimobendan 2.5 mg po q 12 hours.

**ULTRASONOGRAPHIC EXAMINATION OF THE HEART**

CANINE CARDIAC PARAMETERS	MR VMAX (m/s)	TR VMAX (m/s)	LA/AO (M-Mode)	LA/AO (Heart Base; Swe)	FS (%)	EF (%)	EPSS (cm)
<b>NORMAL PARAMETER</b>	4.5-5.5	<2.7	1.3	Up to 1.6	28-40	40-100	<0.6
<b>PATIENT</b>	5.49	--	NM	1.45	46	NM	0.37
CANINE CARDIAC PARAMETERS	HR (BPM)	AV VMAX (m/s)	PV MAX (m/s)	BODY WEIGHT (kg)	LAD LA MAX 4 Chamber	LVIDd Avg; 2D and m-mode short axis (cm)	LVIDs Avg; 2D and m-mode short axis (cm)
<b>NORMAL PARAMETER</b>	50-100	0.7-1.7	0.7-1.6				
<b>PATIENT</b>	--	1.97	1.05	--	2.76	2.99	1.61

**Cardiac Presentation**

The left atrium was normal in all 3 views. The mitral valve shows myxomatous changes compatible with myxomatous mitral valve disease, as diagnosed before. The left ventricle was normal. The myocardium was normal. Contractility was normal. Left ventricular outflow tract was normal. The right atrium was normal. No evidence of masses. Very mild tricuspid valve regurgitation was noted. The right ventricle was normal. The pulmonic tract was normal. No visible pericardial effusion or pleural effusion. The cranial mediastinum and pericardial regions were free of masses in the visible windows.

**ULTRASONOGRAPHIC FINDINGS**

- ACVIM myxomatous mitral valve disease, stage B-1(stable compared to last year).

**INTERPRETATION OF THE FINDINGS & FURTHER RECOMMENDATIONS**

Annual recheck is recommended. No medication is necessary.



**PATIENT**

Taz Cordero

**SPECIES**

Canine

**BREED**

Mini Schnauzer

**SEX**

Neutered Male

**AGE**

8 Years 10 Months

**WEIGHT**

25 Pounds

**INTERPRETED BY**

Laurent Locquet, DVM,  
 MRCVS, GPCert, (VC)  
 Diplomate, ECVIM-CA  
 (Cardiology)

**IMAGING PERFORMED BY**

Rebecca Hamilton

**HOSPITAL NAME**

North Jersey AH

**REFERRING VET**

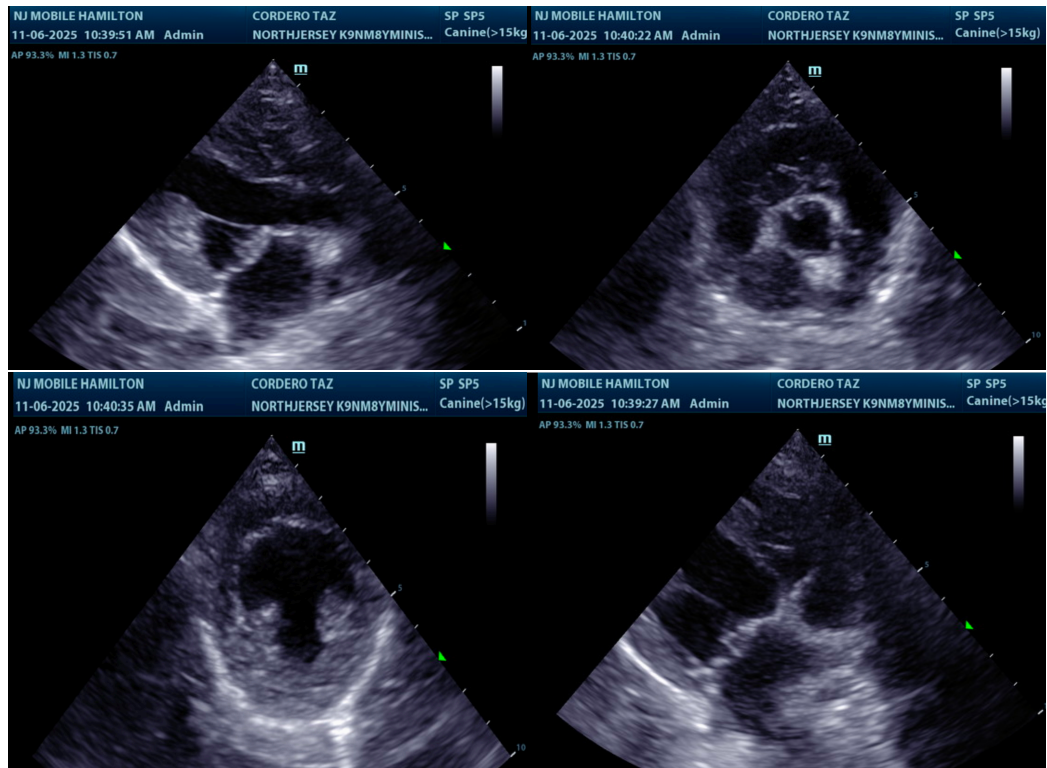
Dr. Chiu

**INVOICE**

35418

**DATE**

11/6/25



**The information and recommendations provided are based on the images presented by the referring veterinarian/sonographer. No evaluation can be communicated regarding pathology that was not visible in the image/video clips provided.**

Thank you for this referral. If the clinical or image interpretation does not parallel your findings or if I can be of any further assistance please contact me.

Sara Brethel DVM, DACVIM (Cardiology)

[info@SonoPath.com](mailto:info@SonoPath.com)