



PATIENT

Luna Schaubhut

SPECIES

Feline

BREED

DLH

SEX

Spayed Female

AGE

11 Years

WEIGHT

11 pounds

INTERPRETED BY

Laurent Locquet, DVM,
 MRCVS, GPCert, (VC)
 Diplomate, ECVIM-CA
 (Cardiology)

IMAGING PERFORMED BY

Meghan Morse, LVT,
 CVT

HOSPITAL NAME

All Animal Veterinary
 Services

REFERRING VET

Dr. Acworth

INVOICE

12114

DATE

11/05/25

PRESENTING CLINICAL SIGNS

Hx of heart murmur, left anterior fascicular block noted on ECG, Murmur grade II/VI No current meds
 Abnormal PE/Chem/CBC/UA Results: Alb 3.6, Ca 8.7, Mag 29

ULTRASONOGRAPHIC EXAMINATION OF THE HEART

FELINE CARDIAC PARAMETERS	BODY WEIGHT (kg)	HR (BPM)	IVSd (cm)	LVIDd (cm)	LVWd (cm)	FS (%)	EF (%)
NORMAL PARAMETER	-----	150-240	0.3-0.6	1.0-2.1	0.25-0.6	35-67	80-100
PATIENT	--	NM	0.48	1.25	0.49	53	87
FELINE CARDIAC PARAMETERS	LA/AO (M-mode)	LA/AO HEART BASE (Sisson)	LAD LA MAX 4 Chamber		LVOT VEL. (m/s)	RVOT VEL. (m/s)	IVRT (m/)
NORMAL PARAMETER	<1.5	1.6	0.7-1.7		<1.6	<1.3	40-60
PATIENT	NM	1.37	1.34		1.35	0.98	NM
Adapted from June Boon, Veterinary Echocardiography, 1998							
Sisson D et al. JVIM 1991; 5: 232, Jacobs et al. Am J Vet Res 1985; 46:1705							

Free Wall: 0.50

Cardiac Presentation

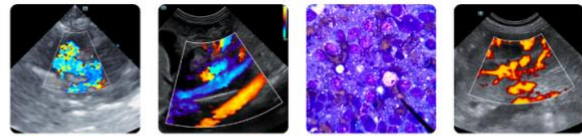
The left atrium was normal in all 3 views. The mitral valve was normal. The left ventricle was normal. The myocardium was normal. Contractility was normal. Left ventricular outflow tract was normal. The right atrium was normal. No evidence of masses. The tricuspid valve was normal. The right ventricle was normal. The pulmonic tract was normal. No visible pericardial effusion or pleural effusion. The cranial mediastinum and pericardial regions were free of masses in the visible windows.

ULTRASONOGRAPHIC FINDINGS

- Functionally and structurally normal heart based on these images.
- Possible idiopathic flow murmur (not hemodynamically significant).

INTERPRETATION OF THE FINDINGS & FURTHER RECOMMENDATIONS

No recheck is necessary unless there are concerns.



PATIENT

Luna Schaubhut

SPECIES

Feline

BREED

DLH

SEX

Spayed Female

AGE

11 Years

WEIGHT

11 pounds

INTERPRETED BY

Laurent Locquet, DVM,
 MRCVS, GPCert, (VC)
 Diplomate, ECVIM-CA
 (Cardiology)

IMAGING PERFORMED BY

Meghan Morse, LVT,
 CVT

HOSPITAL NAME

All Animal Veterinary
 Services

REFERRING VET

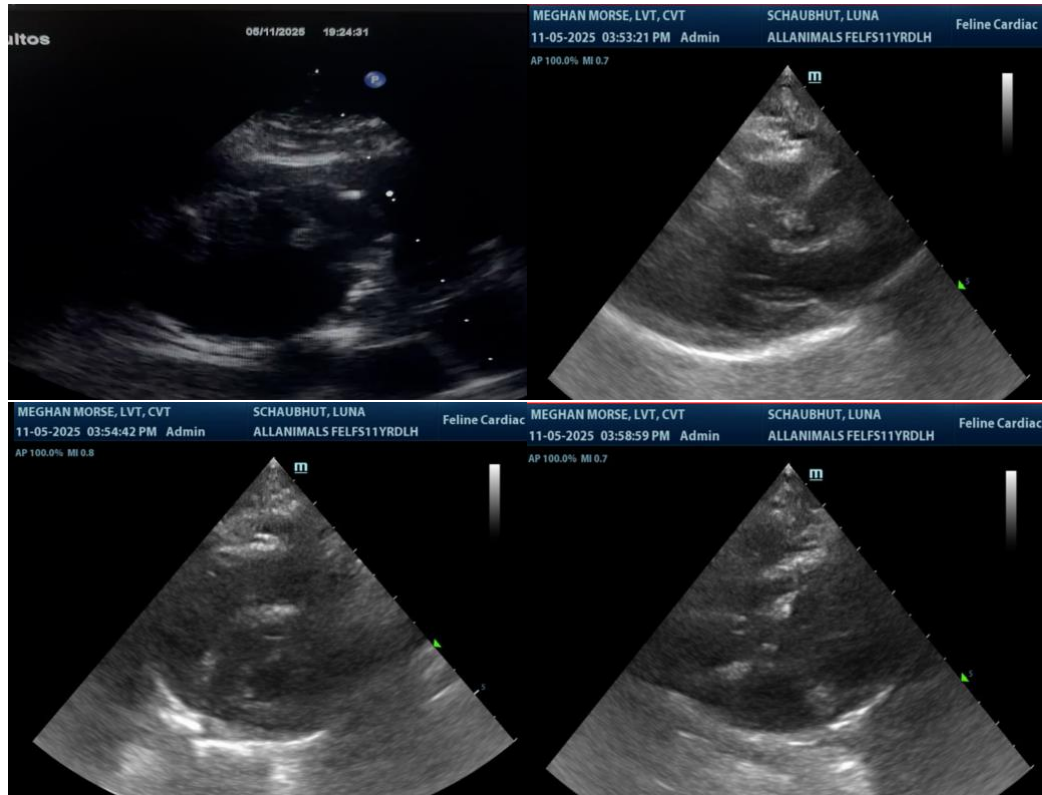
Dr. Acworth

INVOICE

12114

DATE

11/05/25



The information and recommendations provided are based on the images presented by the referring veterinarian/sonographer. No evaluation can be communicated regarding pathology that was not visible in the image/video clips provided.

Thank you for this referral. If the clinical or image interpretation does not parallel your findings or if I can be of any further assistance please contact me.

Laurent Locquet, DVM, MRCVS, GPCert, (VC) Diplomate, ECVIM-CA (Cardiology)

info@SonoPath.com