



**PATIENT**

Ollie Detorres

**SPECIES**

Feline

**BREED**

DSH

**SEX**

Neutered Male

**AGE**

5 Years

**WEIGHT**

14.6 Pounds

**INTERPRETED BY**

Laurent Locquet, DVM,  
 MRCVS, GPCert, (VC)  
 Diplomate, ECVIM-CA  
 (Cardiology)

**IMAGING PERFORMED BY**

Rebecca Hamilton

**HOSPITAL NAME**

The Venturing Vet

**REFERRING VET**

Dr. Herzog

**INVOICE**

35687

**DATE**

11/28/25

**PRESENTING CLINICAL SIGNS**

History: Grade 2/6 heart murmur. no current meds.

**ULTRASONOGRAPHIC EXAMINATION OF THE HEART**

<b>FELINE CARDIAC PARAMETERS</b>	<b>BODY WEIGHT (lb)</b>	<b>HR (BPM)</b>	<b>IVSd (cm)</b>	<b>LVIDd (cm)</b>	<b>LVWd (cm)</b>	<b>FS (%)</b>	<b>EF (%)</b>
<b>NORMAL PARAMETER</b>	-----	150-240	0.3-0.6	1.0-2.1	0.25-0.6	35-67	80-100
<b>PATIENT</b>	14.6	220	0.36	1.96	0.36	55	88
<b>FELINE CARDIAC PARAMETERS</b>	<b>LA/AO (M-mode)</b>	<b>LA/AO HEART BASE (Sisson)</b>	<b>LAD LA MAX 4 Chamber</b>		<b>LVOT VEL. (m/s)</b>	<b>RVOT VEL. (m/s)</b>	<b>IVRT (m/)</b>
<b>NORMAL PARAMETER</b>	<1.5	1.6	0.7-1.7		<1.6	<1.3	40-60
<b>PATIENT</b>	1.21	1.12	1.35		1.11	1.11	NM
Adapted from June Boon, Veterinary Echocardiography, 1998							
Sisson D et al. JVIM 1991; 5: 232, Jacobs et al. Am J Vet Res 1985; 46:1705							

**Cardiac Presentation**

The echocardiogram demonstrated normal left atrial size based on three separate measurements, including LAD (left atrial diameter), and LA/Ao using both the Swedish method and the method described by Boon. The cranial and caudal mitral valve leaflets appeared normal in 2D, and color Doppler revealed no mitral valve insufficiency. The left ventricle appeared normal, with normal thickness of both the left ventricular free wall and the interventricular septum. The myocardium presented as normal, without subjective evidence of significant fibrotic or ischemic disease. Contractility of the ventricular walls was adequate and within the normal range for this patient, evidenced by fractional shortening measurements and subjective evaluation of the myocardium from multiple regions and imaging angles. The LVOT demonstrated normal structural appearance in 2D, including a normal aortic valve. Color Doppler and spectral Doppler showed non-turbulent flow with normal velocities. The right atrium and auricle revealed no abnormalities. No evidence of masses was identified. The tricuspid valve appeared normal in 2D, and color Doppler showed no tricuspid insufficiency. The right ventricle was normal in size (approximately one third of the left ventricular diameter) with normal chordae structure, myocardial echogenicity, and wall thickness. The pulmonic tract assessment revealed no abnormalities. The pulmonic valve appeared subjectively normal in 2D; color Doppler identified no turbulent flow, and velocities were within reference ranges. No visible pericardial or pleural effusion was noted, and no extracardiac pathology was detected in the visible imaging planes. The cranial mediastinal and pericardial regions were free of visible masses.

**ULTRASONOGRAPHIC FINDINGS**



**PATIENT**

Ollie Detorres

**SPECIES**

Feline

**BREED**

DSH

**SEX**

Neutered Male

**AGE**

5 Years

**WEIGHT**

14.6 Pounds

**INTERPRETED BY**

Laurent Locquet, DVM,  
 MRCVS, GPCert, (VC)  
 Diplomate, ECVIM-CA  
 (Cardiology)

**IMAGING PERFORMED BY**

Rebecca Hamilton

**HOSPITAL NAME**

The Venturing Vet

**REFERRING VET**

Dr. Herzog

**INVOICE**

35687

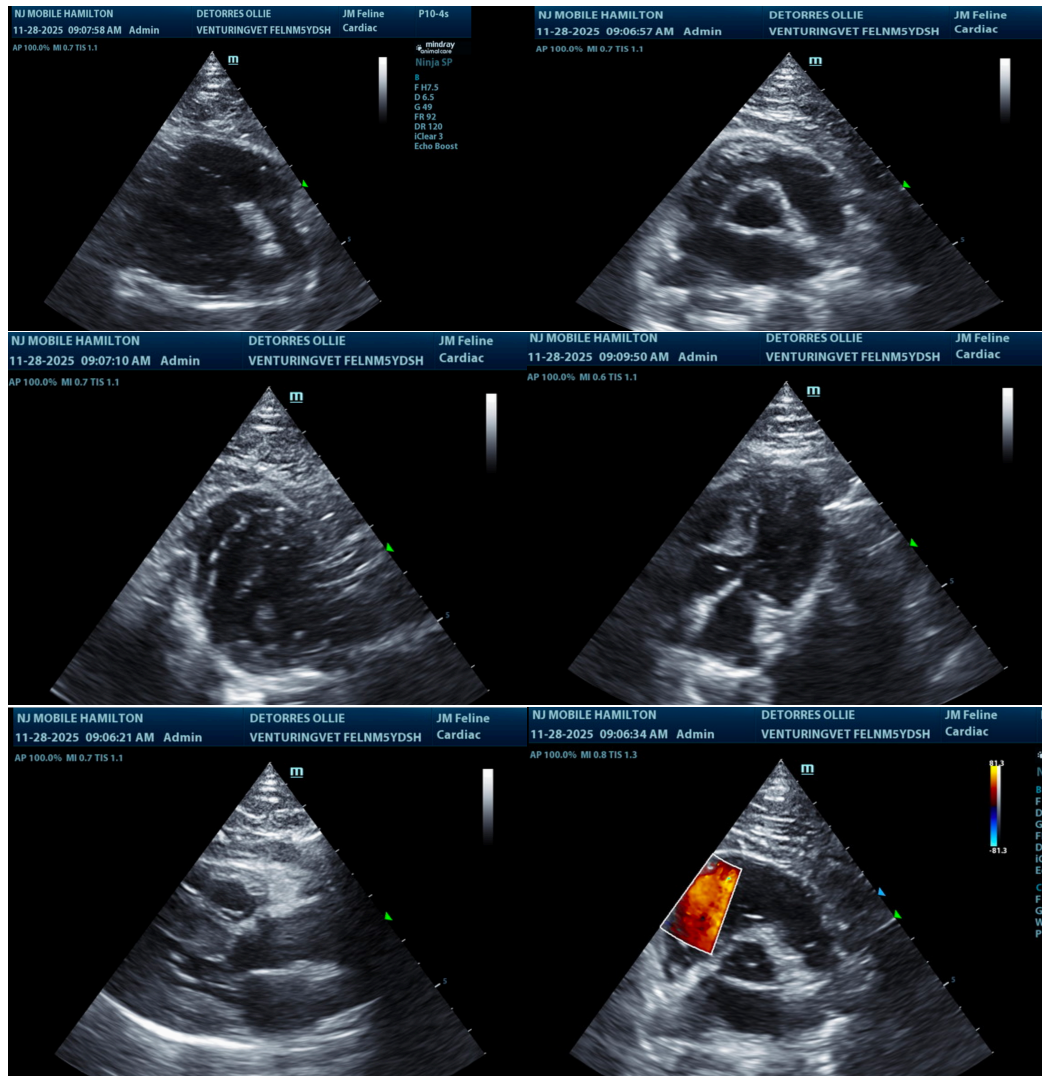
**DATE**

11/28/25

- This heart is functionally and structurally normal based on today's echocardiographic examination.
- Possibly idiopathic flow murmur, not hemodynamically relevant

**INTERPRETATION OF THE FINDINGS & FURTHER RECOMMENDATIONS**

No recheck is necessary unless there are any concerns.



The information and recommendations provided are based on the images presented by the referring veterinarian/sonographer. No evaluation can be communicated regarding pathology that was not visible in the image/video clips provided.



**PATIENT**

Ollie Detorres

**SPECIES**

Feline

**BREED**

DSH

**SEX**

Neutered Male

**AGE**

5 Years

**WEIGHT**

14.6 Pounds

**INTERPRETED BY**

Laurent Locquet, DVM,  
MRCVS, GPCert, (VC)  
Diplomate, ECVIM-CA  
(Cardiology)

**IMAGING  
PERFORMED BY**

Rebecca Hamilton

**HOSPITAL NAME**

The Venturing Vet

**REFERRING VET**

Dr. Herzog

**INVOICE**

35687

**DATE**

11/28/25

Thank you for this referral. If the clinical or image interpretation does not parallel your findings or if I can be of any further assistance please contact me.

**Laurent Locquet, DVM MRCVS GPCert (VC) Diplomate ECVIM-CA**

[info@SonoPath.com](mailto:info@SonoPath.com)