



**PATIENT**

Comet Strum

**SPECIES**

Canine

**BREED**

Chihuahua Mix/Min  
 Pin

**SEX**

Neutered Male

**AGE**

11.3 Years

**WEIGHT**

19.1

**INTERPRETED BY**

Laurent Locquet, DVM,  
 MRCVS, GPCert, (VC)  
 Diplomate, ECVIM-CA

**IMAGING PERFORMED BY**

Ginny Dodd

**HOSPITAL NAME**

Ironton AH

**REFERRING VET**

Dr. Tony Levine

**INVOICE**

35504

**DATE**

11/13/25

**PRESENTING CLINICAL SIGNS**

History: H/O heart murmur in last year. Seen at another hospital for a dental and Vetmedin was prescribed. Blood work 9/25 was normal. No rads taken. Taken back to family DVM and they advised an echo.

Abnormal PE/Chem/CBC/UA Results: Grade 3/6 systolic murmur PMI L 4-5 near base more than apex, mm pink, CRT < 1 sec, nervous even with Butorphanol 0.3 mg IV. Near the end of procedure his HR increased to 154, but he also defecated about that time.

**ULTRASONOGRAPHIC EXAMINATION OF THE HEART**

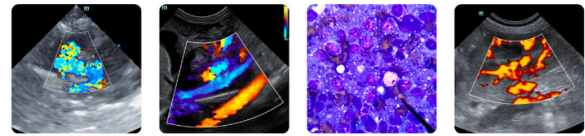
<b>CANINE CARDIAC PARAMETERS</b>	<b>MR VMAX</b> (m/s)	<b>TR VMAX</b> (m/s)	<b>LA/AO</b> (M-Mode)	<b>LA/AO</b> (Heart Base; Swe)	<b>FS</b> (%)	<b>EF</b> (%)	<b>EPSS</b> (cm)
<b>NORMAL PARAMETER</b>	4.5-5.5	<2.7	1.3	Up to 1.6	28-40	40-100	<0.6
<b>PATIENT</b>	NM	--	1.29	1.34	41	75	0.21
<b>CANINE CARDIAC PARAMETERS</b>	<b>HR</b> (BPM)	<b>AV VMAX</b> (m/s)	<b>PV MAX</b> (m/s)	<b>BODY WEIGHT</b> (kg)	<b>LAD</b> LA MAX 4 Chamber	<b>LVIDd</b> Avg; 2D and m-mode short axis (cm)	<b>LVIDs</b> Avg; 2D and m-mode short axis (cm)
<b>NORMAL PARAMETER</b>	50-100	0.7-1.7	0.7-1.6				
<b>PATIENT</b>	103	1.80	--	--	2.29	2.79	1.65

**Cardiac Presentation**

The mitral valve leaflets are mildly thickened with mild mitral regurgitation posteriorly directed. There is no prolapse of the mitral valve leaflets. The left atrial size is normal. Left ventricular internal dimensions during diastole are within normal limits and systolic function is preserved in the face of mitral regurgitation. There is normal right atrial size without tricuspid regurgitation. There is no prolapse of the tricuspid valve leaflets and no evidence of pulmonary hypertension based upon tricuspid regurgitant velocities. The right ventricle subjectively appears normal in structure and function. The aortic and pulmonic valves have normal morphology and the corresponding outflow velocities are within normal limits. There is no evidence of pulmonic or aortic insufficiency. The aorta appears normal. The pulmonary artery and associated branches appear normal. There is no evidence of pleural effusion, pericardial effusion, or intracardiac masses.

**ULTRASONOGRAPHIC FINDINGS**

- Degenerative valve disease ACVIM stage B1



**PATIENT**

Comet Strum

**SPECIES**

Canine

**BREED**

Chihuahua Mix/Min  
 Pin

**SEX**

Neutered Male

**AGE**

11.3 Years

**WEIGHT**

19.1

**INTERPRETED BY**

Laurent Locquet, DVM,  
 MRCVS, GPCert, (VC)  
 Diplomate, ECVIM-CA

**IMAGING PERFORMED BY**

Ginny Dodd

**HOSPITAL NAME**

Ironton AH

**REFERRING VET**

Dr. Tony Levine

**INVOICE**

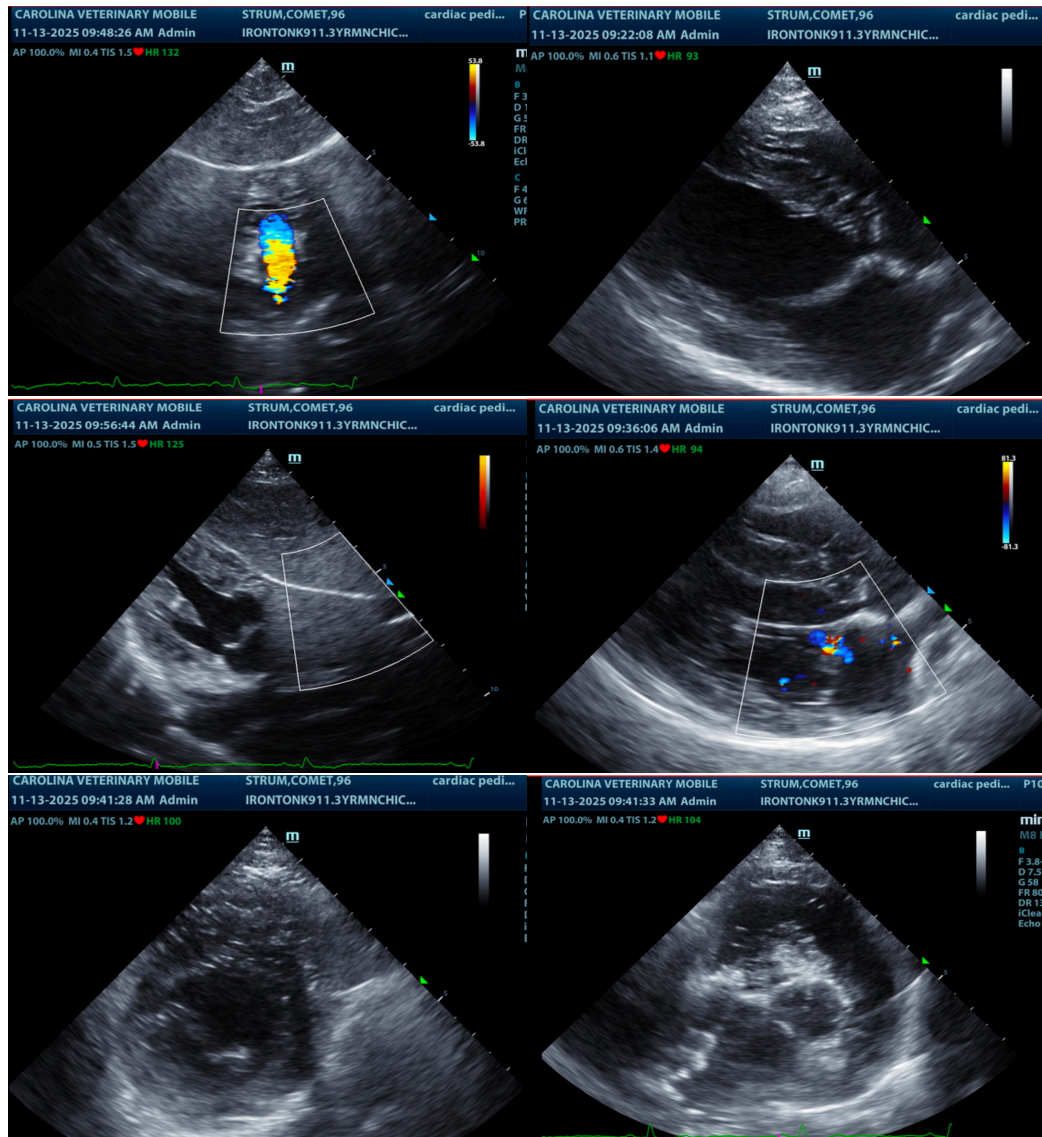
35504

**DATE**

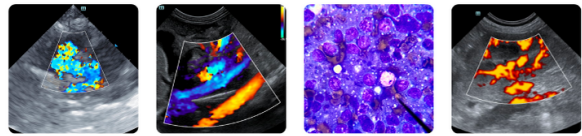
11/13/25

**INTERPRETATION OF THE FINDINGS & FURTHER RECOMMENDATIONS**

The patient has degenerative valve disease ACVIM stage B1 and no cardiac medications are indicated at this time. Since this can be a progressive condition, serial monitoring is recommended. A recheck echocardiogram is recommended in 10-12 months. A sooner recheck is recommended if the patient develops cardiovascular clinical signs or the heart murmur is worsening in intensity. Elective anesthetic procedures should be well tolerated.



The information and recommendations provided are based on the images presented by the referring veterinarian/sonographer. No evaluation can be communicated regarding pathology that was not visible in the image/video clips provided.



**PATIENT**

Comet Strum

**SPECIES**

Canine

**BREED**

Chihuahua Mix/Min  
Pin

**SEX**

Neutered Male

**AGE**

11.3 Years

**WEIGHT**

19.1

**INTERPRETED BY**

Laurent Locquet, DVM,  
MRCVS, GPCert, (VC)  
Diplomate, ECVIM-CA

**IMAGING  
PERFORMED BY**

Ginny Dodd

**HOSPITAL NAME**

Ironton AH

**REFERRING VET**

Dr. Tony Levine

**INVOICE**

35504

**DATE**

11/13/25

Thank you for this referral. If the clinical or image interpretation does not parallel your findings or if I can be of any further assistance please contact me.

**Laurent Locquet, DVM MRCVS GPCert (VC) Diplomate ECVIM-CA**

[info@SonoPath.com](mailto:info@SonoPath.com)