



**PATIENT**

Ziggy Allanello

**SPECIES**

Canine

**BREED**

Chihuahua Mix

**SEX**

Spayed Female

**AGE**

14 Years 9 Months

**WEIGHT**

16 Pounds

**INTERPRETED BY**

Laurent Locquet, DVM,  
MRCVS, GPCert, (VC)  
Diplomate, ECVIM-CA

**IMAGING PERFORMED BY**

Rebecca Hamilton

**HOSPITAL NAME**

Farview AC

**REFERRING VET**

Dr. Mosaad

**INVOICE**

35619

**DATE**

1/29/26

**PRESENTING CLINICAL SIGNS**

- Coughing, Grade 5 heart murmur
- Radiographs show heart is enlarged, mild effusion of the caudal dorsal chest
- Meds: Prozac susp 20mg/5ml- 2 ml once a day, Doxy 100 mg 1/4 tab twice a day

**ULTRASONOGRAPHIC EXAMINATION OF THE HEART**

<b>CANINE CARDIAC PARAMETERS</b>	<b>MR VMAX</b> (m/s)	<b>TR VMAX</b> (m/s)	<b>LA/AO</b> (M-Mode)	<b>LA/AO</b> (Heart Base; Swe)	<b>FS</b> (%)	<b>EF</b> (%)	<b>EPSS</b> (cm)
<b>NORMAL PARAMETER</b>	4.5-5.5	<2.7	1.3	Up to 1.6	28-40	40-100	<0.6
<b>PATIENT</b>	5.60	NM	1.21	1.22	31	74	0.21
<b>CANINE CARDIAC PARAMETERS</b>	<b>HR</b> (BPM)	<b>AV VMAX</b> (m/s)	<b>PV MAX</b> (m/s)	<b>BODY WEIGHT</b> (lbs)	<b>LAD</b> LA MAX 4 Chamber	<b>LVIDd</b> Avg; 2D and m-mode short axis (cm)	<b>LVIDs</b> Avg; 2D and m-mode short axis (cm)
<b>NORMAL PARAMETER</b>	50-100	0.7-1.7	0.7-1.6				
<b>PATIENT</b>	--	1.51	2.83	16 lbs	2.83	2.47	1.46

**Cardiac Presentation**

The mitral valve leaflets are mildly thickened with mild mitral regurgitation posteriorly directed. There is no prolapse of the mitral valve leaflets. The left atrial size is normal. Left ventricular internal dimensions during diastole are within normal limits and systolic function is preserved in the face of mitral regurgitation. There is normal right atrial size without tricuspid regurgitation. There is no prolapse of the tricuspid valve leaflets and no evidence of pulmonary hypertension based upon tricuspid regurgitant velocities. The right ventricle subjectively appears normal in structure and function. The aortic and pulmonic valves have normal morphology and the corresponding outflow velocities are within normal limits. There is no evidence of pulmonic or aortic insufficiency. The aorta appears normal. The pulmonary artery and associated branches appear normal. There is no evidence of pleural effusion, pericardial effusion, or intracardiac masses.

**ULTRASONOGRAPHIC FINDINGS**

- Myxomatous mitral valve disease, stage B-1

**INTERPRETATION OF THE FINDINGS & FURTHER RECOMMENDATIONS**



**PATIENT**

Ziggy Allanello

**SPECIES**

Canine

**BREED**

Chihuahua Mix

**SEX**

Spayed Female

**AGE**

14 Years 9 Months

**WEIGHT**

16 Pounds

**INTERPRETED BY**

Laurent Locquet, DVM,  
 MRCVS, GPCert, (VC)  
 Diplomate, ECVIM-CA

**IMAGING PERFORMED BY**

Rebecca Hamilton

**HOSPITAL NAME**

Farview AC

**REFERRING VET**

Dr. Mosaad

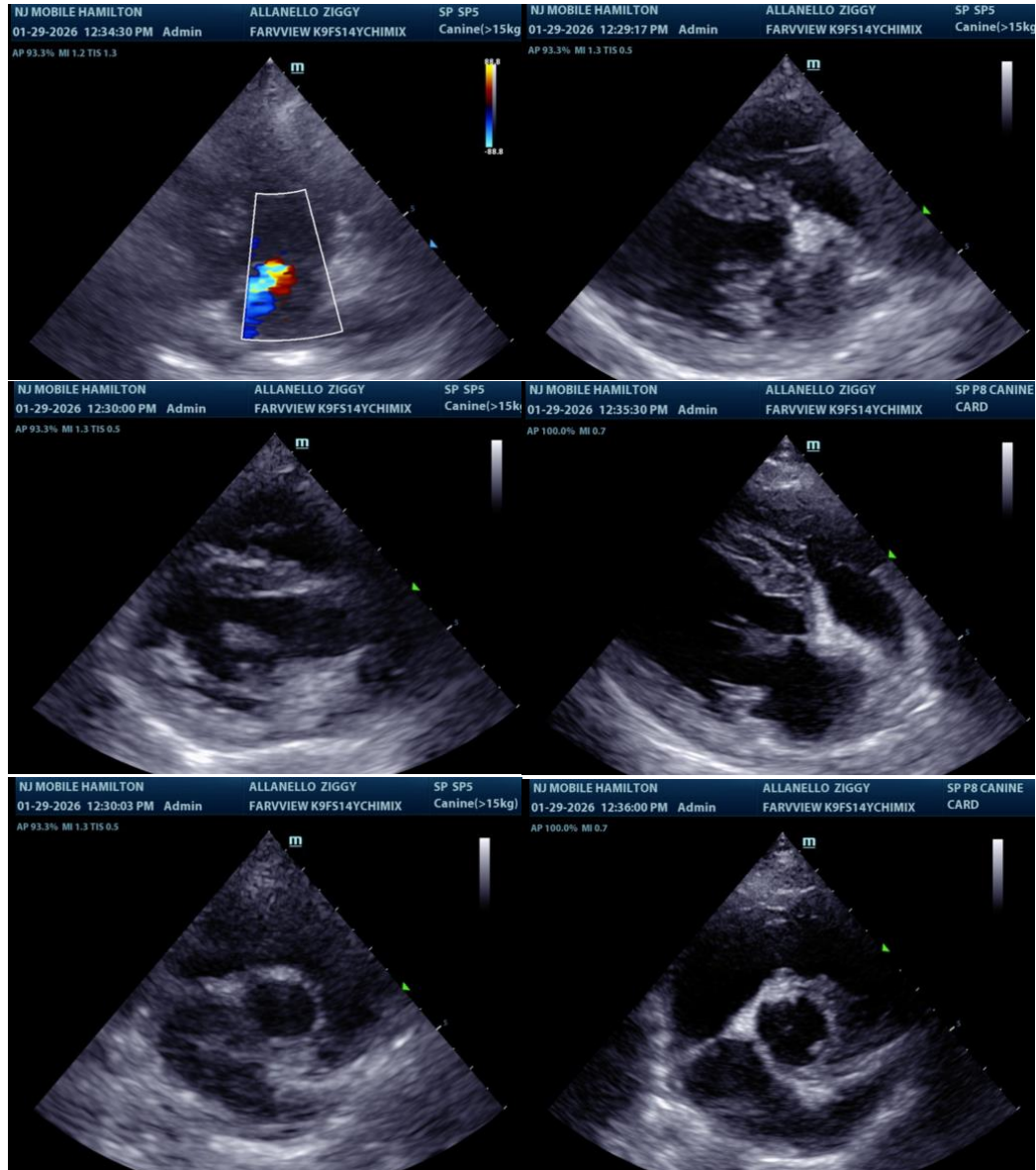
**INVOICE**

35619

**DATE**

1/29/26

The heart is normal in size. Thoracic radiographs are a good screening test for cardiomegaly, but based on these echocardiographic results, the heart is normal in size, which is good. Annual recheck is recommended. No medications are necessary.





**PATIENT**

Ziggy Allanello

**SPECIES**

Canine

**BREED**

Chihuahua Mix

**SEX**

Spayed Female

**AGE**

14 Years 9 Months

**WEIGHT**

16 Pounds

**INTERPRETED BY**

Laurent Locquet, DVM,  
 MRCVS, GPCert, (VC)  
 Diplomate, ECVIM-CA

**IMAGING PERFORMED BY**

Rebecca Hamilton

**HOSPITAL NAME**

Farview AC

**REFERRING VET**

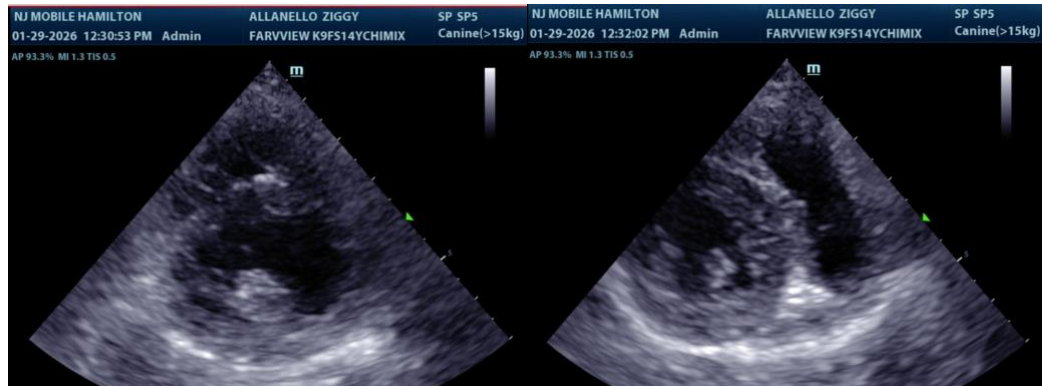
Dr. Mosaad

**INVOICE**

35619

**DATE**

1/29/26



**The information and recommendations provided are based on the images presented by the referring veterinarian/sonographer. No evaluation can be communicated regarding pathology that was not visible in the image/video clips provided.**

Thank you for this referral. If the clinical or image interpretation does not parallel your findings or if I can be of any further assistance please contact me.

**Laurent Locquet, DVM MRCVS GPCert (VC) Diplomate ECVIM-CA**

[info@SonoPath.com](mailto:info@SonoPath.com)