

PATIENT

Lexi Barrett

PRESENTING CLINICAL SIGNS

History: Large spindle cell tumor caudal L hind leg - looking for potential internal neoplasia before pursuing surgery.
Abnormal PE/Chem/CBC/UA Results: WNL as of 4/12/22. U/A: pH 9.0, USG 1.010.

SPECIES

Canine

ULTRASONOGRAPHIC EXAMINATION OF THE ABDOMEN

BREED

Mix

Urinary System

The urinary bladder is well distended with anechoic contents. The wall is smooth and regular. No abnormalities are noted with the trigone or proximal urethra, and there is no evidence of sediment, cystoliths, polyps or a mass.

SEX

Spayed Female

Kidneys

AGE

10 years

The **left** kidney measures 4.52 cm. The capsule is smooth. A very mild loss of the normal definition of the cortico-medullary junction is present. Very small mineralizations of the diverticulae and pelvis are present, without evidence of nephroliths or pyelectasia. Blood flow is within normal limits. The surrounding mesentery is not hyperechoic.

WEIGHT

43.5 lbs

The **right** kidney measures 5.25 cm. Findings are similar to the left kidney.

Aortic bifurcation/trifurcation

No abnormalities observed.

INTERPRETED BY

Lisa Carioto, DVM,
DVSc, Diplomate
ACVIM

Adrenal Glands

The **left** adrenal gland measures 0.51 cm at the cranial pole, 0.40 cm at the caudal pole. No abnormalities are noted with the gland's overall architecture, echogenicity or echotexture. The phrenico-abdominal vein and surrounding vasculature and mesentery are unremarkable.

IMAGING PERFORMED BY

Kelly Vazquez, CVT

The **right** adrenal gland measures 0.60 cm at the cranial pole, 0.56 cm at the caudal pole and 2.29 cm in length. No abnormalities are noted with the gland's overall architecture, echogenicity or echotexture. The phrenico-abdominal vein and surrounding vasculature and mesentery are unremarkable.

HOSPITAL NAME

Ramapo Valley AH

Spleen

The spleen is within normal limits in size, architecture, echotexture, and echogenicity. The capsule is smooth. An ill-defined hypoechoic nodule, with some anechoic areas, measuring 0.49 cm in diameter x 0.59 cm in length, is observed within the body. A second hypoechoic nodule is noted within the body. It is subcapsular and measures 0.54 cm in diameter x 0.75 cm in length. It does not disrupt the integrity of the capsule. No abnormalities are observed with its vasculature, i.e. congestion and thrombi are not identified.

REFERRING VET

Dr. Katara

INVOICE

30716

DATE

5/13/22



PATIENT	Liver
Lexi Barrett	There are no obvious signs of hepatomegaly and its borders are smooth and sharp, to mildly rounded. The liver's echotexture is homogeneous and it is within normal limits in echogenicity, i.e., it is hypoechoic to the spleen. An isoechoic, subcapsular, nodule in the left liver is observed. It measures 0.85 cm in diameter x 0.77 cm in length. It does not disrupt the integrity of the capsule. Note, the same nodule was remeasured in a different view; it is 1.06 cm in diameter x 1.55 cm in length. Very subtle hyperechoic areas are interspersed between the isoechoic regions. No abnormalities are observed with the hepatic vessels visualized.
SPECIES	
Canine	
BREED	
Mix	The gallbladder wall is within normal limits in thickness and echogenicity. A mild to moderate amount of echogenic material is present within the GB. The portions of the cystic and/or common bile ducts observed are not dilated or tortuous, i.e. there are no signs of an obstruction.
SEX	
Spayed Female	Gastrointestinal
AGE	A moderate amount of gas and fluid are present within the lumen of the stomach. The gastric wall is within normal limits in thickness and the wall layers are well defined. No obvious abnormalities are observed with its peristalsis.
10 years	Gas and fluid are present within the small intestines and duodenum. Wall thickness and definition of the wall layers of the small intestines, including the duodenum, are within normal limits. No abnormalities are observed with the ileocecal colic junction. Abnormally dilated loops of bowel are not observed.
WEIGHT	The colon is empty and no abnormalities are observed with wall thickness or mural detail.
43.5 lbs	There are no obvious signs of a mass, foreign body, infiltrative disease or an obstruction in the gastrointestinal tract.
INTERPRETED BY	
Lisa Carioto, DVM, DVSc, Diplomate ACVIM	Pancreas
IMAGING PERFORMED BY	No overt abnormalities are observed. There is no evidence of hyperechogenicity of the surrounding mesentery, i.e., signs of active pancreatitis are not present. Signs of active pancreatitis or neoplasia are not appreciated.
Kelly Vazquez , CVT	
HOSPITAL NAME	Other
Ramapo Valley AH	Lymph nodes
REFERRING VET	No abnormalities are observed
Dr. Katara	Abdominal effusion is not visualized.
INVOICE	
30716	Subcutaneous masses
DATE	Subcutaneous mass on ventrum , measuring 1.32 cm in diameter x approximately 2.92 cm in length. The mass is soft tissue in origin and well organized. It does not appear encapsulated at the caudal aspect, i.e. local invasion of the surrounding tissues is possible. It has a similar consistency to the spindle cell
5/13/22	



PATIENT

tumour on Lexi's left hip, i.e. its overall appearance is not suggestive of a lipoma. A fine needle aspirate is required to obtain a definitive diagnosis.

Lexi Barrett

SPECIES

Subcutaneous mass region of left hip, previously diagnosed as a spindle cell tumour. The mass measures 3.52 cm in diameter x 5.61 cm in length. It is hypoechoic to the surrounding muscle and well organized soft tissue. The mass is vascularized.

Canine

BREED

Heart

Mix

A brief video clip of the heart was submitted. Pericardial and pleural effusion are not identified. There is no evidence of a mass on evaluation of any chambers of the heart, including the right atrium or auricle. Note, a mass may be overlooked in the absence of pericardial effusion. No abnormalities are observed with the size of the chambers (measurements not performed) or contractility of the heart.

SEX

Spayed Female

ULTRASONOGRAPHIC FINDINGS

AGE

10 years

- **Subcutaneous mass on ventrum:** a fine needle aspirate is required to obtain a definitive diagnosis, as its appearance is *not consistent with a lipoma*. It is very similar in appearance to the spindle cell tumour on her left hip.

WEIGHT

43.5 lbs

- **Subcutaneous mass region of left hip**, cytologically diagnosed as a spindle cell tumour.
- **Liver:** The **hepatic nodule** is highly suggestive of nodular hyperplasia, which is a benign, age-related change, often observed in senior patients. There are no obvious signs of target lesions to suggest neoplasia.

INTERPRETED BY

Lisa Carioto, DVM,
DVSc, Diplomate
ACVIM

- **Spleen:** The appearance of the **splenic nodules** is suggestive of a benign process, such as nodular or lymphoid hyperplasia and extramedullary hematopoiesis. A possible hematoma is another differential diagnosis. There are no obvious signs of neoplasia.

IMAGING PERFORMED BY

Kelly Vazquez, CVT

- **Renal changes** are subtle and are suggestive of age-related degeneration.

HOSPITAL NAME

Ramapo Valley AH

INTERPRETATION OF THE FINDINGS & FURTHER RECOMMENDATIONS

A fine needle aspirate of the subcutaneous (SQ) mass located on Lexi's ventrum is strongly recommended to obtain a definitive diagnosis, as a spindle cell tumour is suspected based.

REFERRING VET

Dr. Katara

The hepatic and splenic nodules are more suggestive of benign processes. Although neoplasia is considered less likely as the cause of the nodules observed, fine needle aspirates are required to obtain definitive diagnoses.

INVOICE

30716

DATE

5/13/22



PATIENT

Lexi Barrett

SPECIES

Canine

BREED

Mix

SEX

Spayed Female

AGE

10 years

WEIGHT

43.5 lbs

INTERPRETED BY

Lisa Carioto, DVM,
DVSc, Diplomate
ACVIM

IMAGING PERFORMED BY

Kelly Vazquez, CVT

HOSPITAL NAME

Ramapo Valley AH

REFERRING VET

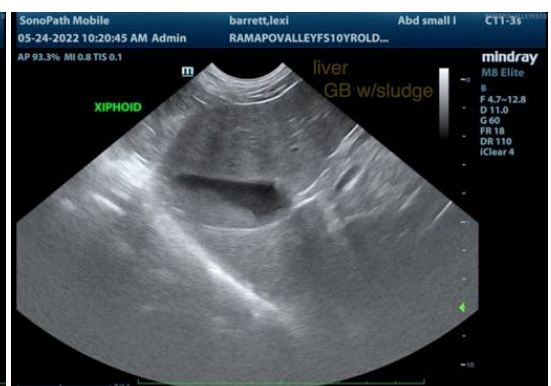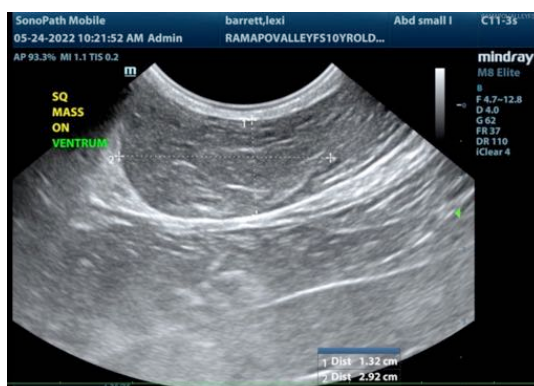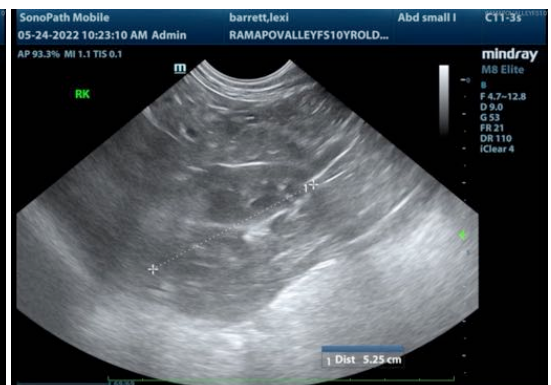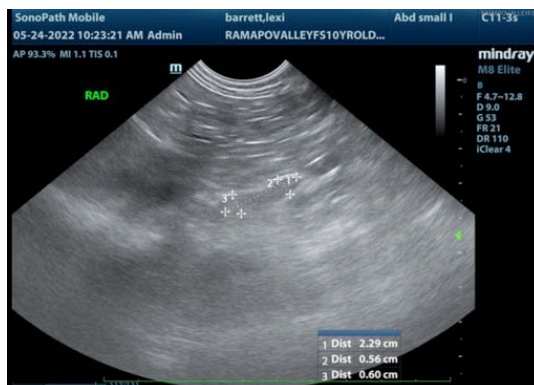
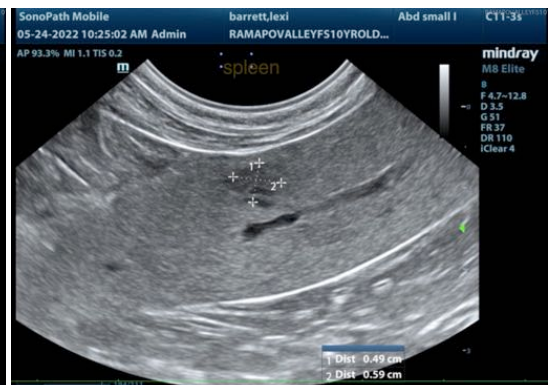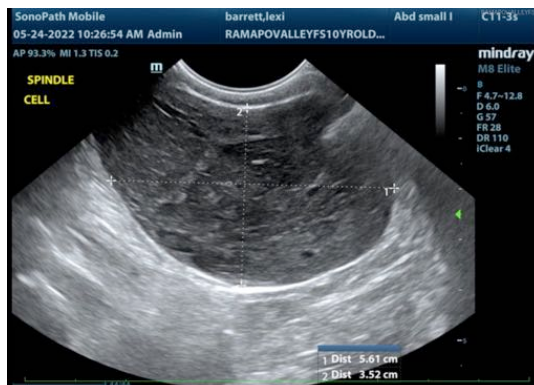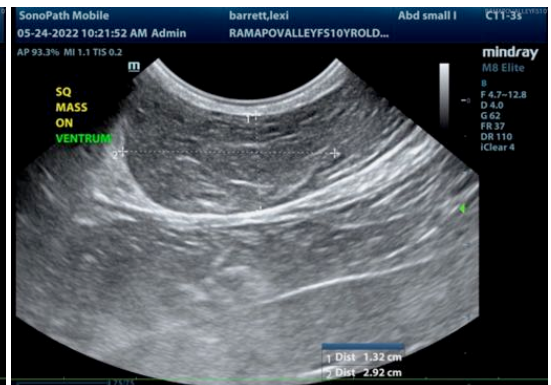
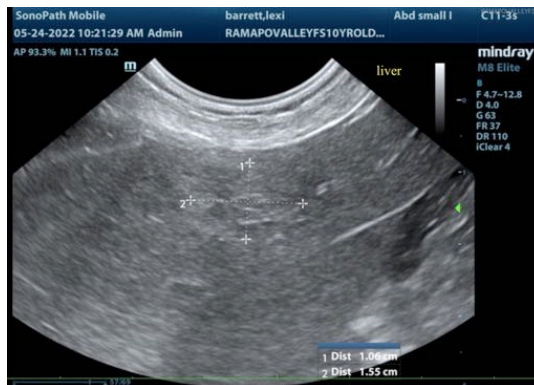Dr. Katara

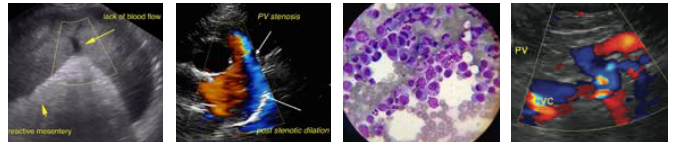
INVOICE

30716

DATE

5/13/22





PATIENT

Lexi Barrett

SPECIES

Canine

BREED

Mix

SEX

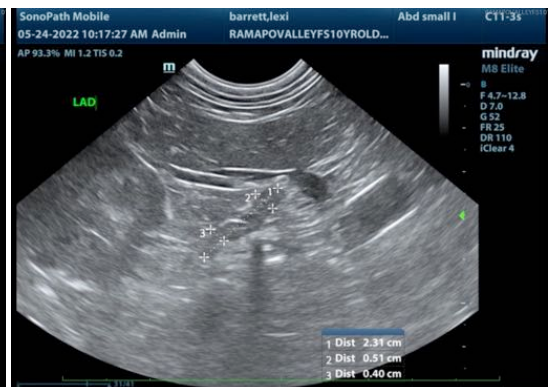
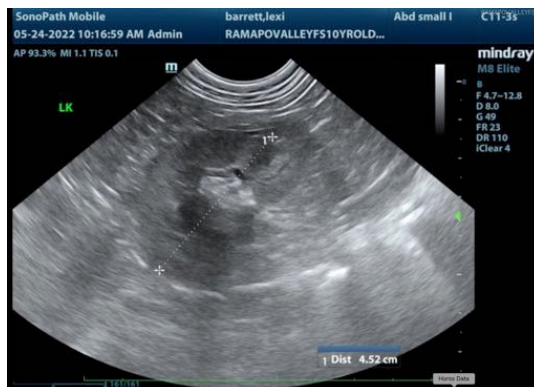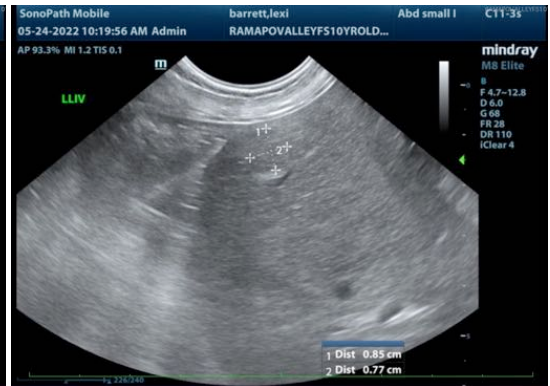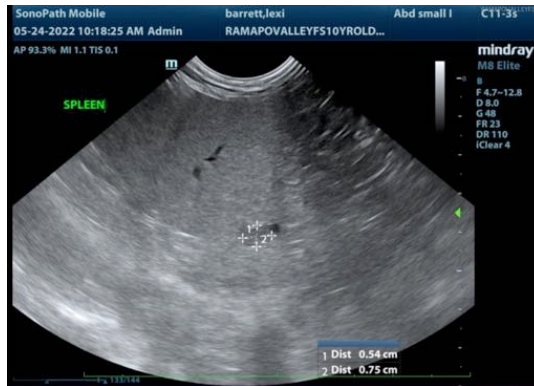
Spayed Female

AGE

10 years

WEIGHT

43.5 lbs



INTERPRETED BY

Lisa Carioto, DVM,
DVSc, Diplomate
ACVIM

IMAGING PERFORMED BY

Kelly Vazquez, CVT

HOSPITAL NAME

Ramapo Valley AH

REFERRING VET

Dr. Katara

INVOICE

30716

DATE

5/13/22

The information and recommendations provided are based on the images presented by the referring veterinarian/sonographer. No evaluation can be communicated regarding pathology that was not visible in the image/video clips provided.

Thank you for this referral. If the clinical or image interpretation does not parallel your findings or if I can be of any further assistance please contact me.

Lisa Carioto, DVM, DVSc, Diplomate ACVIM

Lisa.Carioto@sonopath.com