**DATE PRESENTING CLINICAL SIGNS**

8/3/22

Anorexia for two day duration. Decreased water consumption, urination, and defecation. O reports gradual weight loss and gradual appetite decrease, but P has always been a picky eater. 5-7% dehydration on physical exam. Discomfort on cranial abdominal palpation. Gr I-II/VI cardiac murmur. Tachycardic (216 bpm)

PATIENT

Boodha Goodrich

Current Medications: SQ fluids 8/2/22, Mirataz 8/2/22, Cerenia 8/2/22

Lab Results: CBC/Chem 17/T4: Globulins 5.3, Neut 10.3

SPECIES

Radiographs: Thoracic radiographs: NSF. Abdominal radiographs: Concern for possible mass effect in left dorsal mid abdomen

Feline

Date of Previous IntraPet Ultrasound: No previous.

Sedation: Buprenorphine was given IV for pain control.

BREED

Stat Report: Requested/Approved.

DLH

ULTRASONOGRAPHIC EXAMINATION OF THE ABDOMEN**SEX****Urinary System**

Spayed Female

The **urinary bladder** is adequately distended with anechoic contents. The wall is smooth and regular. No abnormalities are noted with the trigone or proximal urethra, and there is no evidence of sediment, cystoliths, polyps or a mass.

AGE

8/2/06

Kidneys**WEIGHT**

10 Pounds

The **left kidney** measures approximately 2.50 cm (3.80-4.40 cm). It is malformed, with an irregular, hyperechoic capsule. A complete loss of the normal definition of the cortico-medullary junction is present, with severe hydronephrosis. Obvious nephroliths are not observed. The pelvis measures 1.71 cm (longitudinal view). The urine within the dilated pelvis is echogenic. A severely dilated corrugated proximal hydroureter is visualized (1.1 cm). An echogenic, homogeneous, mass effect with irregular borders (0.71 cm x 0.62 cm) is noted within the dilated proximal ureter. The mass effect is not vascularized when evaluated with colour Doppler. Debris is a differential diagnosis for the mass effect. The ureter remains dilated (1.1 cm) for a distance of at least 6 cm and then suddenly tapers to 0.36 cm. The urine in the ureter is "flocculent", with free floating echogenic material. The walls of the ureters are hyperechoic and prominent. Marked acoustic enhancement of the mesentery surrounding both the kidney and ureter is visualized, in addition to very subtle anechoic regions amongst the acoustic enhancement, suggestive of edema. Blood flow of the renal cortex, the ureter and surrounding blood vessels is within normal limits.

INTERPRETED BY

Lisa Carioto, DVM,
DVSc, Diplomate
ACVIM

IMAGING PERFORMED BY

Stephanie Warga
RDCS, RVT

HOSPITAL NAME

Paradise AH

REFERRING VET

Dr. Pound

The **right kidney** measures 3.91 cm (3.80-4.40 cm). It is round, however, its capsule remains smooth. Although a severe loss of the normal definition of the cortico-medullary junction is present, anechoic lesions of various size are observed. Some of these lesions are consistent with dilated diverticulae, although the occasional cystic lesion cannot be excluded. Blood flow is maintained. There are no signs of nephroliths, yet pyelectasia is present 0.53 cm (longitudinal view). The urine within the pelvis is anechoic to mildly echogenic, although not as severe compared to the left kidney. Findings are similar to the left ureter (dilation, echogenicity of urine within ureter, corrugated wall of ureter, ureteritis based on severe hyperechogenicity of the mesentery surrounding the ureter. Marked hyperechogenicity of the mesentery surrounding the kidney is also observed.

Aortic bifurcation/trifurcation No abnormalities observed.

INVOICE

40088

Adrenal Glands

The **left adrenal gland** measures 0.56 cm. No abnormalities are noted with the gland's overall architecture, echogenicity or echotexture. The phrenico-abdominal vein and surrounding vasculature and mesentery are unremarkable.

The **right** adrenal gland is not visualized. The phrenico-abdominal vein and surrounding vasculature and mesentery are unremarkable.

Spleen

The spleen is within normal limits in size 8.5 mm (normal = 10 mm), echotexture, and echogenicity. The capsule is smooth. No abnormalities are observed with its vasculature, i.e. congestion and thrombi are not identified.

Liver

There are no obvious signs of hepatomegaly. The liver's borders are smooth, but mildly rounded. No abnormalities are noted with echotexture, however, it is diffusely hyperechoic, i.e., it is isoechoic to the falciform fat and the spleen. Focal lesions are not observed and no abnormalities are noted with the hepatic vessels.

The gallbladder (GB) wall is thickened at 2.0-2.5 mm and mildly to moderately hyperechoic. A circumferential hypoechoic "halo effect" is observed surrounding the gall bladder. This is suggestive of edema, inflammation or free fluid. The latter is considered less likely in Boodha's case. A small amount of echogenic material is present within the GB. The neck of the GB and proximal cystic duct are filled with sludge. A portion of the cystic is mildly tortuous but not dilated. There are no obvious signs of an obstruction.

Gastrointestinal

A large amount of gas is present within the lumen of the stomach. The gastric wall is within normal limits in thickness and the wall layers are well defined. No obvious abnormalities are observed with its peristalsis. Duodenum: wall thickness is within normal limits and the definition of the wall layers is preserved.

Jejunum: wall thickness is within normal limits and the definition of the wall layers is preserved. Fogging of the muscularis and mucosa are present, in addition to a more prominent muscularis than usual. A segment of jejunum shows a focally, but moderately thicker muscularis (0.4 cm) layer with fogging of the deeper layer. The near field muscularis layer is approximately half the thickness.

The ileo-cecal-colic junction does not show any abnormalities.

Transverse colon: a large amount of gas is present, which hinders the ability to visualize a approximately 2.5 cm of the right hydroureter.

The colonic wall is not thickened and mural detail is considered normal. Gas and formed stools are present in the colon.

Pancreas

The **left and right limbs** are mildly to moderately enlarged, moderately hypoechoic and have irregular borders. The surrounding mesentery is moderately to severely hyperechoic, particularly surrounding the left limb. Positive Murphy sign as per the sonographer, despite administration of buprenorphine. The latter may be a combination of pain associated with the pancreas and the kidneys.

Other

Lymph nodes No abnormalities are observed

Abdominal effusion A very scant amount of ascites is visualized surrounding both kidneys and ureters.

ULTRASONOGRAPHIC FINDINGS

- **Kidneys:** Bilateral hydronephrosis and hydroureter with severe acoustic enhancement and signs of echogenic urine and a possible mass effect within the left ureter. Bilateral pyelonephritis is suspected, however, pyonephrosis and neoplasia, (e.g. lymphoma) are other differential diagnoses.
- **Gastrointestinal (GI) tract:** Signs of inflammation of the jejunum are observed, however, neoplasia cannot be excluded as the cause of the one segment of the focally thickened muscularis layer.
- **Gallbladder:** Cholecystitis cannot be excluded, including a suppurative component.
- **Liver:** Hepatic lipidosis could explain the diffuse hyperechogenicity. Although no other abnormalities are observed, cholestasis and cholangitis/cholangiohepatitis cannot be excluded.
- **Pancreas:** Diffuse pancreatitis is suspected. Signs of neoplasia are not appreciated.
- High index of suspicion of “*triaditis*”
- **Adrenal glands:** Although all is within normal limits with regard to architecture of the left adrenal gland, it is at the high end of the normal reference range for a cat. This may be a result of hyperplasia secondary to stress/chronic illness, however, lymphoma can also cause enlarged adrenal glands in cats. The right adrenal was not visualized.

INTERPRETATION OF THE FINDINGS & FURTHER RECOMMENDATIONS

A urine culture and sensitivity may be performed, however, pyelocentesis may be necessary if the urine culture is negative.

Pyelocentesis to perform a culture and sensitivity and a fine needle aspirate of the kidneys could be performed to help exclude neoplasia.

Fine needle aspirates of the liver, pancreas, kidneys, pending coagulation profile results, are additional options to help exclude co-morbidities.

Antibiotics, enrofloxacin, should be started, pending the culture and cytology results.

Analgesia for visceral pain, such as buprenorphine (0.005-0.01 mg/kg sublingually every 8-12 hours) for a minimum of 7-10 days. Continue for 3-4 weeks if an improvement is noted; the dose and frequency may be weaned to the minimum effective dose during that time.

+/- gabapentin

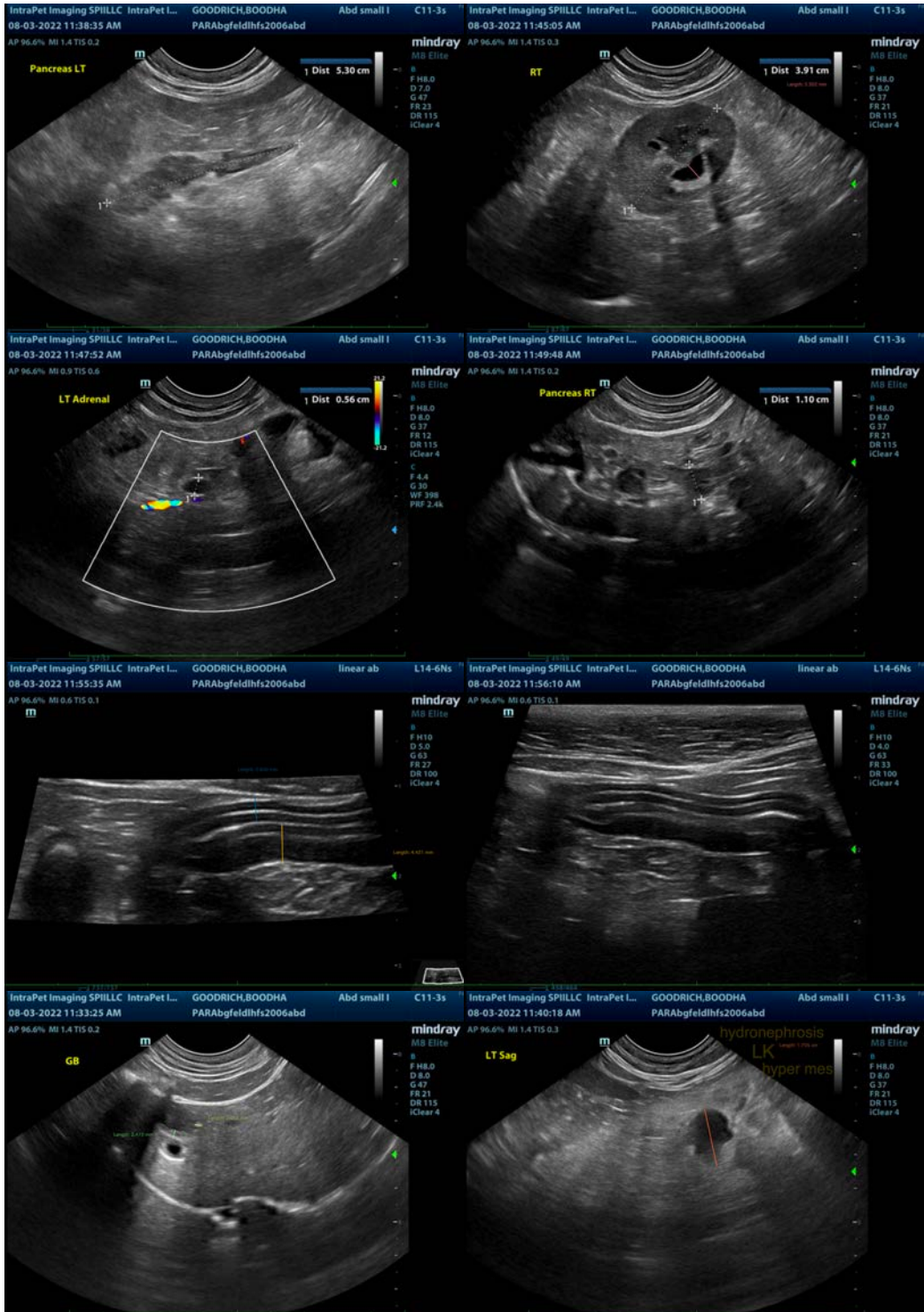
Supportive care (maropitant, mirtazapine, SQ fluids, etc.)

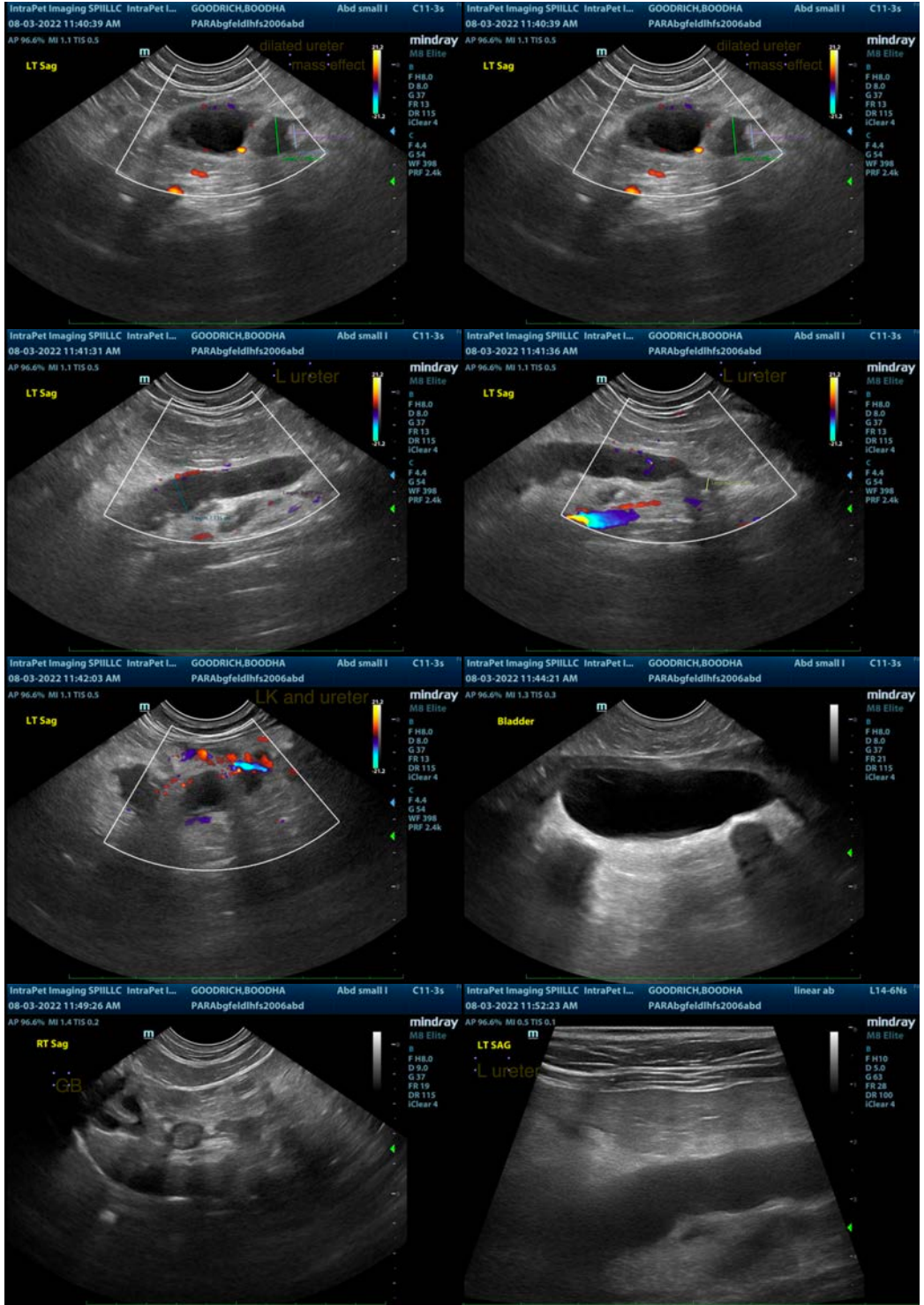
Referral to a board certified internist or specialist who deals with interventional therapies may be pursued, however, a biopsy of the abnormal appearing loop of jejunum is suggested to ensure Boodha is not suffering from concurrent neoplasia.

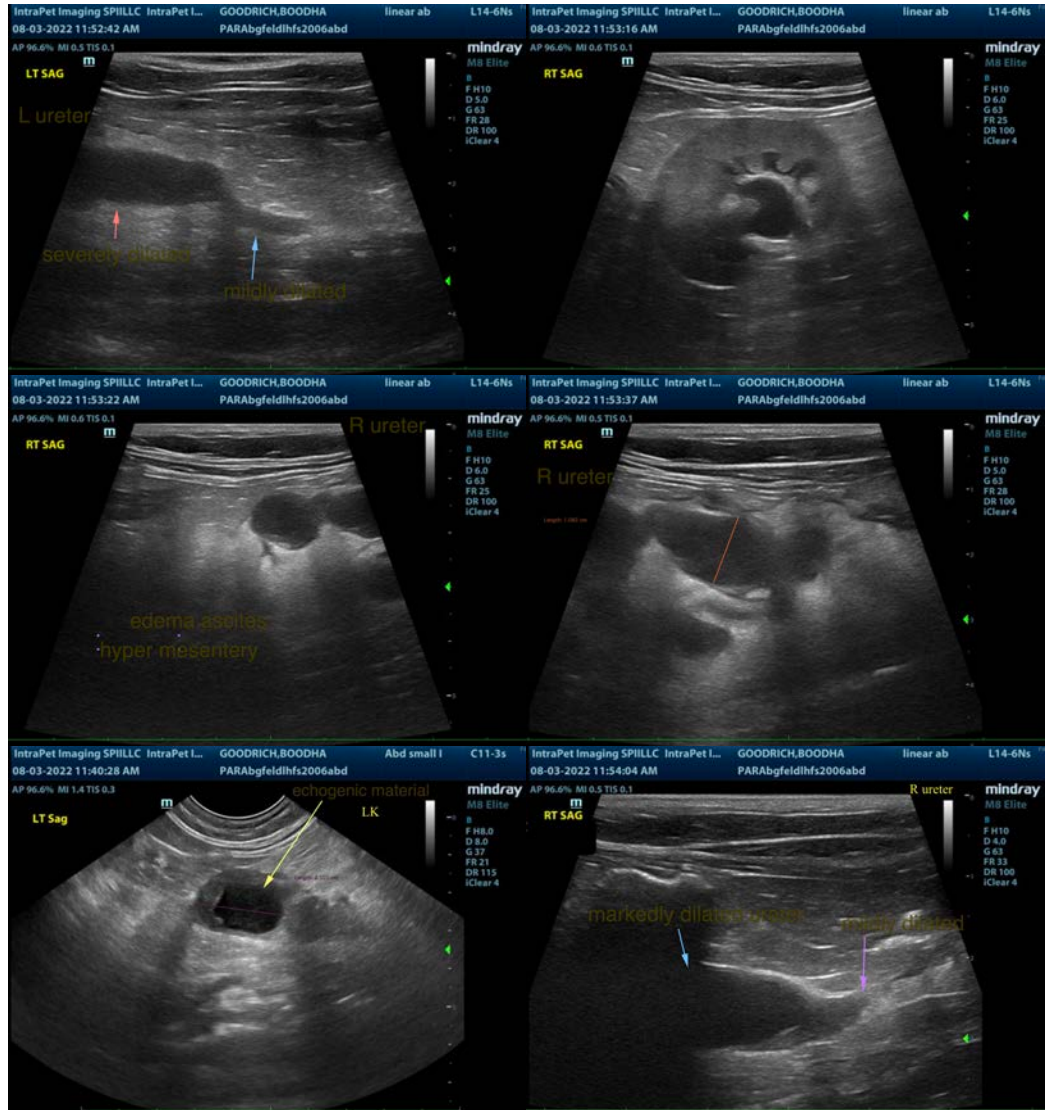
If signs of GERD present, 10-14 day trial with famotidine or omeprazole (0.7-1 mg/kg PO q12h)

Cholangitis/cholangiohepatitis and cholecystitis cannot be excluded, including a secondary ascending bacterial infection. Although indiscriminate use of antibiotics is not normally recommended, one could start treatment with a broad-spectrum antibiotic if an improvement is not observed with the above therapies; note, enrofloxacin may be sufficient.

A single dose of vitamin K (0.5 mg/kg SQ) due to cholestasis, but also suggested prior to performing fine needle aspirates.







The information and recommendations provided are based on the images presented by the referring veterinarian/sonographer. No evaluation can be communicated regarding pathology that was not visible in the image/video clips provided.

Thank you for this referral. If the clinical or image interpretation does not parallel your findings or if I can be of any further assistance please contact me.

Lisa Carioto, DVM, DVSc, Diplomate AVIM

Lisa.Carioto@sonopath.com