



PATIENT

Adicus Ramsey

SPECIES

Canine

BREED

Miniature Schnauzer

SEX

Neutered Male

AGE

12 Years 3 Months

WEIGHT

11 kg

INTERPRETED BY

Lisa Carioto, DVM,
DVSc, Diplomate
ACVIM

IMAGING PERFORMED BY

Donna Markland, DVM

HOSPITAL NAME

Island Mobile Paws

REFERRING VET

Maholo Vet Hospital

INVOICE

39374

DATE

7/9/22

PRESENTING CLINICAL SIGNS

Recently diagnosed with diabetes. Diabetes is uncontrolled. Adicus is losing weight. Also has high BP, OA, and KCS. Adicus wears a Freestyle Libre monitor which is changed regularly. The majority of his BG readings are high. He continues to have high fructosamine and glucosuria without ketonuria. Adicus' diet is high in protein. Drugs: Talmisartan, 15 mg PO SID Cartrophen (OA supplement in Canada) monthly Meloxicam, 11 kg dose SID Gabapentin, 100mg PO BID Cyclosporin ophthalmic, 1 drop OU BID Lantus insulin, 6 units SQ q 12 hrs
Abnormal PE/Chem/CBC/UA Results: Results from 7/1/22: UA usg=1.028 Glucose 3+ WBC 0-2/hpf
CBC: RBC=4.9 (5.4-8.7) HCT=33% (38-57) HGB=115 (134-207) Platelets=625 (143-448) Chem: Glucose=24.6 (3.5-6.3) Urea=23.6 (3.2-11.0) ALT= 613 (18-121) AST=154 (16-55) ALP=1786 (5-160) Cholesterol=14.8 (3.4-8.9) Fructosamine=504 (177-314) T4=normal (27.5) Electrolytes: Cl=106 (108-119) Potassium=5.8 (4.0-5.4) Na=142 (142-152) Na:K ratio=24

ULTRASONOGRAPHIC EXAMINATION OF THE ABDOMEN

Urinary System

The **urinary bladder** is adequately distended with anechoic contents. The wall is smooth and regular. No abnormalities are noted with the trigone or proximal urethra, and there is no evidence of sediment, cystoliths, polyps or a mass.

The **prostate** is homogenous and measures 1.12 cm; within normal limits for a neutered male.

Kidneys

The **left kidney** measures 5.99 cm. The capsule is smooth. The cortex appears mildly thickened compared to normal and a mild loss of the normal definition of the cortico-medullary junction is present. Mild mineralization of the diverticulae and pelvis are present, without evidence of nephroliths or pyelectasia. The perirenal mesentery is very mildly hyperechoic.

The **right kidney** measures 6.10 cm. The capsule is smooth. The cortex is isoechoic to mildly hyperechoic to the liver and appears thickened compared to normal. A mild loss of the normal definition of the cortico-medullary junction is present. Mild mineralization of the diverticulae and pelvis are present, without evidence of nephroliths or pyelectasia. Blood flows within normal limits. The surrounding mesentery is mildly hyperechoic.

Aortic bifurcation/trifurcation No abnormalities observed.

Adrenal Glands

The **left adrenal gland** measures 0.53 cm at the cranial pole, 0.59 cm at the caudal pole and 2.00 cm in length. No abnormalities are noted with the gland's overall architecture, echogenicity or echotexture. The phrenico-abdominal vein and surrounding vasculature and mesentery are unremarkable.

The **right adrenal gland** measures 0.55 cm at the cranial pole, 0.48 cm at the caudal pole and approximately 2.18 cm in length. No abnormalities are noted with the gland's overall architecture, echogenicity or echotexture. The phrenico-abdominal vein and surrounding vasculature and mesentery are unremarkable.

Spleen

The portions of the spleen evaluated are within normal limits in size, architecture, echotexture, and echogenicity. The capsule is smooth. No abnormalities are observed with its vasculature, i.e. congestion and thrombi are not identified.



PATIENT

Liver

Adicus Ramsey

Hepatomegaly is suspected, however, this is better characterized at the time of the ultrasound or radiographically. The liver's borders are smooth, and vary between sharp to mildly rounded. It is mildly to moderately hyperechoic, however, it remains hypoechoic to the spleen. A normal echotexture, consisting of a finely granular or coarse pattern, is observed. A hyperechoic nodule, measuring 1.0 cm in diameter x 0.93 cm in length is noted. No other focal lesions are visualized. No obvious abnormalities are noted with the hepatic vessels.

SPECIES

Canine

BREED

Miniature Schnauzer

The gallbladder (GB) wall is within normal limits in thickness and echogenicity. A small amount of free floating, gravity-dependent and inspissated echogenic material (sludge) is present within the GB, in addition to markedly hyperechoic, nodular sediment with an acoustic shadow. The latter is consistent with a cholelith (5.3 mm x 5.3 mm) or 6.5 mm in another view. Strings of mucus are also noted. The portions of the cystic and/or common bile ducts observed are not dilated or tortuous, i.e. there are no signs of an obstruction.

SEX

Neutered Male

Gastrointestinal

AGE

12 Years 3 Months

Food fluid and gas are present within the lumen of the stomach. The gastric wall is within normal limits in thickness and the wall layers are well defined. No obvious abnormalities are observed with its peristalsis.

WEIGHT

11 kg

The small intestinal wall thickness, including the duodenum, is within normal limits and the definition of the wall layers is preserved. However, mild fogging and stippling of the mucosa of the duodenum and jejunum are noted. Abnormally dilated loops of bowel are not observed.

The colonic wall is not thickened and mural detail is considered normal. Formed feces are present within the colon.

INTERPRETED BY

Pancreas

Lisa Carioto, DVM,
DVSc, Diplomate
ACVIM

The pancreas has a mildly coarse echotexture, and is mildly heterogeneous. It is very mildly hypoechoic to isoechoic to the surrounding omentum. It consists of hypoechoic nodules of variable size and pinpoint to punctate hyperechoic foci scattered throughout the parenchyma. The changes are suggestive of nodular hyperplasia and fibrosis, respectively. Fibrosis may be an age-related change, secondary to previous episodes of pancreatitis, mineralization and amyloid deposition. Signs of active pancreatitis or neoplasia are not appreciated.

IMAGING PERFORMED BY

Donna Markland, DVM

Other

HOSPITAL NAME

Island Mobile Paws

Lymph nodes No abnormalities are observed

Abdominal effusion is not visualized.

REFERRING VET

Maholo Vet Hospital

ULTRASONOGRAPHIC FINDINGS

- **Liver:** A *vacuolar hepatopathy* is suspected which is consistent with diabetes mellitus, stress or chronic illness. Cholestasis is likely present. A subtle reactive hepatopathy cannot be excluded based on the mild granular echotexture. Obvious signs of hepatitis, cholangitis/cholangiohepatitis are not appreciated, but cannot be excluded, including an ascending bacterial infection from the gastrointestinal tract (see later). The *hyperechoic nodule* is most likely due to fibrosis and/or regeneration including mineralization and fat accumulation. There is no evidence of cirrhosis. Overt signs of neoplasia are not observed.

INVOICE

39374

DATE

7/9/22



PATIENT

Adicus Ramsey

SPECIES

Canine

BREED

Miniature Schnauzer

SEX

Neutered Male

AGE

12 Years 3 Months

WEIGHT

11 kg

INTERPRETED BY

Lisa Carioto, DVM,
DVSc, Diplomate
ACVIM

**IMAGING
PERFORMED BY**

Donna Markland, DVM

HOSPITAL NAME

Island Mobile Paws

REFERRING VET

Maholo Vet Hospital

INVOICE

39374

DATE

7/9/22

- **Gallbladder:** Presence of *gallbladder sludge*, a *cholelith* and *strings of mucus*. There is no evidence of a mucocoele or of an obstruction. Although sonographic signs of cholecystitis are not observed, an infection due to ascending bacteria from the intestinal tract is possible. The presence of sludge is usually clinically insignificant, however, some dogs can develop signs of gastroesophageal reflux disease (GERD). Therefore, obtaining a history regarding signs of GERD from the client is suggested.
- **Gastrointestinal (GI) tract:** Serious abnormalities are not observed, however, there are changes suggestive of inflammation in the duodenum and jejunum. The ALT enzyme activity may increase with GI disease.
- **Pancreas:** The pancreatic changes are suggestive of age-related changes. Fibrosis may occur as an age-related change, secondary to previous episodes of pancreatitis, mineralization and amyloid deposition. Overt signs of active pancreatitis or neoplasia are not appreciated.
- **Kidneys:** Mild age related changes are observed. Subtle abnormalities suggestive of glomerulonephritis are noted, however, pyelonephritis cannot be excluded as sonographic signs can overlap.

INTERPRETATION OF THE FINDINGS & FURTHER RECOMMENDATIONS

An obvious cause for the elevated ALT enzyme activity is not determined from today's abdominal ultrasound, however, overt signs of neoplasia are not appreciated.

A hepatic biopsy would be required to obtain additional information for the elevated ALT. However, due to the mild inflammatory changes observed with the GI tract, and the biliary changes, less invasive procedures are suggested.

Fasting triglycerides (an 8 to 12 hours fast, if possible, for example, just prior to insulin injection) as a change in diet may be required.

Urine culture, even if bacteria not evident on urinalysis (increased risk of subclinical bacteriuria and pyelonephritis) due to diabetes mellitus.

Urine protein: creatinine ratio if the urine culture is negative. However, to obtain an average of the UPC ratio, 3 urine samples obtained from 3 consecutive days are suggested (see later).

Obtaining a history regarding signs of GERD from the client is suggested. Treatment with an anti-acid or proton pump inhibitor may be considered depending on the history (famotidine or omeprazole (0.7-1 mg/kg PO q12h)).

+/- ursodeoxycholic acid (Ursodiol) in the future (not recommended for the moment until diabetes is better regulated).

A TLI, serum cobalamin, and folate to assess for underlying maldigestion and malabsorption disease.

Psyllium may be added to her diet to help regulate his diabetes (avoid formulations with sugar AND ensure they are not sweetened with xylitol).



PATIENT

Adicus Ramsey

Dose of glargine is still quite low at 0.5 U/kg SQ BID. Data from the Freestyle LIBRE may be downloaded and reviewed to ascertain how to adjust the insulin dose.

SPECIES

Canine

If still no improvement in the ALT enzyme activity: Secondary bacterial infections of the liver and bile cannot be excluded. Although indiscriminate use of antibiotics is not recommended, consider broad-spectrum antibiotic with reassessment of liver enzymes, including GGT, in a few weeks, while *still receiving* the antibiotics.

If an improvement is observed, continue antibiotic for an additional two weeks.

BREED

Miniature Schnauzer

It is far too soon to consider changing insulins, but two to consider if unable to regulate Adicus' diabetes include, detemir or long acting glargine (Tujeo).

SEX

Neutered Male

Adicus is a complicated patient, and although some treatment recommendations have been described, an internal medicine consult is suggested in order to evaluate his blood glucose data and describe all possible options in further detail.

AGE

12 Years 3 Months

To perform a UPC, ideally, the first morning urine sample should be collected for *three consecutive mornings*. The samples should be kept in the refrigerator until the *third day*, at which time the samples are brought to the clinic. All three samples should be combined as one and submitted as one sample. This yields an average UPC. If possible, please clean Adicus' prepuce with chlorhexidine (0.05%) or a moistened cotton ball with water and mild pet shampoo prior to collecting the urine to help reduce contamination.

WEIGHT

11 kg

INTERPRETED BY

Lisa Carioto, DVM,
DVSc, Diplomate
ACVIM

IMAGING PERFORMED BY

Donna Markland, DVM

HOSPITAL NAME

Island Mobile Paws

REFERRING VET

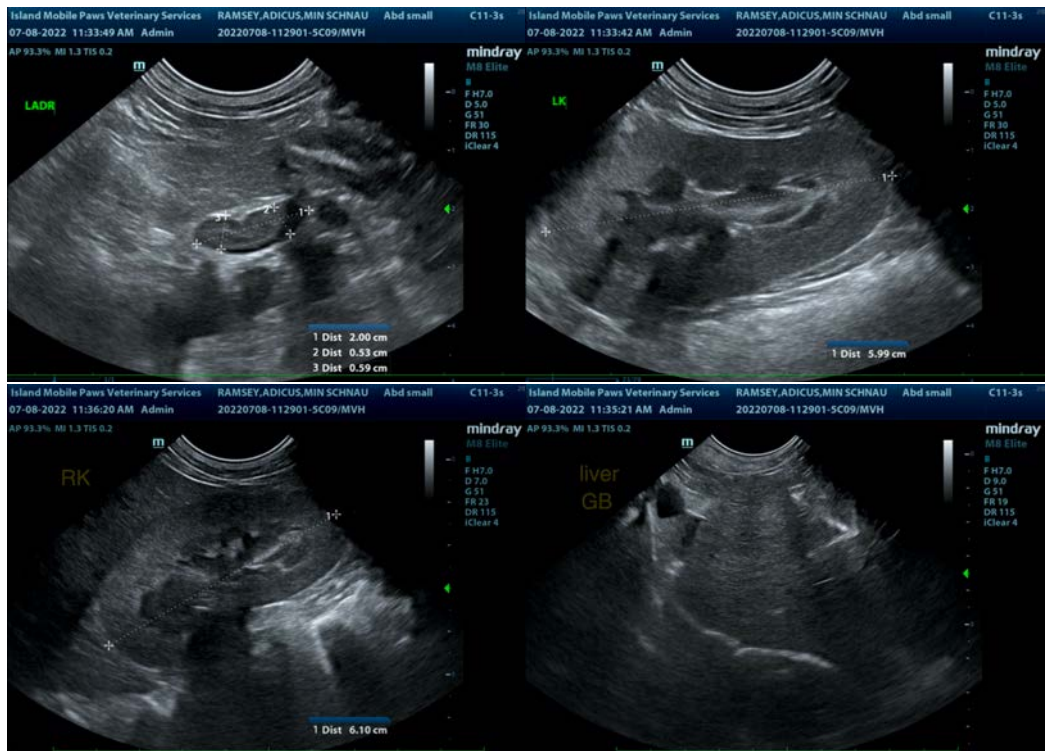
Maholo Vet Hospital

INVOICE

39374

DATE

7/9/22





PATIENT

Adicus Ramsey

SPECIES

Canine

BREED

Miniature Schnauzer

SEX

Neutered Male

AGE

12 Years 3 Months

WEIGHT

11 kg

INTERPRETED BY

Lisa Carioto, DVM,
DVSc, Diplomate
ACVIM

**IMAGING
PERFORMED BY**

Donna Markland, DVM

HOSPITAL NAME

Island Mobile Paws

REFERRING VET

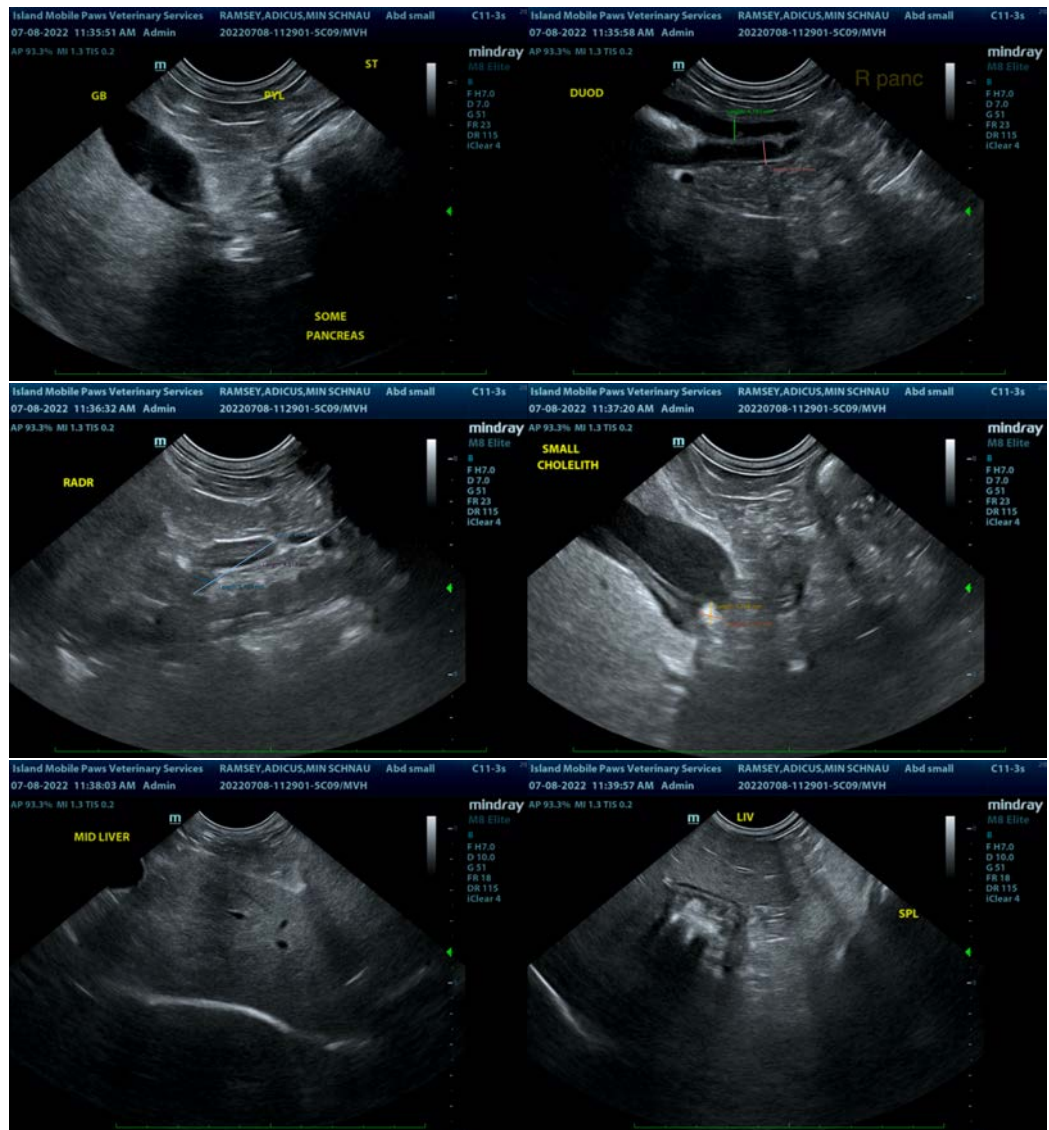
Maholo Vet Hospital

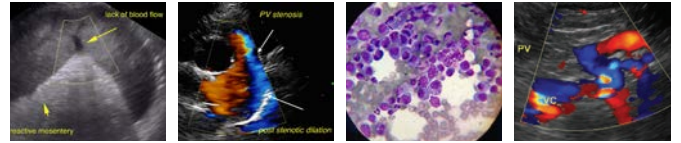
INVOICE

39374

DATE

7/9/22





PATIENT

Adicus Ramsey

SPECIES

Canine

BREED

Miniature Schnauzer

SEX

Neutered Male

AGE

12 Years 3 Months

WEIGHT

11 kg

INTERPRETED BY

Lisa Carioto, DVM,
DVSc, Diplomate
ACVIM

**IMAGING
PERFORMED BY**

Donna Markland, DVM

HOSPITAL NAME

Island Mobile Paws

REFERRING VET

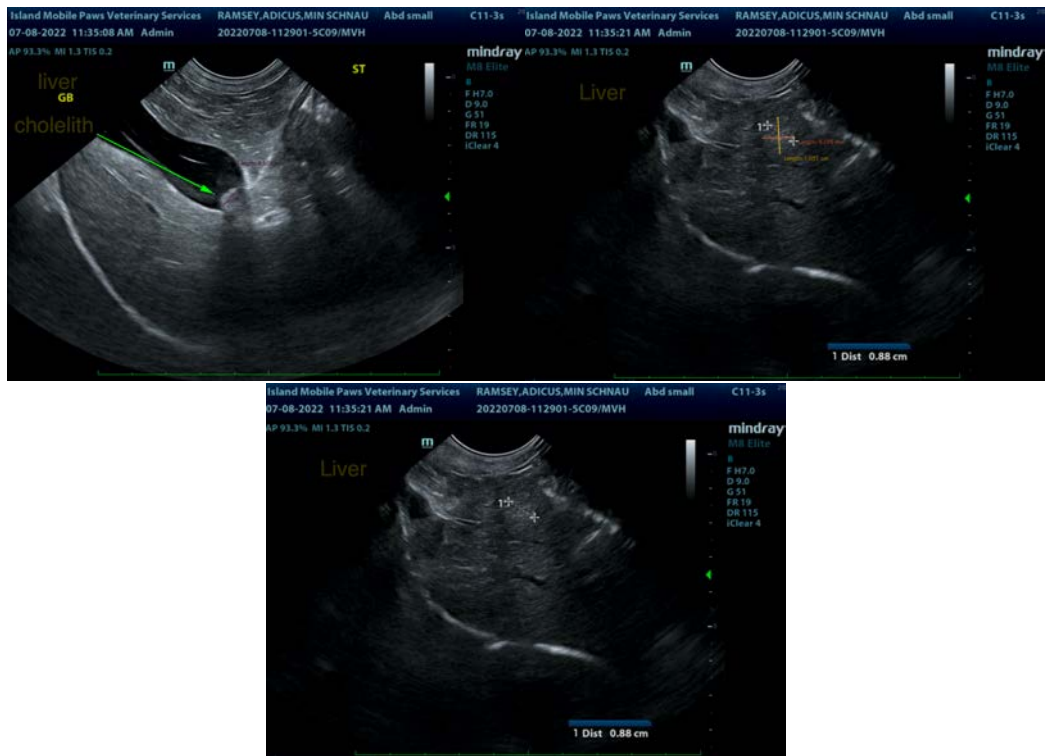
Maholo Vet Hospital

INVOICE

39374

DATE

7/9/22



The information and recommendations provided are based on the images presented by the referring veterinarian/sonographer. No evaluation can be communicated regarding pathology that was not visible in the image/video clips provided.

Thank you for this referral. If the clinical or image interpretation does not parallel your findings or if I can be of any further assistance please contact me.

Lisa Carioto, DVM, DVSc, Diplomate ACVIM

Lisa.Carioto@sonopath.com