



**PATIENT**

Lacei Daly

**SPECIES**

Canine

**BREED**

Beagle

**SEX**

Spayed Female

**AGE**

9 Years

**WEIGHT**

34 Pounds

**INTERPRETED BY**

Lisa Carioto, DVM,  
DVSc, Diplomate  
ACVIM

**IMAGING PERFORMED BY**

Dr. Scott

**HOSPITAL NAME**

Ho-Ho-Kus VH

**REFERRING VET**

Dr. Scott

**INVOICE**

39337

**DATE**

7/8/22

**PRESENTING CLINICAL SIGNS**

Came in for increased urination and panting, eating fine, no v/d when in for exam and diagnostics had an upper airway crisis due to collapsing trachea hx of pancreatitis  
Abnormal PE/Chem/CBC/UA Results: done two days ago USG 1.018, UPC 1.7 cbc/chem/spec pending

**ULTRASONOGRAPHIC EXAMINATION OF THE ABDOMEN**

**Urinary System**

The **urinary bladder** is well distended with anechoic contents. The wall is smooth and regular. No abnormalities are noted with the trigone or proximal urethra, and there is no evidence of sediment, cystoliths, polyyps or a mass.

**Kidneys**

The **left** kidney appears within normal limits in size. A precise measurement is not possible, cranial pole located out of area of interest. The capsule is smooth. A mild loss of the normal definition of the cortico-medullary junction is present. Mineralizations of the diverticulae and pelvis are present, without evidence of nephroliths or pyelectasia. An accumulation of intrapelvic fat is noted. The surrounding mesentery is not hyperechoic.

The **right** kidney measures approximately 5.69 cm. The capsule is smooth. A mild loss of the normal definition of the cortico-medullary junction is present. Mineralizations of the diverticulae and pelvis are present, without evidence of nephroliths or pyelectasia. An accumulation of intrapelvic fat is noted. The surrounding mesentery is not hyperechoic.

**Aortic bifurcation/trifurcation**

No abnormalities observed.

**Adrenal Glands**

The **left** adrenal gland measures 0.48 cm at the cranial pole, 0.58 cm at the caudal pole. No abnormalities are noted with the gland's overall architecture, echogenicity or echotexture. The phrenico-abdominal vein and surrounding vasculature and mesentery are unremarkable.

The **right** adrenal gland measures 0.34 cm at the cranial pole, 0.38 cm at the caudal pole and XXX cm in length. No abnormalities are noted with the gland's overall architecture, echogenicity or echotexture. The phrenico-abdominal vein and surrounding vasculature and mesentery are unremarkable.

**Spleen**

The spleen is within normal limits in size, architecture, echotexture, and echogenicity. The capsule is smooth. Occasional perivascular cuffing is noted, which is consistent with myelolipomas; these are not considered clinically significant. No abnormalities are observed with its vasculature, i.e. congestion and thrombi are not identified.

**Liver**

There are no obvious signs of hepatomegaly and its borders are smooth and sharp. The liver's echotexture is homogeneous, with a diffuse, very mildly coarse or granular echotexture. Focal lesions are not visualized and no abnormalities are observed with the hepatic vessels.



**PATIENT**

Lacei Daly

The **gallbladder** (GB) wall is within normal limits in thickness and echogenicity. A trivial amount of echogenic material is present within the GB. The cystic and common bile ducts are not visualized, however, there are no obvious signs of an obstruction.

**SPECIES**

Canine

**Gastrointestinal**

Ingesta and a large amount of gas are present within the lumen of the stomach. The gastric wall is within normal limits in thickness and the wall layers are well defined. The mucosa is mildly more prominent than usual. Panting artefact is present; it is, therefore, difficult to assess peristalsis.

**BREED**

Beagle

The small intestinal wall thickness, including the duodenum, is within normal limits and the definition of the wall layers is preserved. A small amount of ingesta is present within the small intestines, however, no overt abnormalities are noted. Abnormally dilated loops of bowel are not observed.

**SEX**

Spayed Female

The colonic wall is not thickened and mural detail is considered normal.

**Pancreas**

The pancreas has a coarse echotexture. It consists of small, hypoechoic nodules and pinpoint to punctate hyperechoic foci scattered throughout the parenchyma. These changes are suggestive of nodular hyperplasia and fibrosis, respectively. Fibrosis may be an age-related change, secondary to previous episodes of pancreatitis, mineralization and amyloid deposition. Signs of active pancreatitis or neoplasia are not appreciated.

**AGE**

9 Years

**WEIGHT**

34 Pounds

**Other**

**Lymph nodes**

No abnormalities are observed

**INTERPRETED BY**

Lisa Carioto, DVM,  
DVSc, Diplomate  
ACVIM

**Abdominal effusion** is not visualized.

**ULTRASONOGRAPHIC FINDINGS**

- **Kidneys:** Age-related degenerative changes are noted. Pyelonephritis cannot be excluded despite the absence of classical sonographic signs.
- **Gallbladder:** Gallbladder sludge is often clinically insignificant, however, gastroesophageal reflux disease (GERD), can occur in some patients. Obtaining a history regarding signs of GERD from the client is suggested. Treatment with an anti-acid, proton pump inhibitor or ursodeoxycholic acid may be required.
- **Pancreas:** Age-related changes are observed in addition to signs of fibrosis. The latter may be due to age-related change, secondary to previous episodes of pancreatitis, mineralization and amyloid deposition. Signs of active pancreatitis or neoplasia are not appreciated.
- **Gastrointestinal tract:** The clinical significance of the mildly prominent mucosa of the stomach is not known. Subclinical inflammation may be present.

**IMAGING PERFORMED BY**

Dr. Scott

**HOSPITAL NAME**

Ho-Ho-Kus VH

**REFERRING VET**

Dr. Scott

**INTERPRETATION OF THE FINDINGS & FURTHER RECOMMENDATIONS**

**INVOICE**

39337

There are no obvious signs of pituitary-dependent hyperadrenocorticism, however atypical Cushing's disease remains possible, or Lacei may be suffering from HAC without enlarged adrenal glands. Other differential diagnoses include a urinary tract infection or pyelonephritis as the cause of polyuria and polydipsia. The excessive panting could be due to pain associated with osteoarthritis. Hypothyroidism can also cause excessive panting, however, it should not cause pu/pd.

**DATE**

7/8/22



**PATIENT** The following are suggested/recommended

Lacei Daly A urinalysis and urine culture and sensitivity

**SPECIES** A urine protein: creatinine ratio, if the urine culture is negative (particularly if the urine specific gravity is less than 1.015)

Canine If possible, an arterial blood pressure

**BREED** Gabapentin every 8-12 hours as a diagnostic test for possible discomfort, +/- an opioid (e.g. methadone)

Beagle Obtaining a history regarding signs of GERD from the client is suggested. Treatment with an anti-acid or proton pump inhibitor may be required; 10-14 day trial with famotidine or omeprazole (0.7-1 mg/kg PO q12h)

**SEX** A low dose dexamethasone suppression test or an adrenal panel performed at the University of Tennessee Diagnostic Laboratory may be considered depending on the above laboratory results and responses to analgesics.

**AGE** Consider laryngeal paresis in addition to tracheal collapse, i.e., fT4 (EQD) and TSH may be considered to rule out hypothyroidism.

**WEIGHT** Depending on the severity of the tracheal collapse, and whether HAC is present, inhalant therapy with fluticasone 250 ug/actuation may be tried for a few weeks to decrease inflammation, +/- hydrocodone, if coughing.

**INTERPRETED BY**

Lisa Carioto, DVM,  
DVSc, Diplomate  
ACVIM

**IMAGING PERFORMED BY**

Dr. Scott

**HOSPITAL NAME**

Ho-Ho-Kus VH

**REFERRING VET**

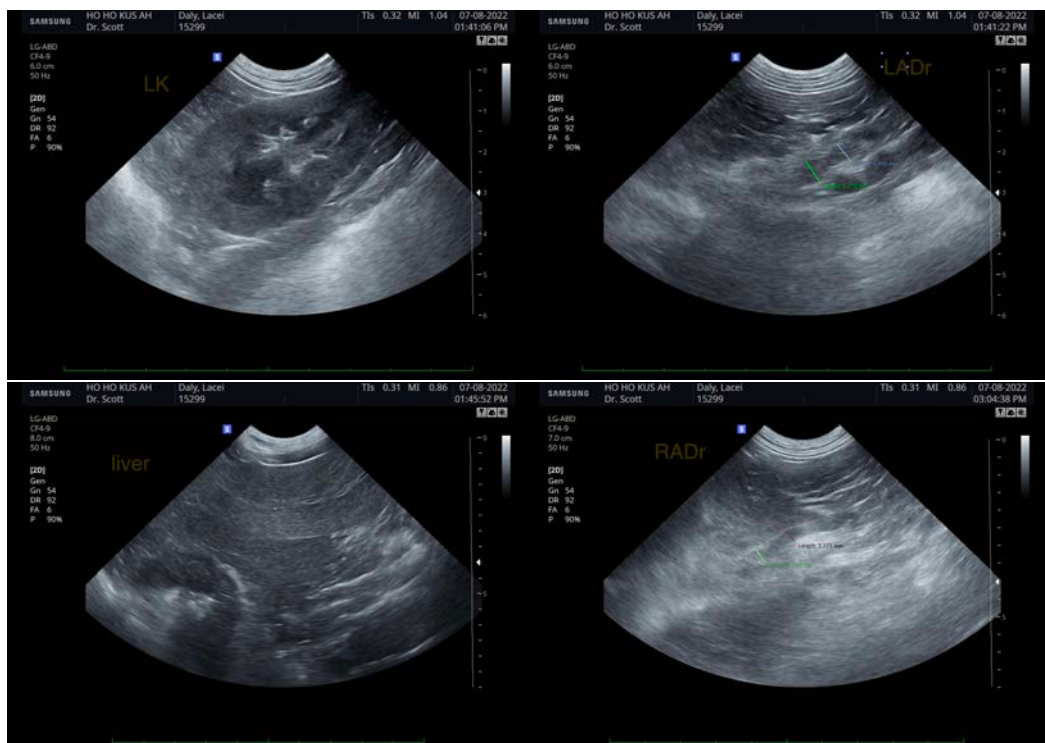
Dr. Scott

**INVOICE**

39337

**DATE**

7/8/22





**PATIENT**

Lacei Daly

**SPECIES**

Canine

**BREED**

Beagle

**SEX**

Spayed Female

**AGE**

9 Years

**WEIGHT**

34 Pounds

**INTERPRETED BY**

Lisa Carioto, DVM,  
DVSc, Diplomate  
ACVIM

**IMAGING  
PERFORMED BY**

Dr. Scott

**HOSPITAL NAME**

Ho-Ho-Kus VH

**REFERRING VET**

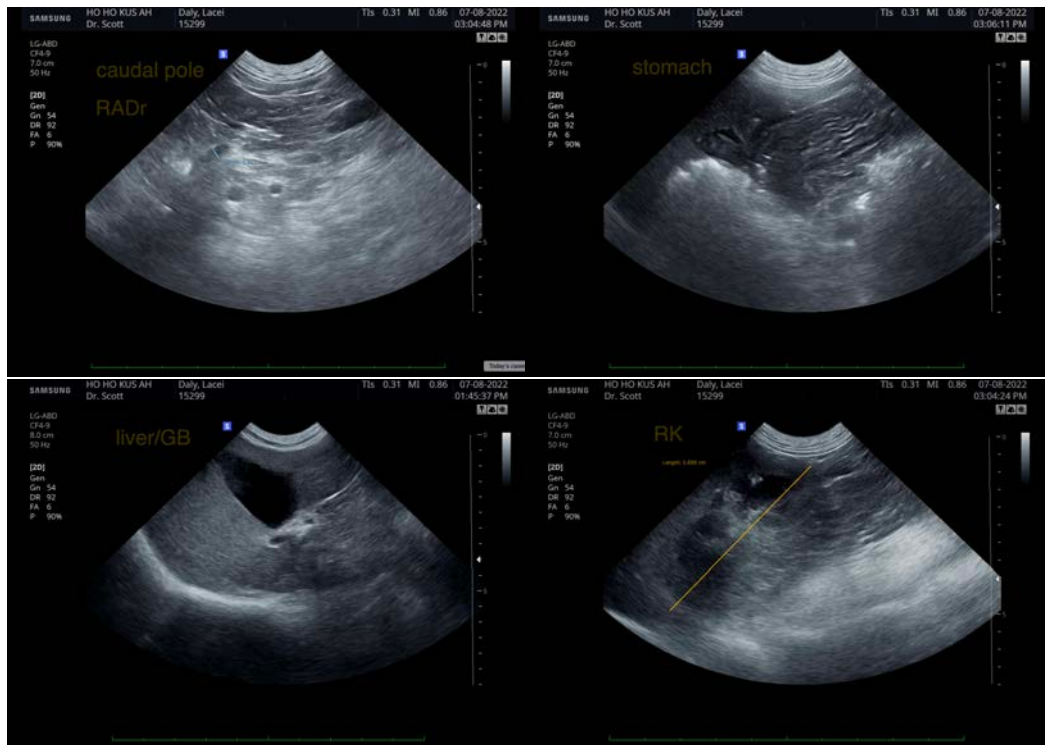
Dr. Scott

**INVOICE**

39337

**DATE**

7/8/22



The information and recommendations provided are based on the images presented by the referring veterinarian/sonographer. No evaluation can be communicated regarding pathology that was not visible in the image/video clips provided.

Thank you for this referral. If the clinical or image interpretation does not parallel your findings or if I can be of any further assistance please contact me.

**Lisa Carioto, DVM, DVSc, Diplomate ACVIM**

[Lisa.Carioto@sonopath.com](mailto:Lisa.Carioto@sonopath.com)