**PATIENT**Hamilton Sprague
273881**SPECIES**

Canine

BREED

Poodle X

SEX

Neutered Male

AGE

1 Year 5 Months

WEIGHT

3.7 kg

INTERPRETED BYBeth Johnson, DVM
DACVIM**IMAGING PERFORMED BY**

Tom McNeill

HOSPITAL NAME

SVS Imaging CT

REFERRING VET

WVRC - Dr. Sevde

INVOICE

39350

DATE

7/8/22

PRESENTING CLINICAL SIGNS

History of chronic vomiting and intermittent soft stools to diarrhea. Owner reports that Hamilton has vomited frequently since a puppy. He has not have bloodwork or X-rays for this. It seemed to improve with famotidine, a meal before bed, and another medication (maropitant?) but did not resolve. Owner reports he actively vomits and generally brings up bile. This can occur at any time of the day. He was staying with owners daughter and family leading up to the holiday weekend. He started to have diarrhea approximately 2 weeks ago. On July 4th and vomited multiple times in an hour and was shaking. He was evaluated at WVRC Grafton and treated with SC fluids and maropitant. Owner reports he did not improve and he was evaluated at his primary veterinarian and treated with SC fluids. He was started on famotidine and maropitant (owner unsure when). He has not had much of an appetite since Monday. Today he ate a few bites of turkey. His diarrhea has been liquid which is much worse than usual for him. He eats a raw diet (was already on this when obtained by owner) Owner reports not known to eat toys/non-food items Owner reports frequent ear infections

Abnormal PE/Chem/CBC/UA Results: CBC: Hct 44%, WBC 12.49 K/uL, Plt 349 K/uL Hemolysis noted in green top tube Chem: BUN 16.9, Cre 0.7, GLu 199 (H consistent with stress), Chol 96 (L normal 120), ALb 3.1, Glob 2.7, ALT 33, ALKP 43, GGT 25 (H, suspect artifact given hemolysis), tBili 1.2 (H, suspect artifact given hemolysis) Lytes: Na 148, K 4.2, Cl 110 (Na/K 35) Baseline cortisol: 7.1 (H)

ULTRASONOGRAPHIC EXAMINATION OF THE ABDOMEN**Urinary System**

The **urinary bladder** is not fully distended. The wall is very mildly irregular, however this may be due to an incompletely filled urinary bladder, rather than pathology. No abnormalities are present with the trigone. Its contents are primarily anechoic, except for a small amount of free floating sediment and echogenic strings. There is no evidence of cystoliths, polyps or a mass. The free floating sediment is most likely composed of mucus, crystalline material and exfoliated cells.

Note, the urinary bladder was in one of the images at the end of the exam at which time, a round, echogenic structure, measuring 5.1 mm x 6.2 mm, was visualized. It had settled to the gravity-dependent wall. Acoustic shadowing is not present.

The **prostate** is homogenous and measures 0.66 cm; within normal limits for a neutered male.

Kidneys

The **left kidney** measures 3.21 cm. The capsule is smooth. Although its overall architecture is preserved, a hyperechoic band is observed along the medulla, traversing parallel to the corticomedullary junction. The band accentuates the definition of the cortico-medullary junction. Mineralizations of the arcuate arteries are present, without evidence of nephroliths or pyelectasia. The surrounding mesentery is not hyperechoic

The **right kidney** measures 3.33 cm. Findings are similar to the left kidney.

Aortic bifurcation/trifurcation

No abnormalities observed.

Adrenal Glands

The **left adrenal gland** measures 0.37 cm at the cranial pole, 0.31 cm at the caudal pole. No abnormalities are noted with the gland's overall architecture, echogenicity or echotexture. The phrenico-abdominal vein and surrounding vasculature and mesentery are unremarkable.

**PATIENT**Hamilton Sprague
273881

The **right** adrenal gland measures 0.49 cm at the cranial pole, 0.53 cm at the caudal pole. No abnormalities are noted with the gland's overall architecture, echogenicity or echotexture. The phrenico-abdominal vein and surrounding vasculature and mesentery are unremarkable.

SPECIES

Canine

Spleen

The spleen is within normal limits in size, architecture, echotexture, and echogenicity. The capsule is smooth. No abnormalities are observed with its vasculature, i.e. congestion and thrombi are not identified.

BREED

Poodle X

Liver

The sonographer felt the liver was mildly decreased in size. Hepatic size is better characterized at the time of the ultrasound or, ideally, radiographically. Liver size may appear slightly decreased if a patient has a deep thorax. The liver's borders are smooth and sharp. Its echotexture is homogeneous and it is within normal limits in echogenicity. Focal lesions are not observed, and no abnormalities are noted with the hepatic vessels.

SEX

Neutered Male

The **gallbladder** (GB) wall is within normal limits in thickness and echogenicity. A small amount of echogenic material is present within the GB. The portions of the cystic and/or common bile ducts observed are not dilated or tortuous, i.e. there are no signs of an obstruction. The parenchyma surrounding the GB is hyperechoic.

AGE

1 Year 5 Months

Gastrointestinal**WEIGHT**

3.7 kg

Although the gastric wall is within normal limits in thickness and the wall layers are well defined, the mucosa appears more prominent in certain regions. Obvious erosions, a foreign body or a mass are not visualized. No obvious abnormalities are observed with its peristalsis.

INTERPRETED BYBeth Johnson, DVM
DACVIM

Duodenum: No abnormal findings noted with wall thickness or definition of the wall layers. The small intestinal wall thickness is within normal limits and the definition of the wall layers is preserved. However, mild fogging and stippling of a few segments of jejunum are present. The submucosa of the jejunum is also more prominent than usual. Ingesta, fluid and gas are observed passing through a segment of jejunum adjacent to the mesenteric lymph nodes. The ingesta is granular and echogenic. Peristalsis appears within normal limits. An obvious foreign body is not visualized. No abnormalities are observed with the ileocecal colic junction. Abnormally dilated loops of bowel are not observed.

IMAGING PERFORMED BY

Tom McNeill

The colonic wall is not thickened and mural detail is conserved.

HOSPITAL NAME

SVS Imaging CT

Pancreas

No abnormalities are observed with the architecture, contours, echogenicity or echotexture of the pancreas. There is no evidence of hyperechogenicity of the surrounding mesentery, i.e., signs of active pancreatitis are not present.

REFERRING VET

WVRC - Dr. Sevede

Other**Lymph nodes (LNs)**

The right medial iliac lymph node is mildly prominent, but within normal limits in size. Two hypoechoic areas are noted.

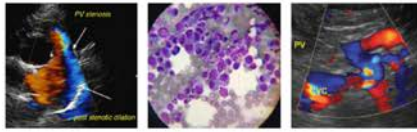
INVOICE

39350

A lymph node located midline and ventral to the aortic trifurcation is mildly enlarged and hypoechoic. It measures 0.68 cm in diameter x 1.03 cm in length. It has smooth borders, but is rounder and more "plump" than usual.

DATE

7/8/22

**PATIENT**Hamilton Sprague
273881

Most of the mesenteric lymph nodes are mildly prominent, but remain within normal limits in echogenicity, echotexture and architecture. They are within normal limits to very mildly increased in size (0.54 cm), however, younger adults can have mildly larger lymph nodes.

SPECIES

Canine

One of the mesenteric lymph nodes, measuring 0.83 cm x 3.38 cm, has mildly irregular contours compared to the others, i.e. this LN appears reactive.

BREED

Poodle X

The gastric lymph node is visualized and is mildly heterogeneous, with both hyperechoic and hypoechoic regions. It measures 0.33 cm in diameter x 0.61 cm in length.

Abdominal effusion is not visualized.

SEX

Neutered Male

ULTRASONOGRAPHIC FINDINGS

- **Gastrointestinal tract:** The gastrointestinal changes are consistent with inflammation associated with a chronic enteropathy. For example, inflammatory bowel disease, food intolerance, dysbiosis, etc. Bacterial infections with *Campylobacter* spp, *Clostridium* spp, *E. coli*, *Salmonella* cannot be excluded as Hamilton receives a raw diet.
- **Lymph nodes:** Reactive hyperplasia of one of the mesenteric lymph nodes (LNs) is suspected. A combination of reactive hyperplasia and mildly more prominent LNs due to Hamilton's young age is the most likely explanation.
- **Kidneys:** The medullary rim band may be suggestive of inflammation, such as, glomerulonephritis and proteinuria. The significance of the mineralization of the arcuate arteries is unknown for a dog of Hamilton's age. An evaluation of the amount of calcium in his raw diet is suggested.
- **Urinary bladder:** The sediment within the lumen is most likely clinically insignificant. The bladder wall is mildly irregular, which may be due to an infection or a result of incomplete filling. Findings should be correlated with clinical signs and a urinalysis. The echogenic structure visualized at the end of the exam may be aggregated sediment and mucus. It is not consistent with a cystolith.
- **Gallbladder:** Gallbladder **sludge** is often clinically insignificant, however, gastroesophageal reflux disease (GERD), can occur in some patients. Hamilton appears to be suffering from GERD based on the history provided. Treatment with an anti-acid, proton pump inhibitor for 2 to 3 weeks may be required.
- **Liver:** No obvious abnormalities are noted with the liver's architecture, echogenicity or echotexture, however, the sonographer felt the liver was mildly decreased in size. Hepatic size is better characterized at the time of the ultrasound or, ideally, radiographically. Liver size may appear slightly decreased if a patient has a deep thorax.

AGE

1 Year 5 Months

WEIGHT

3.7 kg

INTERPRETED BYBeth Johnson, DVM
DACVIM**IMAGING PERFORMED BY**

Tom McNeill

HOSPITAL NAME

SVS Imaging CT

REFERRING VET

WVRC - Dr. Sevde

INTERPRETATION OF THE FINDINGS & FURTHER RECOMMENDATIONS

The following are suggested/recommended

INVOICE

39350

Urinalysis, +/- urine culture

Urine protein creatinine ratio, if the urine culture is negative

DATE

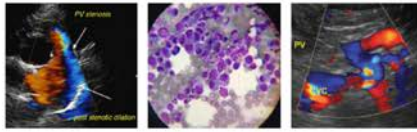
7/8/22

+/- GI PCR panel, primarily to exclude bacterial infections due to raw meat diet

If signs of GERD currently present, 10-14 day trial with famotidine or omeprazole (0.7-1 mg/kg PO)

IMAGING PERFORMED BY

SVS Mobile Imaging CT 262 - 366 - 5970
fredgromalak@gmail.com



EDUCATIONAL TELECONSULTATION SERVICES™

1-800-838-4268 info@sonopath.com SonoPath.com

PATIENT

q12h)

Hamilton Sprague
273881

Serum cobalamin, folate, TLI to exclude dysbiosis and possible EPI.

SPECIES

Evaluation of fasting triglycerides to exclude hyperlipidemia as cause of gallbladder sludge and GERD

Canine

A clay based paste, containing montmorillonite and a synbiotic, may be administered during episodes of acute diarrhea.

BREED

Soluble fibre supplementation, e.g., psyllium

Poodle X

Note, supplementation with psyllium (soluble fibre) may be required if a hydrolyzed hypoallergenic diet is fed.

SEX

Avoid antibiotics, unless signs of sepsis develop.

Neutered Male

Small, frequent meals

AGE

Small meal prior to bedtime

1 Year 5 Months

Once feeling better, deworm, (e.g., fenbendazole), even if receiving monthly heartworm prevention.

WEIGHT

3.7 kg

Hill's Biome may be tried, however, if there is no improvement in vomiting, a dietary trial (veterinary prescription, hypoallergenic, hydrolyzed or novel protein), is suggested. Due to Hamilton's recurring otitis externa, Royal Canin Ultamino or Purina HA should be prioritized. Royal Canin Hydrolyzed Protein is another option, Hill's d/d. Hypoallergenic diets also available through Rayne.

INTERPRETED BY

Endoscopy and biopsies of the upper and lower GI tract may eventually be required, if no response to deworming, dietary trials and other suggestions, above.

Beth Johnson, DVM
DACVIM

IMAGING PERFORMED BY

Tom McNeill

HOSPITAL NAME

SVS Imaging CT

REFERRING VET

WVRC - Dr. Sevde

INVOICE

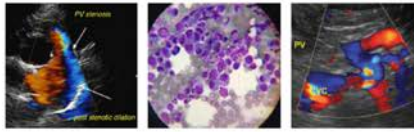
39350

DATE

7/8/22

IMAGING PERFORMED BY

SVS Mobile Imaging CT 262-366-5970
fredgromalak@gmail.com



PATIENT

Hamilton Sprague
273881

SPECIES

Canine

BREED

Poodle X

SEX

Neutered Male

AGE

1 Year 5 Months

WEIGHT

3.7 kg

INTERPRETED BY

Beth Johnson, DVM
DACVIM

IMAGING PERFORMED BY

Tom McNeill

HOSPITAL NAME

SVS Imaging CT

REFERRING VET

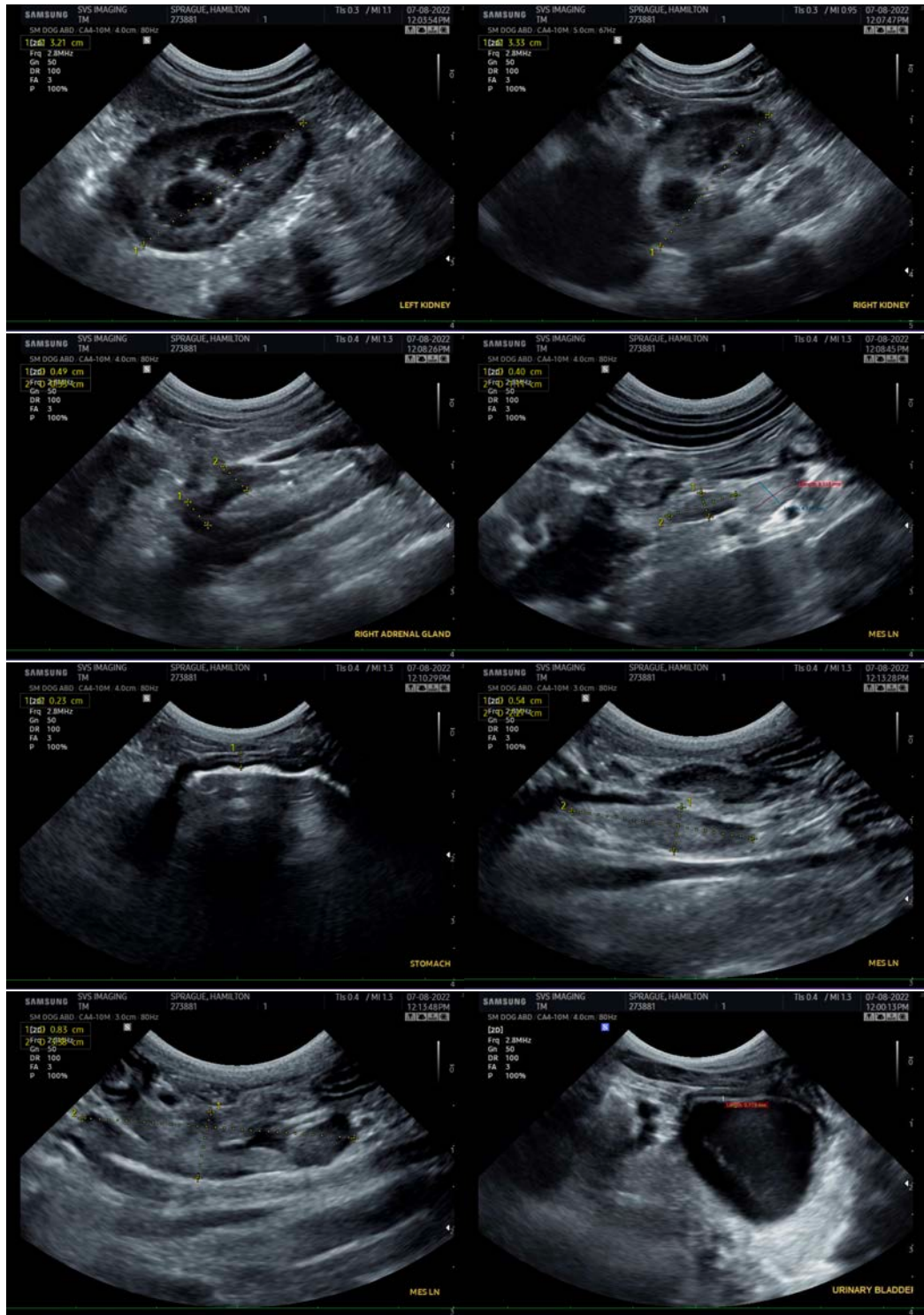
WVRC - Dr. Sevde

INVOICE

39350

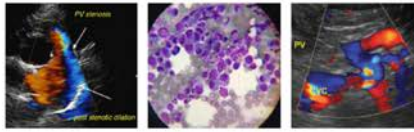
DATE

7/8/22



IMAGING PERFORMED BY

SVS Mobile Imaging CT 262-366-5970
fredgromalak@gmail.com



PATIENT

Hamilton Sprague
273881

SPECIES

Canine

BREED

Poodle X

SEX

Neutered Male

AGE

1 Year 5 Months

WEIGHT

3.7 kg

INTERPRETED BY

Beth Johnson, DVM
DACVIM

IMAGING PERFORMED BY

Tom McNeill

HOSPITAL NAME

SVS Imaging CT

REFERRING VET

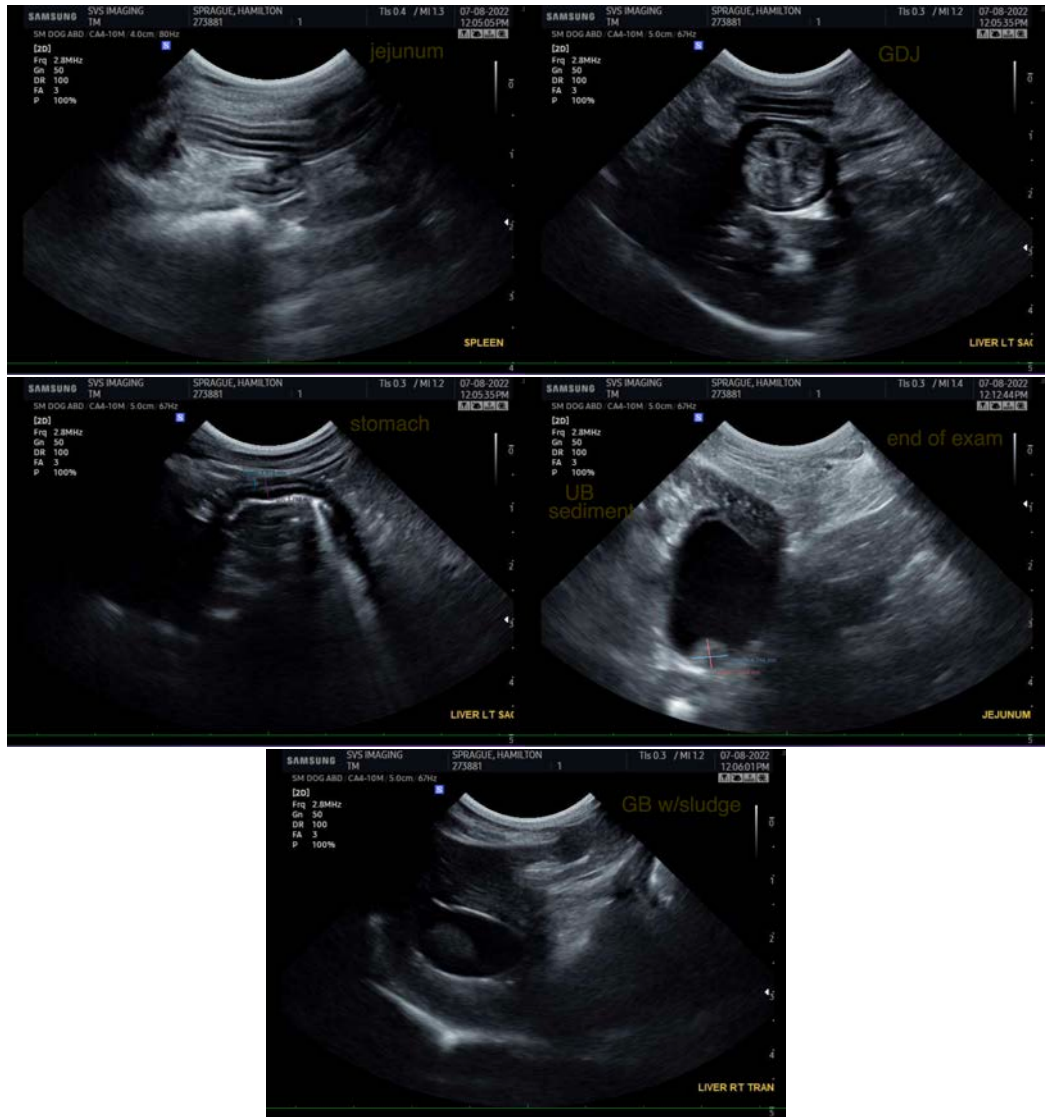
WVRC - Dr. Sevde

INVOICE

39350

DATE

7/8/22



The information and recommendations provided are based on the images presented by the referring veterinarian/sonographer. No evaluation can be communicated regarding pathology that was not visible in the image/video clips provided.

Thank you for this referral. If the clinical or image interpretation does not parallel your findings or if I can be of any further assistance please contact me.

Lisa Carioto, DVM, DVSc, Diplomate ACVIM

Lisa.Carioto@sonopath.com