



PATIENT

Frida Bradley

SPECIES

Canine

BREED

Dachshund

SEX

Spayed female

AGE

7 years

WEIGHT

11.6 lbs

INTERPRETED BY

Lisa Carioto, DVM,
DVSc, Diplomate
ACVIM

IMAGING PERFORMED BY

M Kermendy CVT

HOSPITAL NAME

Wauwautosa VC

REFERRING VET

Dr. Binor

INVOICE

31827

DATE

7/19/22

PRESENTING CLINICAL SIGNS

History: History of renal disease since 03/2020. Was azotemic prior to a dental prophy. Lepto PCR was negative in June 2020. Pet started K/D diet at that time. BUN has consistently been elevated >100 since March 2020. Has been on SQ fluids but have recently been tapering fluids off. Abdominal imaging today to determine status of kidneys and compare to last imaging done March 2021 where mild degenerative renal changes with mineralization was noted. (March 3, 2021 invoice # 85665)
Abnormal PE/Chem/CBC/UA Results: 6/24/22 BUN=101 (9-31) Creat=1.4 (0.5-1.5) Potassium=3.8 (4.0-5.4) Occult blood fecal test was negative on 6-11-22

ULTRASONOGRAPHIC EXAMINATION OF THE ABDOMEN

Urinary System

The urinary bladder is well distended. The wall is smooth and regular. No abnormalities are present with the trigone or proximal urethra. A very small amount of free floating sediment is present, however, there is no evidence of cystoliths, polyps or a mass.

Kidneys

The **left** kidney measures 3.63 cm. The capsule is smooth. The cortex is hyperechoic and a mild loss of the normal definition of the cortico-medullary junction is present. Occasional mineralizations of the diverticulae and pelvis are present. There is no evidence of nephroliths or pyelectasia. The surrounding mesentery is not hyperechoic.

The **right** kidney measures 4.11 cm. The capsule is smooth. The cortex is hyperechoic (it is hyperechoic to the liver) and a mild loss of the normal definition of the cortico-medullary junction is present. Occasional mineralizations of the diverticulae and pelvis are present without evidence of nephroliths. Very mild pyelectasia is noted (longitudinal 1.39 mm). The surrounding mesentery is not hyperechoic.

Aortic bifurcation/trifurcation No abnormalities observed.

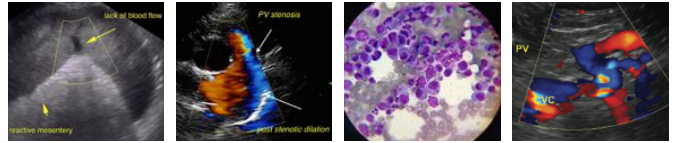
Adrenal Glands

The **left** adrenal gland measures 0.47 cm at the cranial pole, 0.36 cm at the caudal pole and 1.38 cm in length. No abnormalities are noted with the gland's overall architecture, echogenicity or echotexture. The phrenico-abdominal vein and surrounding vasculature and mesentery are unremarkable.

The **right** adrenal gland measures 0.39 cm at the cranial pole, 0.38 cm at the caudal pole and 0.97 cm in length. No abnormalities are noted with the gland's overall architecture, echogenicity or echotexture. The phrenico-abdominal vein and surrounding vasculature and mesentery are unremarkable.

Spleen

The spleen is within normal limits in size, architecture, echotexture, and echogenicity. The capsule is smooth. No abnormalities are observed with its vasculature, i.e. congestion and thrombi are not identified.



PATIENT	Liver
Frida Bradley	There are no obvious signs of hepatomegaly and its borders are smooth and sharp. It is within normal limits in echogenicity (it is hypoechoic to the spleen). No abnormalities are observed with its echotexture. Focal lesions are not observed and no abnormalities are observed with the hepatic vessels.
SPECIES	
Canine	The gallbladder (GB) is mildly dilated (consistent with a fasted individual) with a small amount of free floating and gravity-dependent echogenic material (sludge). The GB wall is within normal limits in thickness and echogenicity. The portions of the cystic and/or common bile ducts observed are not dilated or tortuous, i.e. there are no signs of an obstruction. The parenchyma surrounding the GB is not hyperechoic.
BREED	
Dachshund	
SEX	Gastrointestinal
Spayed female	The gastric wall is within normal limits in thickness and the wall layers are well defined. No obvious abnormalities are observed with its peristalsis.
AGE	
7 years	The small intestinal wall thickness, including the duodenum, is within normal limits and the definition of the wall layers is preserved. Abnormally dilated loops of bowel are not observed. A large amount of gas and ingesta are present within the transverse colon.
WEIGHT	
11.6 lbs	The colonic wall is not thickened and mural detail is considered normal. There are no obvious signs of a mass, foreign body, infiltrative disease or an obstruction in the gastrointestinal tract.
INTERPRETED BY	
Lisa Carioto, DVM, DVSc, Diplomate ACVIM	Pancreas
IMAGING PERFORMED BY	The pancreas has a mildly coarse echotexture. These changes are suggestive of nodular hyperplasia. The parenchyma is isoechoic to the surrounding omentum. Signs of active pancreatitis or neoplasia are not appreciated.
M Kermendy CVT	Other
HOSPITAL NAME	Lymph nodes No abnormalities are observed
Wauwautosa VC	Abdominal effusion is not visualized.
REFERRING VET	ULTRASONOGRAPHIC FINDINGS
Dr. Binor	<ul style="list-style-type: none"> Urinary bladder: The free floating sediment within the lumen of the urinary bladder is most likely composed of mucus, crystalline material and exfoliated cells. The debris is most likely clinically insignificant given the lack of inflammatory changes to the bladder wall, however, findings should be correlated with clinical signs and a urinalysis, +/- urine culture and sensitivity. Kidneys: Non-specific age-related degenerative changes are present, as well as very mild mineralizations. Very mild pyelectasia of the right kidney may be due to the administration of
INVOICE	
31827	
DATE	
7/19/22	



PATIENT	subcutaneous fluids, and polydipsia and polyuria. Obvious signs of pyelonephritis, which can also cause pyelectasia, are not appreciated.
Frida Bradley	
SPECIES	<u>INTERPRETATION OF THE FINDINGS & FURTHER RECOMMENDATIONS</u>
Canine	A SNAP 4Dx is suggested, if not already performed.
BREED	A urine protein: creatinine is suggested, if not already performed.
Dachshund	A SDMA is a more sensitive and specific test to trend compared to urea, which is affected by many factors.
SEX	Monitor body condition and muscle condition scores Frida does not become sarcopenic on a low protein diet.
Spayed female	Monitor phosphorus concentrations
AGE	Potassium supplementation may be considered.
7 years	Arterial blood pressure
WEIGHT	Canned food and Purina Hydra Care may be given to maintain hydration.
11.6 lbs	Omega-3 fatty acids may also help improve blood flow to the kidneys.

INTERPRETED BY

Lisa Carioto, DVM,
DVSc, Diplomate
ACVIM

IMAGING PERFORMED BY

M Kermendy CVT

HOSPITAL NAME

Wauwautosa VC

REFERRING VET

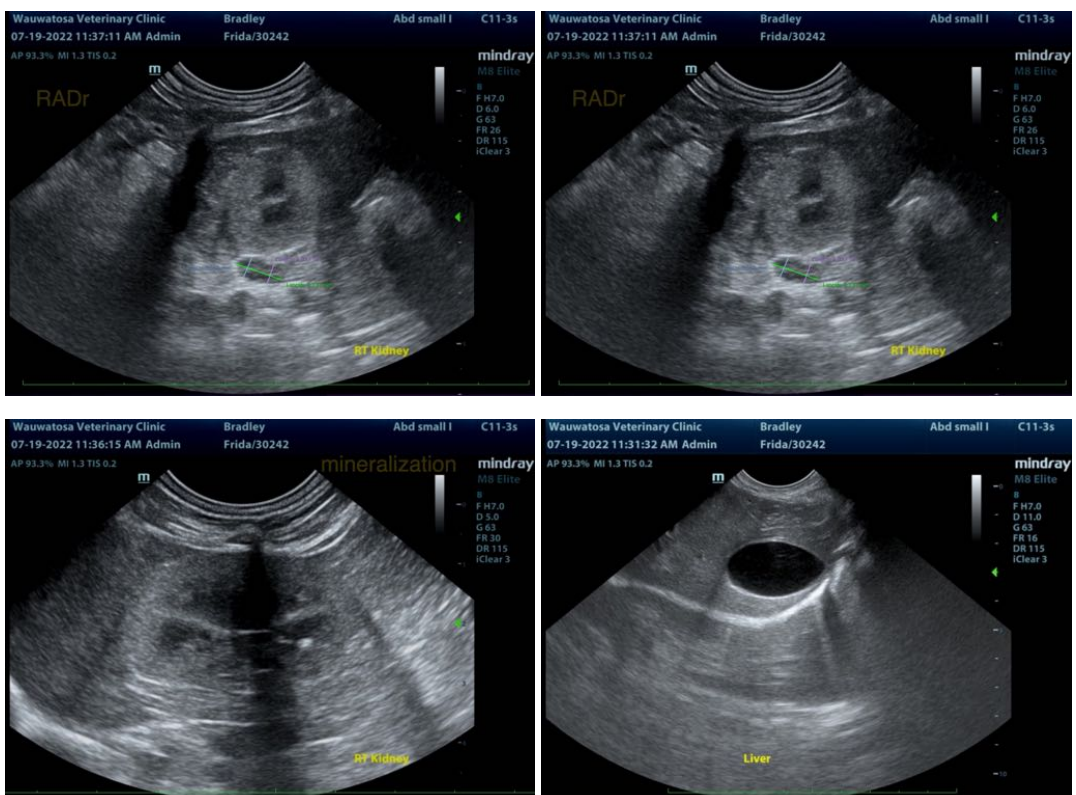
Dr. Binor

INVOICE

31827

DATE

7/19/22





PATIENT

Frida Bradley

SPECIES

Canine

BREED

Dachshund

SEX

Spayed female

AGE

7 years

WEIGHT

11.6 lbs

INTERPRETED BY

Lisa Carioto, DVM,
DVSc, Diplomate
ACVIM

**IMAGING
PERFORMED BY**

M Kermendy CVT

HOSPITAL NAME

Wauwautosa VC

REFERRING VET

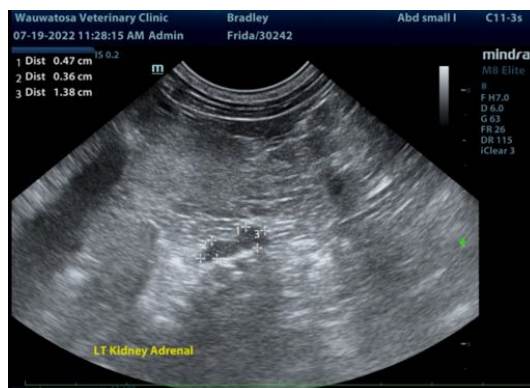
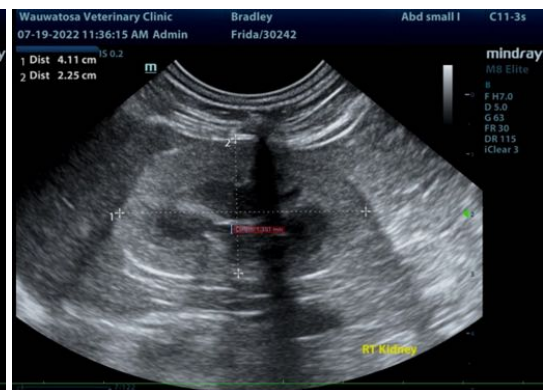
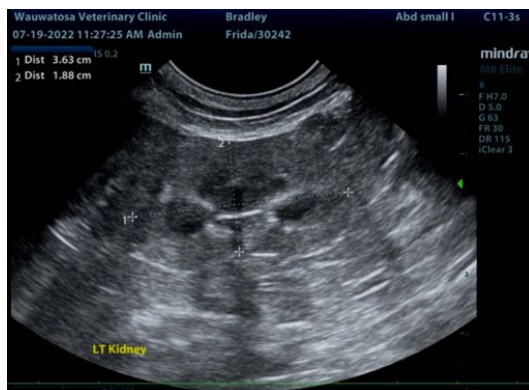
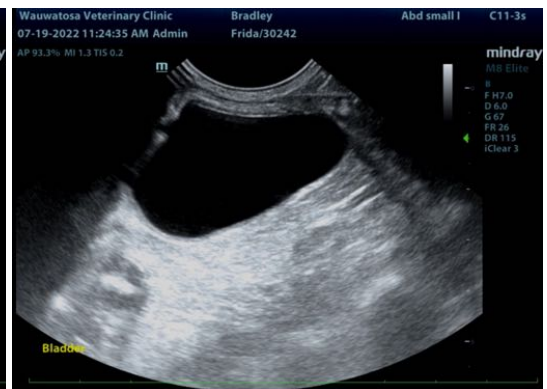
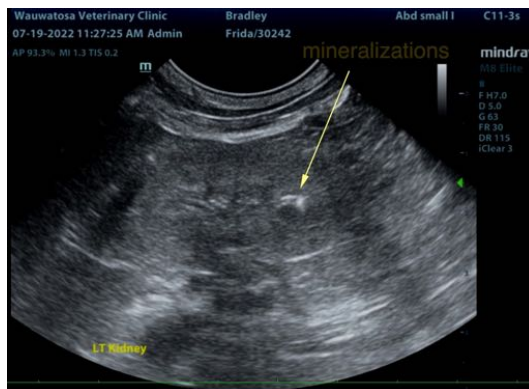
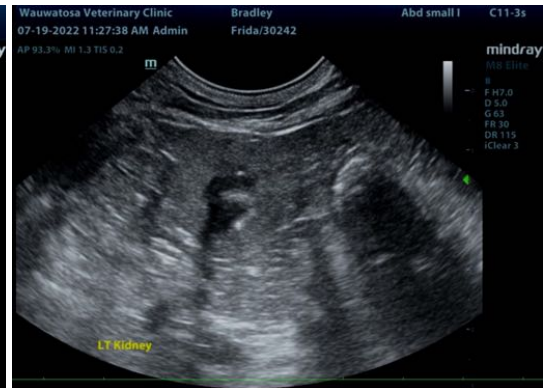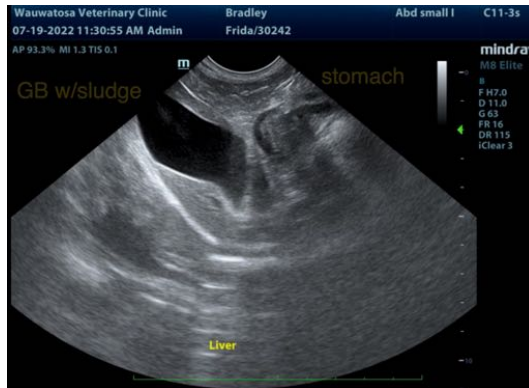
Dr. Binor

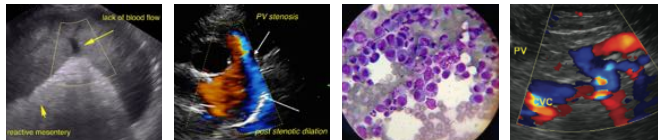
INVOICE

31827

DATE

7/19/22





PATIENT

Frida Bradley

The information and recommendations provided are based on the images presented by the referring veterinarian/sonographer. No evaluation can be communicated regarding pathology that was not visible in the image/video clips provided.

SPECIES

Canine

Thank you for this referral. If the clinical or image interpretation does not parallel your findings or if I can be of any further assistance please contact me.

Lisa Carioto, DVM, DVSc, Diplomate ACVIM

Lisa.Carioto@sonopath.com

BREED

Dachshund

SEX

Spayed female

AGE

7 years

WEIGHT

11.6 lbs

INTERPRETED BY

Lisa Carioto, DVM,
DVSc, Diplomate
ACVIM

**IMAGING
PERFORMED BY**

M Kermendy CVT

HOSPITAL NAME

Wauwautosa VC

REFERRING VET

Dr. Binor

INVOICE

31827

DATE

7/19/22