

**DATE**

6/30/22

PRESENTING CLINICAL SIGNS

P presented 6/29/22 for inappetence, PU/PD and lethargy. On PE, p was tense/painful and had a temp of 104.2.

Current Medications: None- SQ fluids given.

PATIENT

Bella Willsford

Lab Results: HCT 59.87 (37-55), neutrophilia 14,450 (3000-12,000), ALP- value was suppressed on two samples, ALT 844 (10-118) tbili 1.7 (0.1-0.6).

Date of Previous IntraPet Ultrasound: No previous.

Sedation: Not required to complete full diagnostic ultrasound.

SPECIES

Canine

Stat Report: Declined.

Imaging Performed By: Stephanie Pearce RDCS, RVT.

BREED

Maltese Mix

ULTRASONOGRAPHIC EXAMINATION OF THE ABDOMEN**Urinary System****SEX**

Spayed Female

The urinary bladder is well distended with anechoic contents. The wall is smooth and regular. No abnormalities are noted with the trigone or proximal urethra, and there is no evidence of cystoliths, polyps or a mass. A trivial amount of sediment is present within the urinary bladder.

AGE

1/1/13

Kidneys

The **left** kidney measures 4.11 cm. The capsule is smooth. The normal definition of the cortico-medullary junction is present. Mild mineralizations of the diverticulae and pelvis are present, without evidence of nephroliths or pyelectasia. Blood flow is within normal limits to increased. The surrounding mesentery is mildly hyperechoic, however, it appears to be associated with the pancreas, rather than the kidney.

WEIGHT

12.6 lbs

The **right** kidney measures 4.27 cm. The capsule is smooth. The normal definition of the cortico-medullary junction is present. Mild mineralizations of the diverticulae and pelvis are present, without evidence of nephroliths or pyelectasia. Blood flow is within normal limits. The surrounding mesentery is mildly hyperechoic, however, it appears to be associated with the pancreas, rather than the kidney.

INTERPRETED BY

Lisa Carioto, DVM,
DVSc, Diplomate
ACVIM

Aortic bifurcation/trifurcation

No abnormalities observed.

HOSPITAL NAME

Charm City VH

Adrenal Glands

The **left** adrenal gland measures 0.63 cm at the cranial pole, 0.48 cm at the caudal pole and 1.60 cm in length. The cranial pole is "plump" and nodular. There is no evidence of a mass. No abnormalities are noted with the gland's overall echogenicity or echotexture. The phrenico-abdominal vein and surrounding vasculature and mesentery are unremarkable.

REFERRING VET

Dr. Eavers

The **right** adrenal gland measures 0.61 cm at the cranial pole, 0.55 cm at the caudal pole and 1.60 cm in length. The cranial pole is mildly rounded and "plump", however, a well-defined mass is not visualized. The cranial pole measures 0.59 and the caudal pole 0.48 cm in a different view. No abnormalities are noted with the gland's overall architecture, echogenicity or echotexture. The phrenico-abdominal vein and surrounding vasculature are unremarkable. The surrounding mesentery is hyperechoic, which is attributed to the pancreas, rather than the adrenal gland.

INVOICE

31362

Spleen

The spleen is within normal limits in architecture, echotexture, and echogenicity. The capsule is smooth. Mild splenomegaly cannot be excluded. Perivascular cuffing, consistent with myelolipomas, is noted. They

are not considered clinically significant. No abnormalities are observed with its vasculature, i.e. congestion and thrombi are not identified.

Liver

Although there are no obvious signs of hepatomegaly, the liver appears “swollen”. Its borders are smooth, but rounded. The liver is within normal limits in echogenicity, however, a false impression of diffuse hypoechoogenicity is given as a result of the marked hyperechogenicity of the surrounding mesentery. The echotexture is diffusely coarse, which is created by echogenic portal walls. Focal lesions are not visualized. No obvious abnormalities are noted with the hepatic veins.

The gallbladder wall is thickened (2.1 mm) and moderately to severely hyperechoic. A circumferential hypoechoic “halo effect” surrounding the gall bladder is observed, which is suggestive of edema and/or free fluid. A trivial amount of echogenic material is present within the GB. The portions of the cystic and/or common bile ducts observed are not dilated or tortuous, i.e. there are no signs of an obstruction.

Gastrointestinal

A large amount of gas and fluid are present within the lumen of the stomach. Although the gastric wall is within normal limits in thickness and the wall layers are well defined, the mucosa is more prominent than usual and stippling is evident. Decreased peristalsis, i.e. an ileus, is evident.

A large amount of fluid and gas are present within the lumen of the duodenum. Fogging of the mucosa of the duodenum is present.

The small intestinal wall thickness, including the duodenum, is within normal limits and the definition of the wall layers is preserved. The lumen of the small intestines is also fluid filled. A mild to moderate ileus is present.

Ingesta and gas are present within the transverse colon.

The colonic wall is not thickened and mural detail is considered normal. A large amount of gas and soft fecal matter are present within the colon

Pancreas

The pancreas is markedly enlarged and hypoechoic to anechoic with irregular contours. The surrounding mesentery is severely hyperechoic. Multiple poorly defined hyperechoic foci are observed scattered throughout the hypo to anechoic pancreas. There are no obvious signs of neoplasia. Bella is painful in the region of the pancreas during the ultrasound as per the sonographer.

Other

Lymph nodes

Multiple hypoechoic, enlarged gastric and pancreatic lymph nodes are observed. The LNs are round and hypoechoic (0.57 cm in diameter x 0.76 cm in length) and surrounded by a hyperechoic mesentery.

Abdominal effusion is not visualized.

ULTRASONOGRAPHIC FINDINGS

- **Pancreas:** Severe pancreatitis with associated pain. Necrotizing pancreatitis cannot be excluded. Obvious signs of neoplasia are not appreciated.

- **Lymphadenomegaly:** Lymphadenomegaly, which is highly suspicious of reactive hyperplasia. Obvious signs of neoplasia are not evident.
- **Gastrointestinal tract:** Sonographic signs are suggestive of inflammation. An underlying chronic enteropathy, which may include causes, such as inflammatory bowel disease (IBD), food intolerance, dysbiosis, etc. Obvious signs of infiltrative disease are not apparent.
- **Liver:** Cholangitis/cholangiohepatitis and hepatitis secondary to pancreatitis with a secondary bacterial infection cannot be excluded.
- **Gallbladder:** Signs of cholecystitis are present. A suppurative form of the disease must also be considered.
- **Spleen:** Subjectively, the spleen may be mildly enlarged. Splenomegaly may occur secondary to reactive hyperplasia, splenitis, as well as extramedullary hematopoiesis.
- **Urinary bladder:** A trivial amount of sediment within the lumen of the urinary bladder is most likely composed of mucus, crystalline material and exfoliated cells. The debris is likely clinically insignificant given the lack of inflammatory changes to the bladder wall, however, findings should be correlated with clinical signs and a urinalysis.
- **Kidneys:** Very subtle changes are noted, which are likely due to mild age-related degeneration.
- **Adrenal glands:** The adrenal glands are at the high end of the normal reference rate based on Bella's stature. Adrenal hyperplasia due to stress/illness is suspected, rather than neoplasia or pituitary-dependent hyperadrenocorticism.

INTERPRETATION OF THE FINDINGS & FURTHER RECOMMENDATIONS

Aggressive treatment for pancreatitis is recommended

Intravenous fluids – dehydration, additional 10% for pyrexia and maintenance rate

Intravenous analgesics, for example, a CRI of fentanyl, as well as a CRI of lidocaine and ketamine based on the severity of Bella's pain

Anti-emetics

Pantoprazole IV every 12 hours; famotidine IV slowly every 12 hours if the former is not available.

Metoclopramide CRI to treat the ileus may be required

Arterial blood pressure

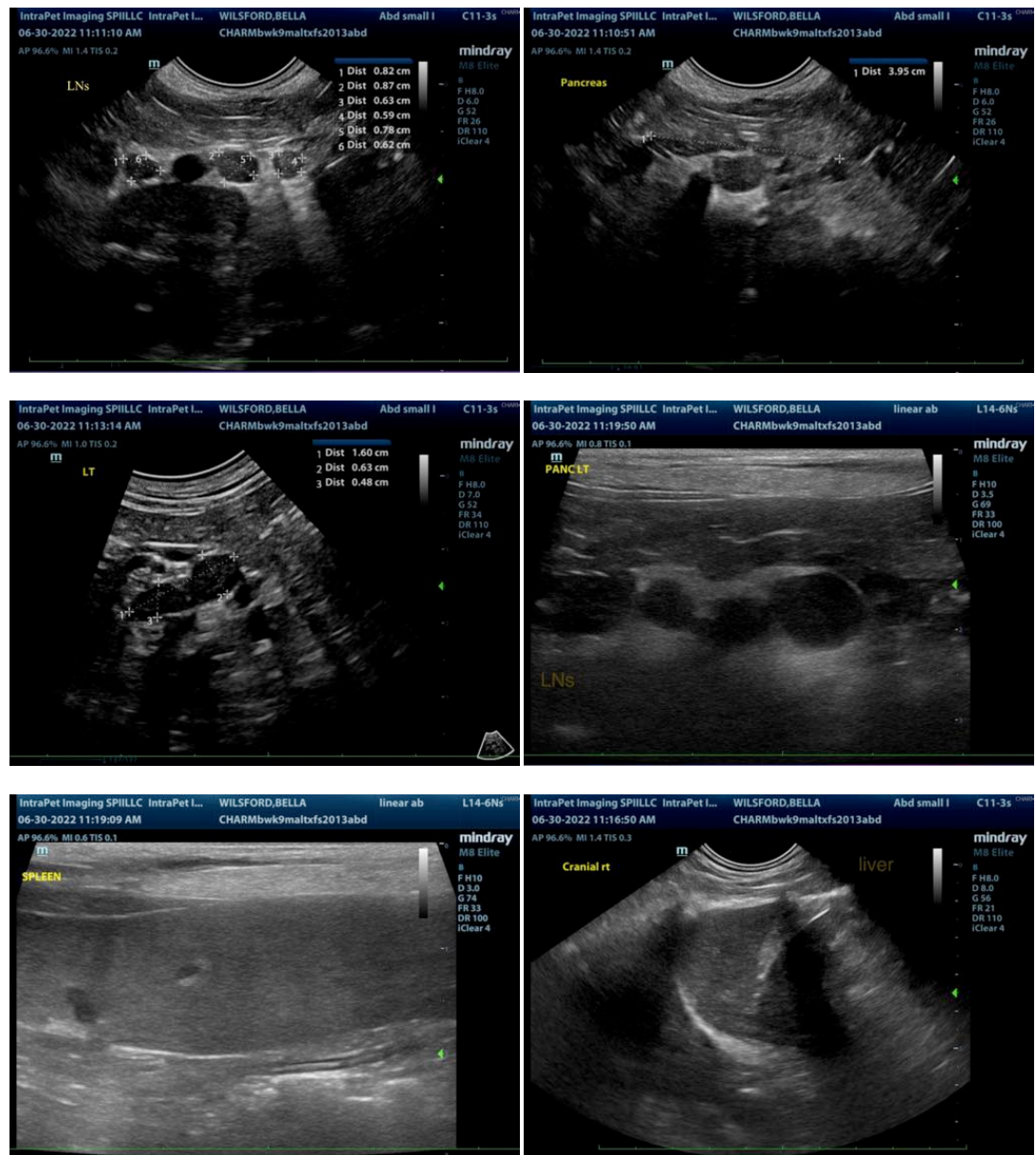
Ins and outs and body weight to ensure hydration status, i.e. RBC parameters showed dehydration

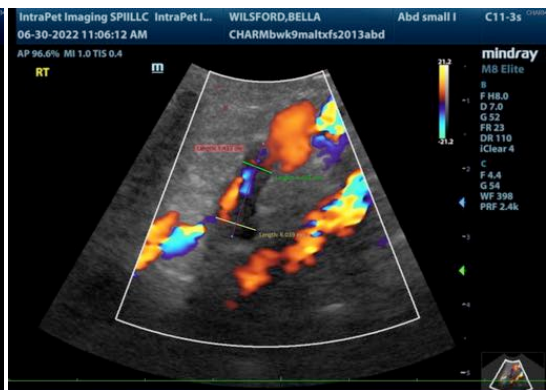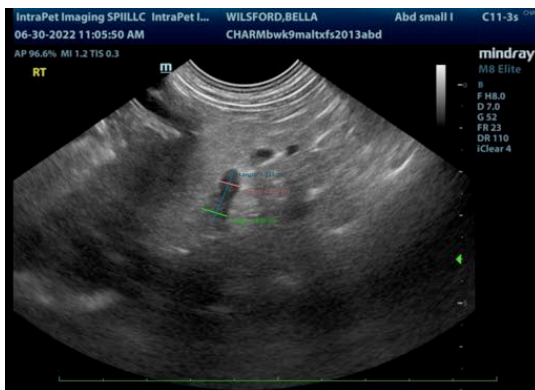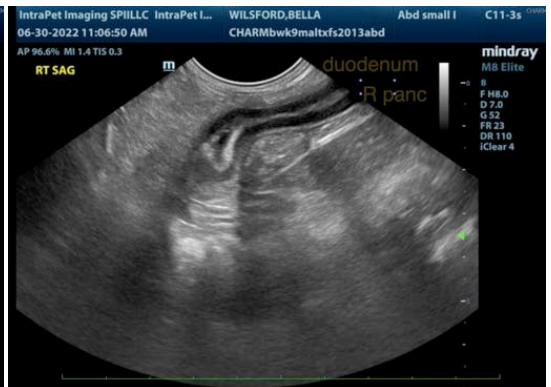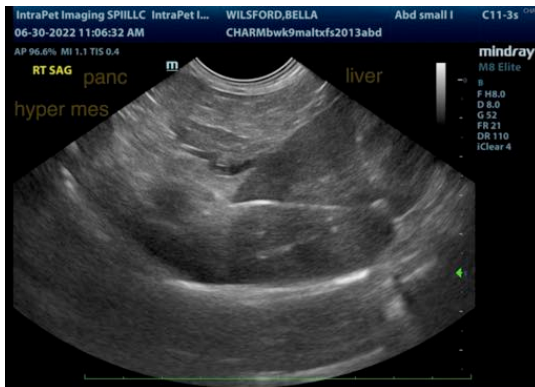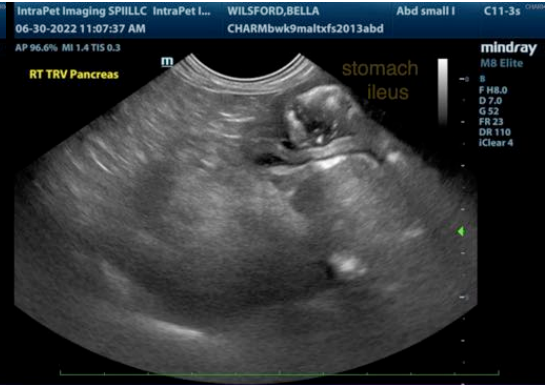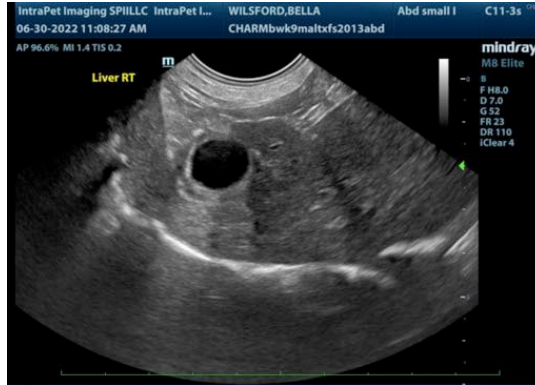Antibiotics are not considered necessary unless Bella's pyrexia does not improve with intravenous fluids and analgesia, or if there are signs of degenerative or toxic neutrophils and bands present on the CBC.

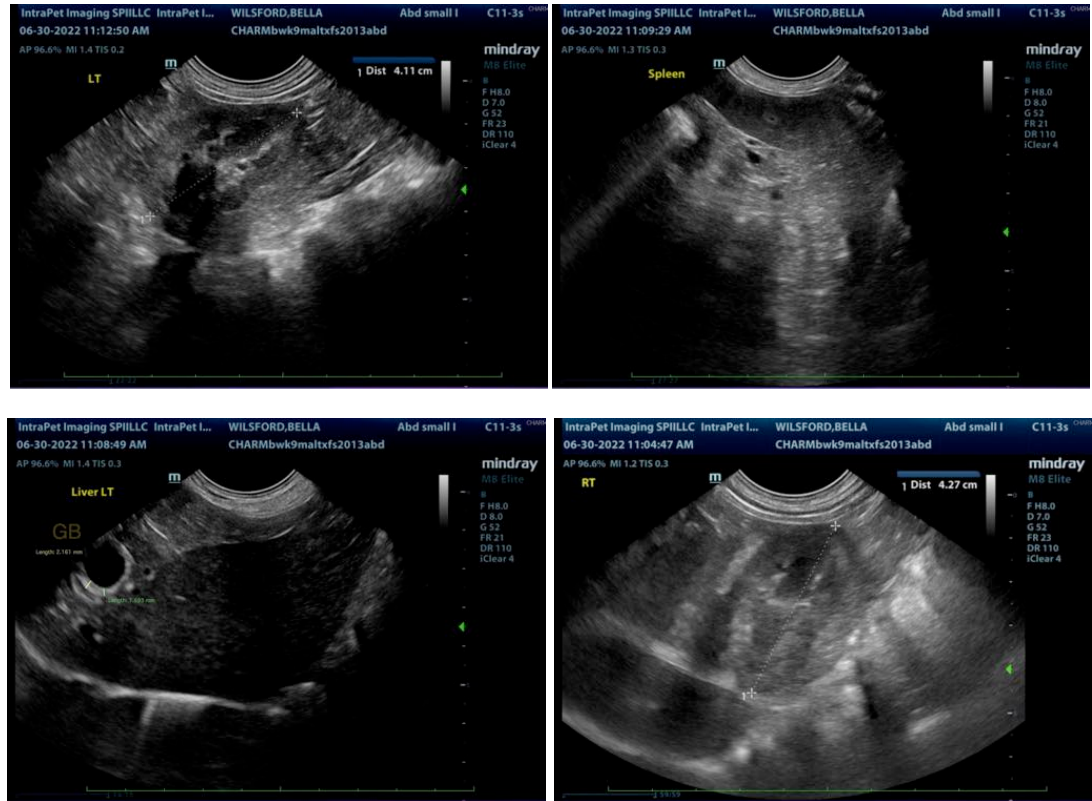
Fresh frozen plasma may also be helpful

A bland, easily digestible, low fat, moderately restricted fibre diet is recommended to help decrease bloating and cramps.

There are no obvious signs of neoplasia, however, further diagnostics, consisting of fine needle aspirates of the, pancreas, lymph nodes, liver and spleen may be considered if Bella does not respond to the above therapy.







The information and recommendations provided are based on the images presented by the referring veterinarian. No evaluation can be communicated regarding pathology that was not visible in the image/video clips provided.

Thank you for this referral. If the clinical or image interpretation does not parallel your findings or if I can be of any further assistance please contact me.

Lisa Carioto, DVM, DVSc, Diplomate ACVIM
Lisa.Carioto@sonopath.com