IMAGING PERFORMED BY

IntraPet.com

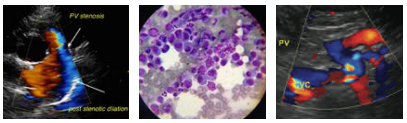

SonoPath
Clinical Sonography & Telecytology
EDUCATIONAL TELECONSULTATION SERVICES™
1-800-838-4268 info@sonopath.com SonoPath.com

**DATE**
6/21/22

**PATIENT**
Sima Roark

**SPECIES**
Feline

**BREED**
Sphinx

**SEX**
Spayed Female

**AGE**
5/2/19

**WEIGHT**
7.2 lbs

**INTERPRETED BY**
Lisa Carioto, DVM, DVSc, Diplomate ACVIM

**HOSPITAL NAME**
All Creatures Veterinary Service

**REFERRING VET**
Dr. Meadows

**INVOICE**
31144

## PRESENTING CLINICAL SIGNS

Chronic diarrhea, over 6 week duration. No improvement with symptomatic care -metro, panacur, EN diet, probiotics. Rx improved urgency though.
Current Medications: Purina Feline EN, Quadruple topical ointment for ear infection.
Lab Results: Fecal Negative, BW NSF, GI Panel pending, FIV/FeLV pending.
Date of Previous IntraPet Ultrasound: No previous.
Sedation: Not required to complete full diagnostic ultrasound.
Stat Report: Not requested.
Imaging Performed By: Rachel Brilhart, RDMS.

## ULTRASONOGRAPHIC EXAMINATION OF THE ABDOMEN

### *Urinary System*

The urinary bladder is well distended with anechoic contents. The wall is smooth and regular. No abnormalities are noted with the trigone or proximal urethra, and there is no evidence of sediment, cystoliths, polyps or a mass.

**Kidneys**

The **left** kidney measures 3.58 cm (3.80-4.40 cm). The capsule is smooth. The definition of the cortico-medullary junction is very mildly decreased with the convex probe, however, *no abnormalities* are observed with the linear probe. There are no signs of nephroliths or pyelectasia. Blood flow is within normal limits. The surrounding mesentery is not hyperechoic.

The **right** kidney measures 3.71 cm (3.80-4.40 cm). The capsule is smooth. The definition of the cortico-medullary junction is very mildly decreased with the convex probe, however, *no abnormalities* are observed with the linear probe. There are no signs of nephroliths or pyelectasia. Blood flow is within normal limits. The surrounding mesentery is not hyperechoic.

**Aortic bifurcation/trifurcation**

No abnormalities observed.

### *Adrenal Glands*

The **left** adrenal gland measures 0.44 cm. No abnormalities are noted with the gland's overall architecture, echogenicity or echotexture. The phrenico-abdominal vein and surrounding vasculature and mesentery are unremarkable.

The **right** adrenal gland measures 0.51 cm. No abnormalities are noted with the gland's overall architecture, echogenicity or echotexture. The phrenico-abdominal vein and surrounding vasculature and mesentery are unremarkable.

### *Spleen*

The spleen is within normal limits in size 6.4 mm (normal = 10 mm), echotexture, and echogenicity. The capsule is smooth. No abnormalities are observed with its vasculature, i.e. congestion and thrombi are not identified.

### *Liver*

There are no obvious signs of hepatomegaly and its borders are smooth and sharp. The liver's echotexture is homogeneous and is within normal limits in echogenicity; i.e. it is hypoechoic to the falciform fat and spleen. Focal lesions are not observed and no abnormalities are observed with the hepatic vessels.

The gallbladder (GB) is moderately dilated, which is not uncommon for a fasted individual. A small amount of free floating and inspissated echogenic material (sludge), some of which have formed nodules of variable size. The GB wall is within normal limits in thickness and echogenicity. The portions of the cystic and/or common bile ducts observed are not dilated or tortuous, i.e. there are no signs of an obstruction. The parenchyma surrounding the GB is not hyperechoic.

### *Gastrointestinal*

The gastric wall is within normal limits in thickness and the wall layers are well defined. No obvious abnormalities are observed with its peristalsis.

The small intestinal wall thickness, including the duodenum, is within normal limits and the definition of the wall layers is preserved. However, mild fogging and stippling of the mucosa of the duodenum and jejunum are noted. No abnormalities are observed with the ileocecal colic junction. Abnormally dilated loops of bowel are not observed. Subjectively, the mesentery surrounding the small intestines is mildly hyperechoic. Ingesta is present within the transverse colon.

The colonic wall is not thickened, but at the high end of the normal reference range. Although mural detail is considered normal, the mucosa and submucosa are more prominent than usual. Gas and semi formed stools are present within the lumen of the colon.

### *Pancreas*

Although no abnormalities are observed with the architecture, contours or echotexture of the pancreas, it is prominent and mildly, but diffusely hypoechoic. However, the surrounding mesentery is not overtly hyperechoic to suggest active pancreatitis. Blood flow of the pancreas is within normal limits.

**Other**

**Lymph nodes**

Multiple **mesenteric** lymph nodes are observed in the region of the ileo-cecal colic junction. They are more prominent, i.e., more "plump" and longer, but smooth, as well as hypoechoic.

**Abdominal effusion** is not visualized.

## ULTRASONOGRAPHIC FINDINGS

- **Gastrointestinal tract**: Colonic changes support recent irritation and inflammation, likely due to Sima's chronic diarrhea. However, an underlying inflammatory process cannot be excluded. Although mild fogging and stippling of the mucosa of the small intestines are somewhat subjective, these findings have been associated with GI inflammation. Therefore, multiple signs of a chronic enteropathy involving the small and large intestines cannot be ignored. Differential diagnoses include inflammatory bowel disease, food intolerance, fibre responsive diarrhea, dysbiosis, etc.

- **Mesenteric lymph nodes**: *Reactive lymphadenomegaly* is suspected, infiltrative disease, such as lymphoma or other round cell tumour, is considered highly unlikely.

- **Mesentery**: Subjectively, the mesentery surrounding the small intestines is mildly hyperechoic, which is suggestive of diffuse inflammation.

- **Pancreas**: The absence of a hyperechoic mesentery surrounding the pancreas decreases the likelihood of pancreatitis, particularly in light of the Precision PSL results, i.e. Sima's pancreas may be

mildly prominent and hypoechoic compared to "normal". Although unlikely, a low grade, smoldering pancreatitis cannot be excluded with certainty.

- **Gallbladder**: Gallbladder sludge is most likely clinically insignificant, however, gastroesophageal reflux disease (GERD), can occur in some patients. Obtaining a history regarding signs of GERD from the client is suggested. Treatment with an anti-acid or a proton pump inhibitor may be required.

- **Adrenal glands**: Subtle adrenomegaly, which may be due to hyperplasia secondary to stress (chronic illness).

## INTERPRETATION OF THE FINDINGS & FURTHER RECOMMENDATIONS

- PCR for *Tritrichomonas foetus* pending

- TLI, serum cobalamin, and folate to assess for underlying maldigestion and malabsorption disease (exocrine pancreatic insufficiency, hypocobalaminemia) and dysbiosis.

- Obtaining a history regarding signs of GERD from the client is suggested. Treatment with an anti-acid or a proton pump inhibitor may be required.

- If signs of GERD, 10-14 day trial with famotidine or omeprazole (0.7-1 mg/kg PO **q12h**). Note, some individuals can develop vomiting, cramps and diarrhea with omeprazole.

- An additional soluble source of fibre, i.e. psyllium, is suggested. Introduce *slowly* to decrease risk of bloating and cramps.

- A clay based paste, containing montmorillonite, are suggested to help treat the diarrhea.

- Analgesia trial (buprenorphine (0.005-0.01 mg/kg, sublingually, every 8-12 hours) with or without gabapentin. Continue for 2-4 weeks, or longer, as needed. Administration even if Sima does not appear painful is recommended.

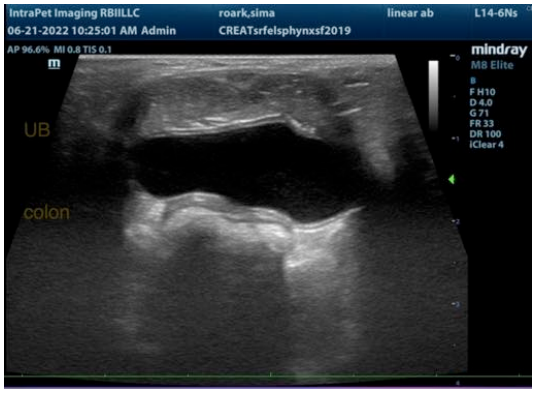

IntraPet Imaging RBIILLC
roark,sima
linear ab
L14-6Ns
06-21-2022 10:23:04 AM Admin
CREATsrfelsphynxsf2019
AP 96.6% MI 0.8 TIS 0.1
mindray
M8 Elite
B
F H10
D 3.5
G 69
FR 33
DR 100
iClear 4

IntraPet Imaging RBIILLC
roark,sima
linear ab
L14-6Ns
06-21-2022 10:23:50 AM Admin
CREATsrfelsphynxsf2019
AP 96.6% MI 0.8 TIS 0.1
L
mindray
M8 Elite
B
F H10
D 3.5
G 69
FR 33
DR 100
iClear 4

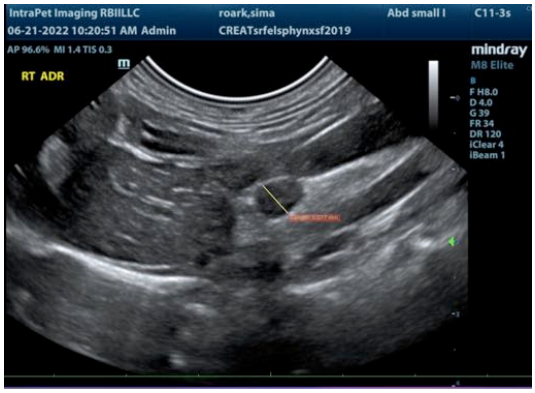
IntraPet Imaging RBIILLC
roark,sima
Abd small I
C11-3s
06-21-2022 10:20:51 AM Admin
CREATsrfelsphynxsf2019
AP 96.6% MI 1.4 TIS 0.3
RT ADR
mindray
M8 Elite
B
F H8.0
D 4.0
G 39
FR 34
DR 120
iClear 4
iBeam 1

IntraPet Imaging RBIILLC
roark,sima
Abd small I
C11-3s
06-21-2022 10:19:46 AM Admin
CREATsrfelsphynxsf2019
AP 96.6% MI 1.4 TIS 0.3
COLON
mindray
M8 Elite
B
F H8.0
D 3.5
G 31
FR 34
DR 120
iClear 4
iBeam 1

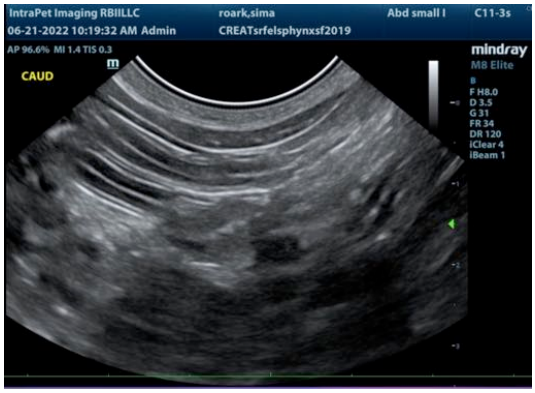
IntraPet Imaging RBIILLC
roark,sima
Abd small I
C11-3s
06-21-2022 10:19:32 AM Admin
CREATsrfelsphynxsf2019
AP 96.6% MI 1.4 TIS 0.3
CAUD
mindray
M8 Elite
B
F H8.0
D 3.5
G 31
FR 34
DR 120
iClear 4
iBeam 1

IntraPet Imaging RBIILLC
roark,sima
Abd small I
C11-3s
06-21-2022 10:16:54 AM Admin
CREATsrfelsphynxsf2019
AP 96.6% MI 1.4 TIS 0.3
Liver
GB w/sludge
mindray
M8 Elite
B
F H8.0
D 6.0
G 57
FR 26
DR 120
iClear 4
iBeam 1

IntraPet Imaging RBIILLC
roark,sima
linear ab
L14-6Ns
06-21-2022 10:24:59 AM Admin
CREATsrfelsphynxsf2019
AP 96.6% MI 0.8 TIS 0.1
COLON
UB
mindray
M8 Elite

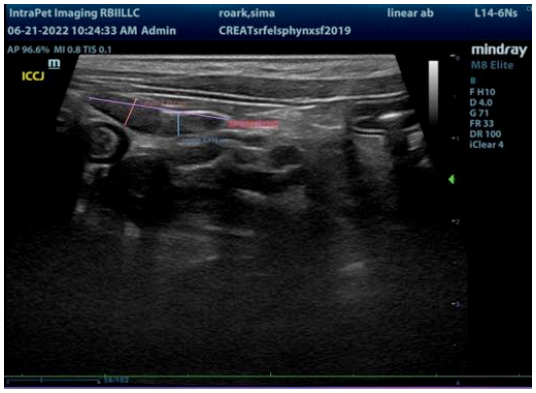
IntraPet Imaging RBIILLC
roark,sima
linear ab
L14-6Ns
06-21-2022 10:24:33 AM Admin
CREATsrfelsphynxsf2019
AP 96.6% MI 0.8 TIS 0.1
ICCJ
mindray
M8 Elite

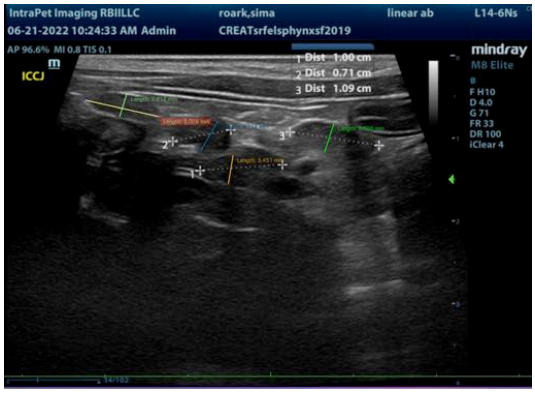
IntraPet Imaging RBIILLC
roark,sima
linear ab
L14-6Ns
06-21-2022 10:24:33 AM Admin
CREATsrfelsphynxsf2019
AP 96.6% MI 0.8 TIS 0.1
ICCJ
1 Dist 1.00 cm
2 Dist 0.71 cm
3 Dist 1.09 cm
mindray
M8 Elite

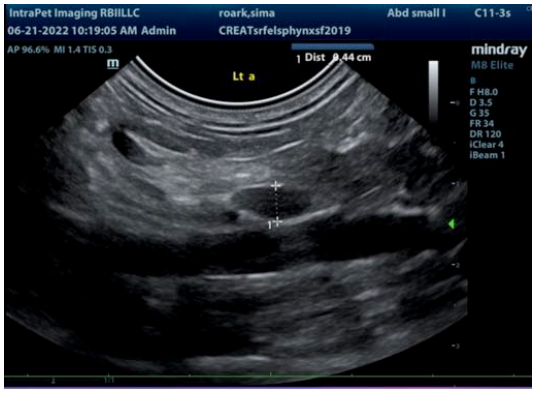
IntraPet Imaging RBIILLC
roark,sima
Abd small I
C11-3s
06-21-2022 10:19:05 AM Admin
CREATsrfelsphynxsf2019
AP 96.6% MI 1.4 TIS 0.3
Lt a
1 Dist 0.44 cm
mindray
M8 Elite

IntraPet Imaging RBIILLC
roark,sima
linear ab
L14-6Ns
06-21-2022 10:23:00 AM Admin
CREATsrfelsphynxsf2019
AP 96.6% MI 0.8 TIS 0.1
colon
mindray
M8 Elite

IntraPet Imaging RBIILLC
roark,sima
linear ab
L14-6Ns
06-21-2022 10:22:50 AM Admin
CREATsrfelsphynxsf2019
AP 96.6% MI 0.8 TIS 0.1
stomach
mindray
M8 Elite

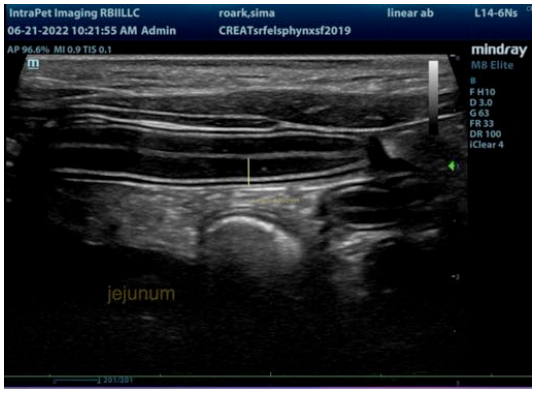


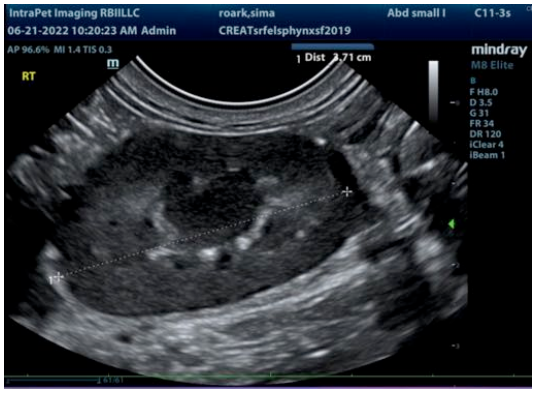


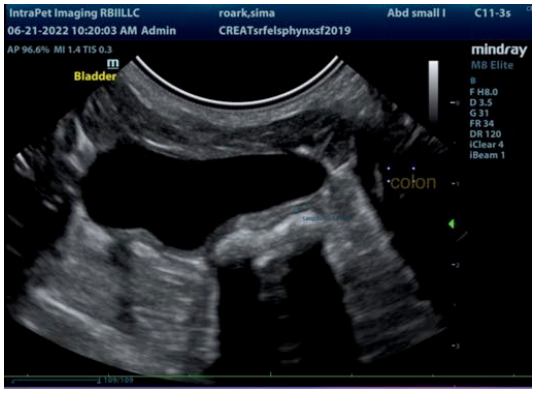


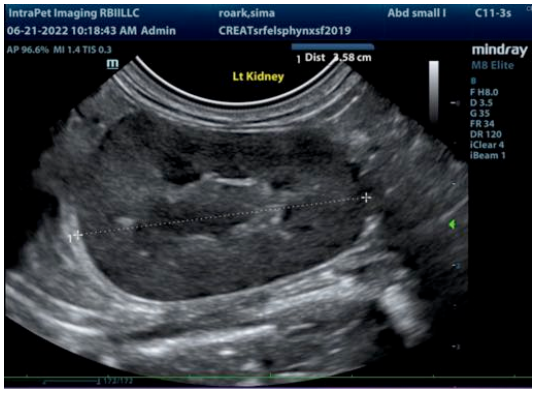


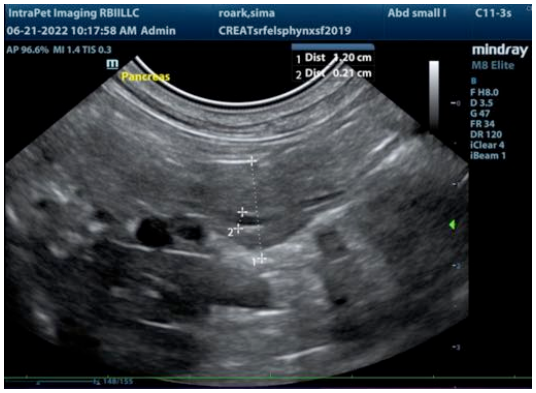


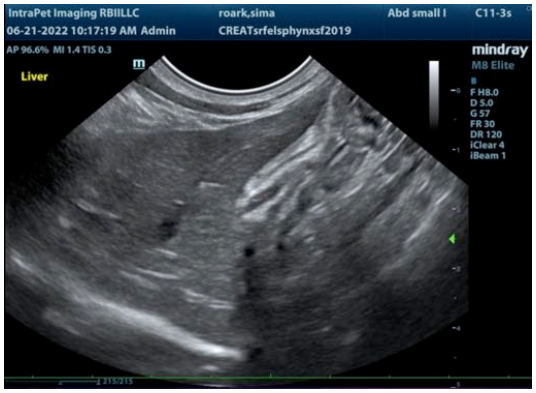


**The information and recommendations provided are based on the images presented by the referring veterinarian. No evaluation can be communicated regarding pathology that was not visible in the image/video clips provided.**

Thank you for this referral. If the clinical or image interpretation does not parallel your findings or if I can be of any further assistance please contact me.

**Lisa Carioto, DVM, DVSc, Diplomate ACVIM**
Lisa.Carioto@sonopath.com