


PATIENT

Chi Rubinetti

SPECIES

Canine

BREED

Chihuahua

SEX

Intact Male

AGE

12 Years 9 Months

WEIGHT

N/A

PRESENTING CLINICAL SIGNS

History: Grade VI/VI murmur, VHS 12.4, generalized cardiomegaly on rads. (stage B1 or B2 likely) MVD. Current meds: Vetmedin 1.25mg 1/2 T bid and Baytril 22.7mg/ml -0.6ml sid x 3 wks started 6/14/22,

ULTRASONOGRAPHIC EXAMINATION OF THE HEART

CANINE CARDIAC PARAMETERS	MR VMAX (m/s)	TR VMAX (m/s)	LA/AO (Boon method)	LA/AO (Heart Base; Swe)	FS (%)	EF (%)	EPSS (cm)
NORMAL PARAMETER	4.5-5.5	<2.7	1.3	<1.3	28-40	40-100	<0.6
PATIENT	5.67	2.4	1.92	--	32	62	0.18
CANINE CARDIAC PARAMETERS	HR (BPM)	AV VMAX (m/s)	PV MAX (m/s)	BODY WEIGHT (kg)	LA 2D short axis Base view (cm)	LVIDd Avg; 2D and m-mode short axis (cm)	LVIDs Avg; 2D and m-mode short axis (cm)
NORMAL PARAMETER	50-100	0.7-1.7	0.7-1.6				
PATIENT	113	1.56	0.69	N/A	2.84	2.68	1.78

INTERPRETED BY

 Lisa Carioto, DVM,
 DVSc, Diplomate
 ACVIM

IMAGING PERFORMED BY

Shari Reffi, CVT

HOSPITAL NAME

ACC Flanders

REFERRING VET

Dr. Casulli

INVOICE

16222

DATE

6/21/22

Radiographs (thoracic)

Marked cardiomegaly (LV and LA) with pulmonary congestion and high index of suspicion of pulmonary edema

Right ventricular enlargement is also suspected

A peribronchiolar lung pattern is also present, which may be due to chronic bronchitis

Echocardiographic findings
Mitral valve

- Moderate (posterior leaflet) to severe (septal leaflet) myxomatous degeneration.
- Moderate (posterior leaflet) to severe (septal leaflet) prolapse.
- Marked mitral regurgitation.
- Marked left atrial enlargement
- Marked left auricular enlargement.
- Rounding of the interventricular septum, i.e. left ventricular enlargement is present
- Moderate increase of LA: Ao ratio
- LA normalized for BW (LAN) not available – weight not provided



PATIENT

Chi Rubinetti

- LVIDd normalized for BW (LVIDND) not available – weight not provided
- LVIDs normalized for BW (LVIDNs) not available – weight not provided

SPECIES

Canine

Aortic valve

- Very mild thickening of the leaflet, without signs of endocarditis
- Mild to moderate aortic insufficiency (2.73 m/s)

BREED

Chihuahua

Tricuspid valve

- Mild to moderate myxomatous degeneration of the tricuspid valve
- Mild prolapse of both leaflets.
- Mild tricuspid regurgitation.

SEX

Intact Male

- No right ventricular or atrial enlargement.

AGE

12 Years 9 Months

Pulmonic valve

- No abnormalities
- No pulmonary insufficiency.
- Main pulmonary artery within normal limits.
- Bifurcation of MPA: No abnormalities

WEIGHT

N/A

Other

INTERPRETED BY

Lisa Carioto, DVM,
DVSc, Diplomate
ACVIM

- No signs of pericardial or pleural effusion
- No evidence of pulmonary edema.
- No obvious signs of a mass.

IMAGING PERFORMED BY

Shari Reffi, CVT

ULTRASONOGRAPHIC FINDINGS

- Myxomatous degeneration of the mitral (mild to moderate) and tricuspid (mild to moderate) valves, ACVIM stage B2, with marked left atrial and left ventricular enlargement.

HOSPITAL NAME

ACC Flanders

- Chi's echocardiographic results meet the criteria from the EPIC study to begin treatment with pimobendan (Vetmedin) to help slow the progression of his heart disease.

REFERRING VET

Dr. Casulli

- Spironolactone is also suggested, providing his renal function is within normal limits (see below).

INTERPRETATION OF THE FINDINGS & FURTHER RECOMMENDATIONS

INVOICE

16222

Other suggestions/recommendations include:

- Evaluation of blood pressure

DATE

6/21/22

- pimobendan (Vetmedin) at 0.25-0.30 mg/kg PO every 12 hours. Ideally, the dose should be started at 0.10 mg/kg PO every 12 hours for 3 days prior to increasing to the full dose to



PATIENT

Chi Rubinetti

decrease the risk of GI side effects. Administer with a *small* amount of food to decrease nausea.

SPECIES

Canine

- spironolactone (0.5-1 mg/kg twice a day) has anti-fibrotic effects. This may be started approximately 5-7 days after initiation of pimobendan, i.e. ensure Chi is tolerating the pimobendan.

BREED

Chihuahua

- Monitoring of the resting (sleeping) respiratory rate (RRR) is highly recommended once a day. The RRR should NOT EXCEED 30 breaths per minute (bpm). If the respiratory rate is greater than 30 bpm, or if there is a gradual increase (over a day or two) toward 30 bpm, the patient should be evaluated immediately for congestive heart failure and the appropriate treatment initiated.

SEX

Intact Male

- Other clinical signs clients should monitor for include coughing (particularly at night), fatigue, lethargy, decreased exercise tolerance (i.e., not being able to walk for as long before becoming tired, or “running out of breath” while playing, or going up and down stairs, as well as syncope (collapsing or fainting spells). Restlessness, or agitation during the night, or being unable to find a comfortable position to sleep are also very common clinical signs.

AGE

12 Years 9 Months

- Moderate salt restriction is suggested (between 0.4-0.5 grams/1000 kcal of food). Monitor salt content in treats.

WEIGHT

N/A

- Blood work PCV/TS, renal profile, SDMA and arterial blood pressure, are recommended 10-14 days after initiation of spironolactone.

INTERPRETED BY

Lisa Carioto, DVM,
DVSc, Diplomate
ACVIM

- Monitoring for progression of heart disease with a re-evaluation of an echocardiogram every 6 to 8 months, or sooner if clinical signs develop, is recommended.

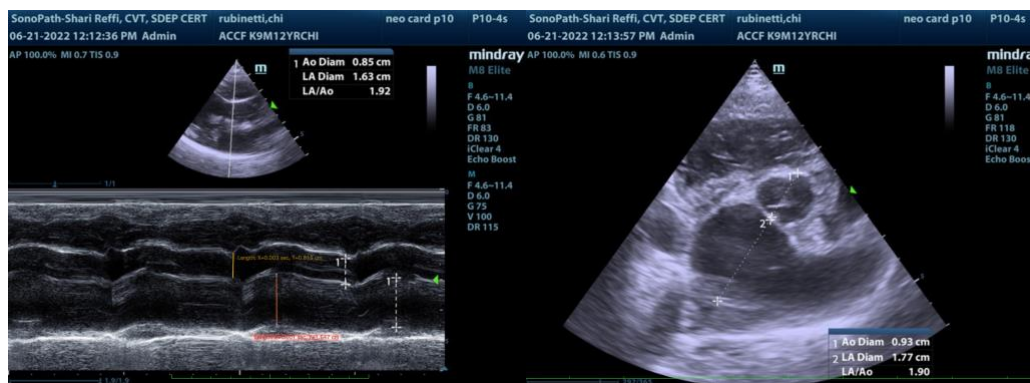
- One should consider sending Chi home with *furosemide in case of an emergency* (1-2 mg/kg PO q12h until able to contact a veterinarian).

IMAGING PERFORMED BY

Shari Reffi, CVT

HOSPITAL NAME

ACC Flanders



REFERRING VET

Dr. Casulli

INVOICE

16222

DATE

6/21/22



PATIENT

Chi Rubinetti

SPECIES

Canine

BREED

Chihuahua

SEX

Intact Male

AGE

12 Years 9 Months

WEIGHT

N/A

INTERPRETED BY

Lisa Carioto, DVM,
DVSc, Diplomate
ACVIM

**IMAGING
PERFORMED BY**

Shari Reffi, CVT

HOSPITAL NAME

ACC Flanders

REFERRING VET

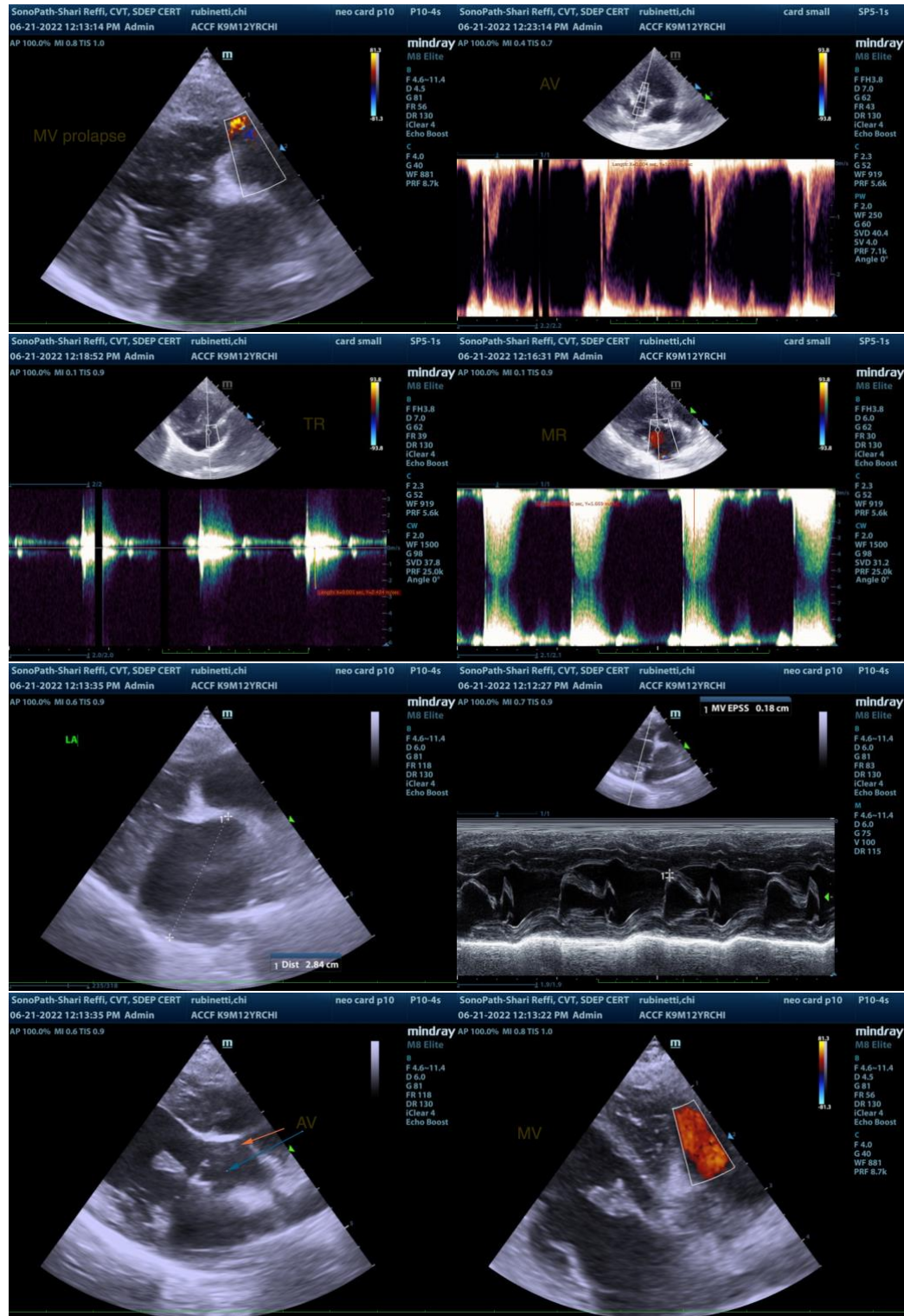
Dr. Casulli

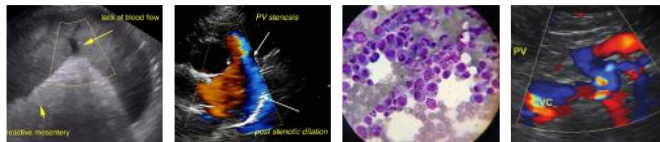
INVOICE

16222

DATE

6/21/22





PATIENT

Chi Rubinetti

SPECIES

Canine

BREED

Chihuahua

SEX

Intact Male

AGE

12 Years 9 Months

WEIGHT

N/A

INTERPRETED BY

Lisa Carioto, DVM,
DVSc, Diplomate
ACVIM

**IMAGING
PERFORMED BY**

Shari Reffi, CVT

HOSPITAL NAME

ACC Flanders

REFERRING VET

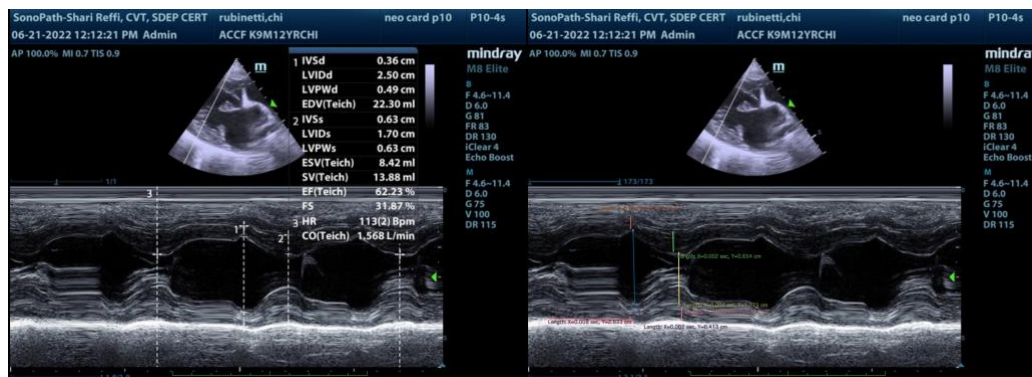
Dr. Casulli

INVOICE

16222

DATE

6/21/22



The information and recommendations provided are based on the images presented by the referring veterinarian/sonographer. No evaluation can be communicated regarding pathology that was not visible in the image/video clips provided.

Thank you for this referral. If the clinical or image interpretation does not parallel your findings or if I can be of any further assistance please contact me.

Lisa Carioto, DVM, DVSc, Diplomate ACVIM

Lisa.Carioto@sonopath.com