



**PATIENT**

Winston Fuqua

**SPECIES**

Canine

**BREED**

Scottish Terrier

**SEX**

Neutered Male

**AGE**

10 Years

**WEIGHT**

21 Pounds

**INTERPRETED BY**

Lisa Carioto, DVM,  
DVSc, Diplomate  
ACVIM

**IMAGING  
PERFORMED BY**

Emily Kirk

**HOSPITAL NAME**

Shiloh AH

**REFERRING VET**

Dr. Shana Silverstein

**INVOICE**

16185

**DATE**

6/17/22

**PRESENTING CLINICAL SIGNS**

History: Asymptomatic. Hx of previous elevated liver enzymes that resolved with unknown "natural product. currently working up liver enzyme elevations and microscopic hematuria. Due to the breed, want to confirm no signs of abnormalities in bladder wall, prostate, etc.

Abnormal PE/Chem/CBC/UA Results: Labs were wnl last year, and dog currently has mild/mod liver enz elevations (ALT 314, ALP 388). Senior screenings also noted a UPC of 1.6 and microscopic hematuria on free catch sample + 3 epith cells.

**ULTRASONOGRAPHIC EXAMINATION OF THE ABDOMEN**

**Urinary System**

The **urinary bladder** is adequately, but not fully distended. It is difficult to evaluate wall thickness as a result, i.e., it is mildly thickened at the apex and ventral wall and very mildly irregular. This may be due to the bladder not being well distended, however, an underlying cystitis cannot be excluded. No abnormalities are noted with the trigone or proximal urethra, and there is no evidence of sediment, cystoliths, polyps or a mass. The contents of the urinary bladder are anechoic.

**Prostate**

The **prostate** is homogenous and within normal limits for a neutered male.

**Kidneys**

The **left** kidney measures 5.03 cm. The capsule is smooth. The cortex is mildly hyperechoic (i.e., it is isoechoic to the spleen). A very mild loss of the normal definition of the cortico-medullary junction is present. Very small mineralizations of the diverticulae and pelvis are present, without evidence of nephroliths or pyelectasia. The surrounding mesentery is not hyperechoic.

The **right** kidney measures 4.96 cm. The cortex is mildly hyperechoic. A thin hyperechoic band is observed along the medulla, traversing parallel to the corticomedullary junction, which accentuates the definition of the cortico-medullary junction. Mineralizations of the diverticulae and pelvis are present, without evidence of nephroliths or pyelectasia. There are more mineralizations within the pelvis compared to the left kidney. The surrounding mesentery is not hyperechoic.

**Aortic bifurcation/trifurcation**

No abnormalities observed.

**Adrenal Glands**

The **left** adrenal gland measures 0.32 cm at the cranial pole, 0.34 cm at the caudal pole and 1.13 cm in length. No abnormalities are noted with the gland's overall architecture, echogenicity or echotexture. The phrenico-abdominal vein and surrounding vasculature and mesentery are unremarkable.

The **right** adrenal gland measures 0.44 cm in diameter. No abnormalities are noted with echogenicity or echotexture. The phrenico-abdominal vein and surrounding vasculature and mesentery are unremarkable.

**Spleen**

Subjectively, the spleen may be mildly enlarged, however, it is within normal limits in architecture, echotexture, and echogenicity. The capsule is smooth. No abnormalities are observed with its vasculature, i.e. congestion and thrombi are not identified.



**PATIENT**

**Liver**

Winston Fuqua

Mild to moderate hepatomegaly is suspected, however, this is better characterized at the time of the ultrasound or with radiographs. The liver is diffusely hyperechoic, i.e. it is hyperechoic to the falciform fat and isoechoic to the spleen). It has a diffuse, mildly coarse/granular echotexture.

**SPECIES**

Canine

The walls of the portal veins are more prominent than usual, which may be caused by inflammation. Perivascular cuffing surrounding some of the hepatic vessels is observed, which may be due to deposition of fat, inflammatory cells, mineralization and/or fibrosis.

**BREED**

Scottish Terrier

A hypoechoic nodule measuring 0.58 cm in diameter x 0.64 cm in length is noted subcapsularly. It does not disrupt the integrity of the capsule. A second hypoechoic nodule is noted adjacent to a blood vessel.

**SEX**

Neutered Male

The gallbladder (GB) is moderately distended with a moderate amount of free floating, gravity-dependent and inspissated echogenic material. The GB wall is within normal limits in thickness and echogenicity. The portions of the cystic and/or common bile ducts observed are not dilated or tortuous, i.e. there are no signs of an obstruction. The parenchyma surrounding the GB is hyperechoic.

**AGE**

10 Years

**Gastrointestinal**

The gastric wall is within normal limits in thickness and the wall layers are well defined. No obvious abnormalities are observed with its peristalsis.

**WEIGHT**

21 Pounds

The small intestinal wall thickness, including the duodenum (0.43 cm), is within normal limits and the definition of the wall layers is preserved. None of the intestines in the region of the mesenteric root (see below) are thickened or show abnormal peristalsis.

**INTERPRETED BY**

Lisa Carioto, DVM,  
DVSc, Diplomate  
ACVIM

Segments of jejunum in the caudal abdomen, cranial to the urinary bladder, have a mildly prominent mucosa.

Abnormally dilated loops of bowel are not observed.

The colonic wall is not thickened and mural detail is considered normal. Semi-formed stools present within the descending colon.

**IMAGING PERFORMED BY**

Emily Kirk

There are no obvious signs of a mass, foreign body, or an obstruction in the gastrointestinal tract.

**Pancreas**

**HOSPITAL NAME**

Shiloh AH

The right limb has a mildly coarse echotexture, and is mildly heterogeneous. Multiple pinpoint to punctate hyperechoic foci are scattered throughout the parenchyma. These changes are suggestive of fibrosis, which may be an age-related change, secondary to previous episodes of pancreatitis, mineralization and/or amyloid deposition. Signs of active pancreatitis or neoplasia are not appreciated.

**REFERRING VET**

Dr. Shana Silverstein

No overt abnormalities are observed with the echogenicity or echotexture of the left limb, however, an in-depth evaluation is not possible due to gas in the surrounding gastrointestinal tract.

**Other**

**INVOICE**

**Lymph nodes**

16185

Inguinal lymph nodes: WNL

**DATE**

6/17/22



**PATIENT**

Winston Fuqua

Mesenteric lymph nodes in the left cranial to mid abdomen are enlarged, hypoechoic and have mildly irregular borders. The surrounding mesentery is markedly hyperechoic surrounding the lymph nodes, as well as the gastrointestinal tract along the entire region.

**SPECIES**

Canine

Lymph nodes:

0.82 cm in diameter x 1.35 cm in length

0.92 cm in diameter x 1.21 cm in length

**BREED**

Scottish Terrier

0.74 cm in diameter x 2.16 cm in length

**Abdominal effusion**

A scant amount of anechoic fluid is visualized between two loops of jejunum in the caudal abdomen.

**SEX**

Neutered Male

**ULTRASONOGRAPHIC FINDINGS**

**AGE**

10 Years

- **Lymph nodes and hyperechoic mesentery in cranial to mid left abdomen:** Lymphadenomegaly of multiple mesenteric lymph nodes and a possible jejunal lymph node may be due to reactive hyperplasia, or an inflammatory response due to an infectious disease. However, one cannot exclude occult or "emerging" neoplasia, such as lymphoma or other round cell tumour. Evaluation of Winston's diet is suggested (see below).

**WEIGHT**

21 Pounds

- **Liver:** Hepatitis cannot be excluded, for example, primary (immune-mediated) or secondary (toxins, including medications and natural supplements, infectious agents (parasites, viruses, or bacteria). Benign, age-related nodular hyperplasia is also suspected. Cholestasis, cholangitis/cholangiohepatitis and cholecystitis remain possible differential diagnoses.

**INTERPRETED BY**

Lisa Carioto, DVM,  
DVSc, Diplomate  
ACVIM

- **Gallbladder:** Gallbladder sludge is often clinically insignificant, however, gastroesophageal reflux disease (GERD), can occur in some patients. Obtaining a history regarding signs of GERD from the client is suggested. Treatment with an anti-acid, proton pump inhibitor or ursodeoxycholic acid may be required. The latter may also help decrease hepatic inflammation.

**IMAGING PERFORMED BY**

Emily Kirk

- **Urinary bladder:** A few white blood cells and a number of red blood cells and epithelial cells were present on the most recent urinalysis, which could account for the positive urine protein:creatinine ratio.

**HOSPITAL NAME**

Shiloh AH

- **Kidneys:** Mild age-related degeneration are present. Pyelonephritis is less likely, but cannot be excluded, despite the absence of classical sonographic signs.

**REFERRING VET**

Dr. Shana Silverstein

- **Pancreas:** Age related changes are suspected, including fibrosis, which may occur due to previous episodes of pancreatitis. There are no obvious signs of pancreatitis or neoplasia. Note, an in-depth evaluation of the left limb was not possible (gas in surrounding GI tract).

**INVOICE**

16185

- **Spleen:** The splenomegaly may in fact be present based on the lymphadenomegaly and hyperechoic mesentery observed. Splenitis or reactive hyperplasia are possible differential diagnoses, as is occult neoplasia, such as lymphoma or other round cell tumour.

**DATE**

6/17/22

- **Gastrointestinal tract:** an inflammatory process, such as inflammatory bowel disease or an infectious gastroenteritis may be present, despite the absence of sonographic abnormalities. An evaluation of Winston's diet for example, a raw meat diet is suggested, to exclude underlying *Clostridium*, *Campylobacter*, *E. coli*, or *Salmonella*.



**PATIENT**

Winston Fuqua

- Abdominal effusion due to increased permeability, for example. There are no signs of an obstruction.

**SPECIES**

Canine

**BREED**

Scottish Terrier

**SEX**

Neutered Male

**AGE**

10 Years

**WEIGHT**

21 Pounds

**INTERPRETED BY**

Lisa Carioto, DVM,  
DVSc, Diplomate  
ACVIM

**IMAGING PERFORMED BY**

Emily Kirk

**HOSPITAL NAME**

Shiloh AH

**REFERRING VET**

Dr. Shana Silverstein

**INVOICE**

16185

**DATE**

6/17/22

**INTERPRETATION OF THE FINDINGS & FURTHER RECOMMENDATIONS**

The following are suggested suggested/recommended

Evaluation of Winston's diet for example, a raw meat diet is suggested, to exclude underlying *Clostridium*, *Campylobacter*, *E. coli*, or *Salmonella*.

Obtaining a history regarding signs of GERD from the client is suggested. Treatment with an anti-acid, proton pump inhibitor or ursodeoxycholic acid may be required.

Review possible toxins, including medications and natural supplements, infectious agents (hunting, travel, etc.).

Winston's total calcium on the serum biochemical profile is at the high end of the normal reference range.

A deep palpation of Winston's peripheral lymph nodes.

A rectal exam, including the anal sacs, pre and post expressing of the anal sacs.

A urine culture and sensitivity

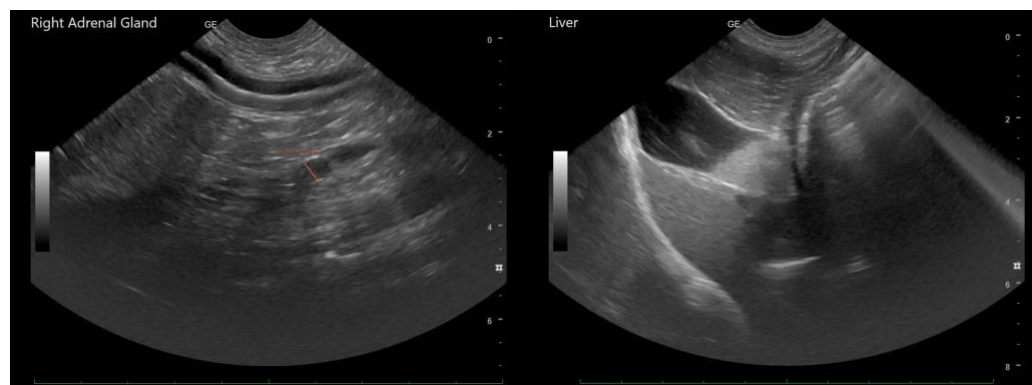
Deworm, even if already receiving monthly heartworm prevention

Fine needle aspirates of the lymph nodes, spleen and liver, pending coagulation panel

+/- culture of liver and bile

+/- hepatic biopsy, pending coagulation panel

Further diagnostics will depend on some of the answers obtained after re-assessing the history.





**PATIENT**

Winston Fuqua

**SPECIES**

Canine

**BREED**

Scottish Terrier

**SEX**

Neutered Male

**AGE**

10 Years

**WEIGHT**

21 Pounds

**INTERPRETED BY**

Lisa Carioto, DVM,  
DVSc, Diplomate  
ACVIM

**IMAGING  
PERFORMED BY**

Emily Kirk

**HOSPITAL NAME**

Shiloh AH

**REFERRING VET**

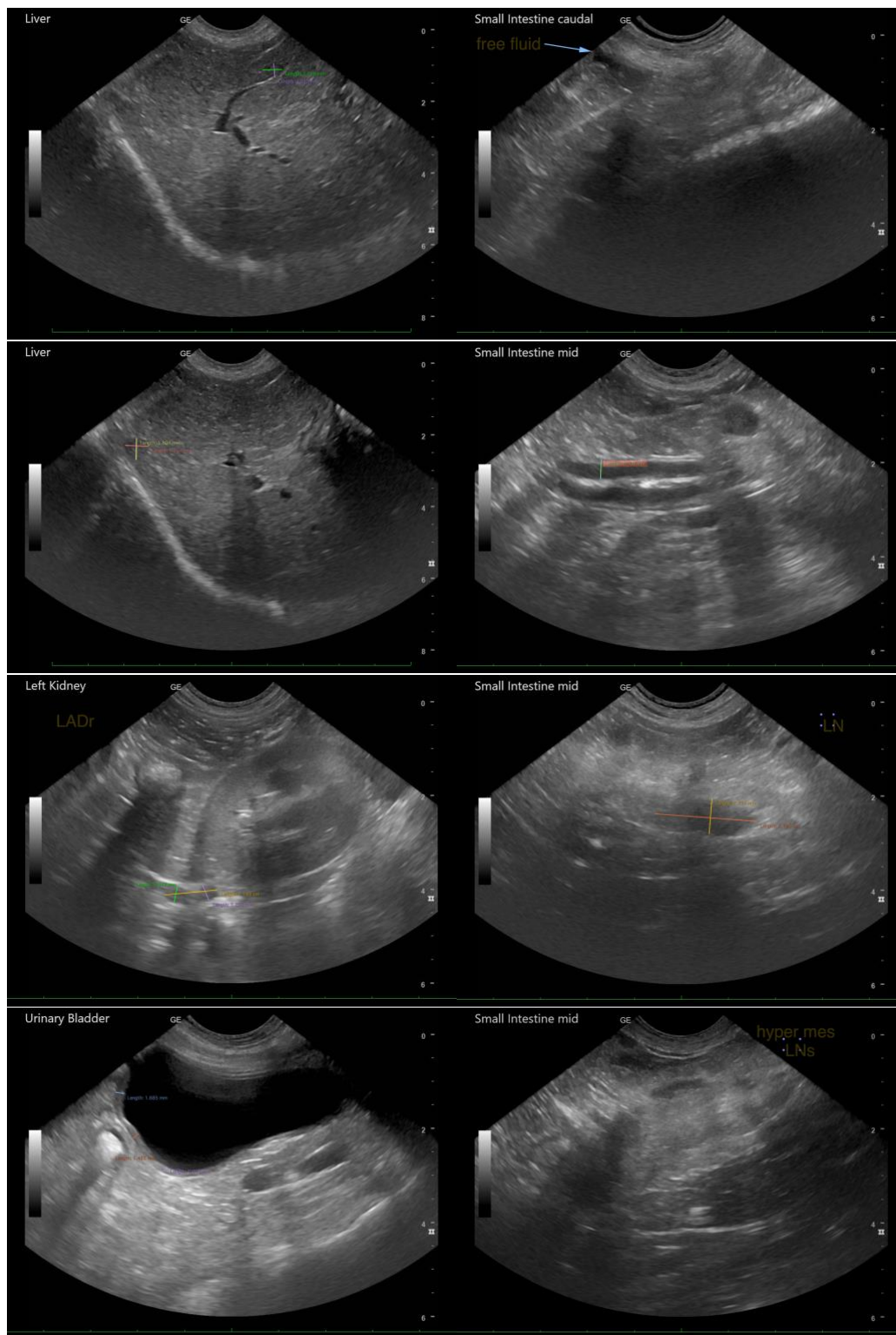
Dr. Shana Silverstein

**INVOICE**

16185

**DATE**

6/17/22





**PATIENT**

Winston Fuqua

**SPECIES**

Canine

**BREED**

Scottish Terrier

**SEX**

Neutered Male

**AGE**

10 Years

**WEIGHT**

21 Pounds

**INTERPRETED BY**

Lisa Carioto, DVM,  
DVSc, Diplomate  
ACVIM

**IMAGING  
PERFORMED BY**

Emily Kirk

**HOSPITAL NAME**

Shiloh AH

**REFERRING VET**

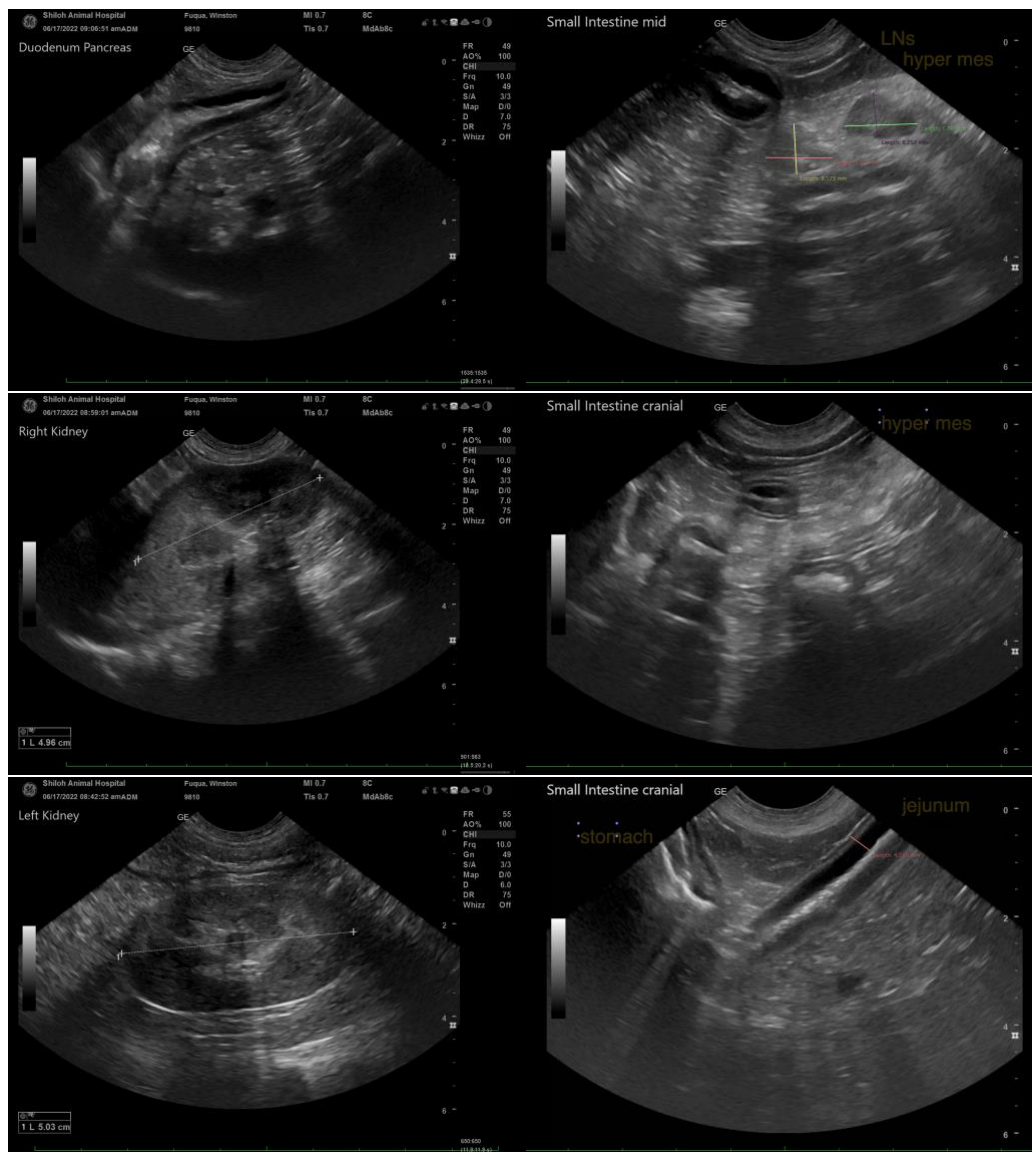
Dr. Shana Silverstein

**INVOICE**

16185

**DATE**

6/17/22



The information and recommendations provided are based on the images presented by the referring veterinarian/sonographer. No evaluation can be communicated regarding pathology that was not visible in the image/video clips provided.

Thank you for this referral. If the clinical or image interpretation does not parallel your findings or if I can be of any further assistance please contact me.

**Lisa Carioto, DVM, DVSc, Diplomate ACVIM**

[Lisa.Carioto@sonopath.com](mailto:Lisa.Carioto@sonopath.com)