

**DATE**

6/14/22

**PRESENTING CLINICAL SIGNS**

Inappetent since 6/10/22. No vomiting or diarrhea. More lethargic than normal. PE: T 102.7. Heart and lungs auscult wnl. Abdomen palpates tense and non-painful.

Current Medications: 6/13/22 administered Cerenia 1mg/kg SQ and Dex SP (0.25mg/kg) IV.

**PATIENT**

Gracie Pie

Lab Results: 6/13/22 CBC: Mild normocytic, normochromic regenerative anemia (HCT 34.3%) Severe thrombocytopenia 55K/uL. Bloodsmear revealed manual platelet count of 50,000. Chemistry: Mild hypocholesteremia 84mg/dL

Date of Previous IntraPet Ultrasound: No previous.

Sedation: Patient sedated with Dexdomitor.

**SPECIES**

Canine

Stat Report: Not requested.

Imaging Performed By: Andi Parkinson, BS, RDMS.

**BREED**

Border Collie

**ULTRASONOGRAPHIC EXAMINATION OF THE ABDOMEN****SEX**

Spayed Female

**Urinary System**

The urinary bladder is well distended with anechoic contents. The wall is smooth and regular. No abnormalities are noted with the trigone or proximal urethra, and there is no evidence of sediment, cystoliths, polyps or a mass.

**AGE**

3/9/15

**Kidneys**

The **left** kidney measures 7.25 cm. The capsule is smooth. It is slightly hyperechoic, but remains hypoechoic to the spleen. Its overall architecture, including the definition of the cortico-medullary junction, is preserved. There are no signs of nephroliths or pyelectasia. Blood flow is within normal limits, although, subjectively it may be slightly increased. An accumulation of intrapelvic fat is observed. The surrounding mesentery is not hyperechoic.

**WEIGHT**

69.4 lbs

The **right** kidney measures 7.59 cm. The capsule is smooth. A mild hyperechogenicity of the renal cortex is present, i.e. it is isoechoic to the liver, which is also considered hyperechoic. Its overall architecture, including the definition of the cortico-medullary junction, is preserved. Mild mineralization of the diverticulae and pelvis is present, without signs of nephroliths or pyelectasia. Renal blood flow is not observed. The surrounding mesentery is not hyperechoic.

**INTERPRETED BY**

Lisa Carioto, DVM,  
DVSc, Diplomate  
ACVIM

**Aortic bifurcation/trifurcation**

No abnormalities observed.

**HOSPITAL NAME**

Timonium AH

**Adrenal Glands**

The **left** adrenal gland measures 0.66 cm at the cranial pole, 0.57 cm at the caudal pole and 2.35 cm in length. No abnormalities are noted with the gland's overall architecture, echogenicity or echotexture. The phrenico-abdominal vein and surrounding vasculature and mesentery are unremarkable.

**REFERRING VET**

Dr. Falkowski

The **right** adrenal gland measures 0.64 cm at the cranial pole, 0.67 cm at the caudal pole and 2.81 cm in length. No abnormalities are noted with the gland's overall architecture, echogenicity or echotexture. The phrenico-abdominal vein and surrounding vasculature and mesentery are unremarkable.

**INVOICE**

31016

**Spleen**

Mild splenomegaly with a smooth capsule. The spleen is within normal limits in architecture, and echogenicity, however, a diffuse miliary echotexture is observed. Focal lesions are not visualized. No abnormalities are observed with its vasculature, i.e. congestion and thrombi are not identified.

**Liver**

There are no obvious signs of hepatomegaly. The liver's borders are smooth, but mildly rounded. It is mildly, but diffusely hyperechoic, and a diffuse, mildly coarse or granular echotexture is observed. The liver and cortex of the right kidney are isoechoic. Focal lesions are not observed. No obvious abnormalities are noted with the hepatic vessels.

The gallbladder (GB) is moderately distended with a moderate amount of free floating and inspissated echogenic material, some of which forms nodules. The GB wall is within normal limits in thickness and echogenicity. The portions of the cystic and/or common bile ducts observed are not dilated or tortuous, i.e. there are no signs of an obstruction. The parenchyma surrounding the GB is not hyperechoic.

### **Gastrointestinal**

A large amount of ingesta is present within the stomach (ate rice at 7 pm). The gastric wall is within normal limits in thickness and the wall layers are well defined. No obvious abnormalities are observed with its peristalsis.

Duodenum: Gas and fluid are present

The small intestinal wall thickness, including the duodenum, is within normal limits and the definition of the wall layers is preserved. Fluid, gas and ingesta are present in the jejunal loops, however, abnormally dilated loops of bowel are not observed. No abnormalities are observed with the ileo-cecal-colic junction.

The colonic wall is not thickened and mural detail is considered normal.

There are no obvious signs of a mass, foreign body, infiltrative disease or an obstruction in the gastrointestinal tract.

### **Pancreas**

No overt abnormalities are observed with the architecture, contours, echogenicity or echotexture of the **left** pancreas. There is no evidence of hyperechogenicity of the surrounding mesentery, i.e., signs of active pancreatitis are not present.

The **right** pancreas has a mildly coarse echotexture. Pinpoint to punctate hyperechoic foci scattered throughout the parenchyma are observed, which are suggestive of fibrosis. The latter may be an age-related change, secondary to previous episodes of pancreatitis, mineralization and amyloid deposition. Signs of active pancreatitis or neoplasia are not appreciated.

### **Other**

#### **Lymph nodes**

No abnormalities are observed

**Abdominal effusion** is not visualized.

### **ULTRASONOGRAPHIC FINDINGS**

- **Spleen:** *Splenomegaly* secondary to anemia, i.e. *extramedullary hematopoiesis (EMH)*. Other differential diagnoses include splenitis due to antigenic stimulation, including immune mediated induced inflammation, as well as infectious diseases. Hypersplenism and reactive hyperplasia cannot be excluded. Neoplasia, such as lymphoma or other round cell tumour, is considered highly unlikely, but cannot be excluded. A fine needle aspirate would be required to obtain a definitive diagnosis, but is not recommended for the moment due to the platelet count.

- **Gallbladder:** *Gallbladder sludge* is often clinically insignificant, however, gastroesophageal reflux disease (GERD), can occur in some patients. Obtaining a history regarding signs of GERD from the client is suggested. Treatment with an anti-acid, proton pump inhibitor or ursodeoxycholic acid may be required. Sonographic signs of cholecystitis are not appreciated.
- **Liver:** *Vacuolar and reactive hepatopathies* are suspected. A vacuolar hepatopathy may occur due to stress, including chronic illness. Other diseases, such as cholangitis/cholangiohepatitis are considered much less likely.
- **Kidneys:** mild hyperechogenicity of the renal cortices, i.e. possible glomerulonephritis. No obvious signs of pyelonephritis. Systemic hypertension cannot be excluded.
- **Pancreas:** Age-related changes, including fibrosis. There are no signs of active pancreatitis or neoplasia.
- **Gastrointestinal tract:** No abnormalities. Food within the stomach due to recent consumption of rice.

#### **INTERPRETATION OF THE FINDINGS & FURTHER RECOMMENDATIONS**

*Immune-mediated thrombocytopenia* is the most likely diagnosis. An infectious cause cannot be excluded.

The following are suggested/recommended  
urinalysis and urine culture and sensitivity to complete the minimum data base

If negative, a urine protein: creatinine ratio to exclude proteinuria.

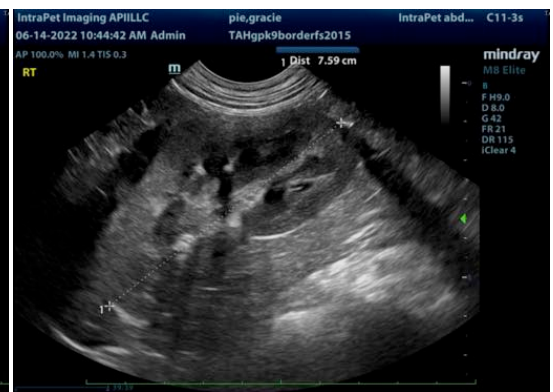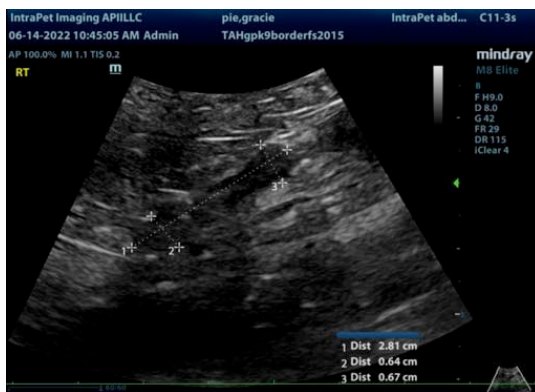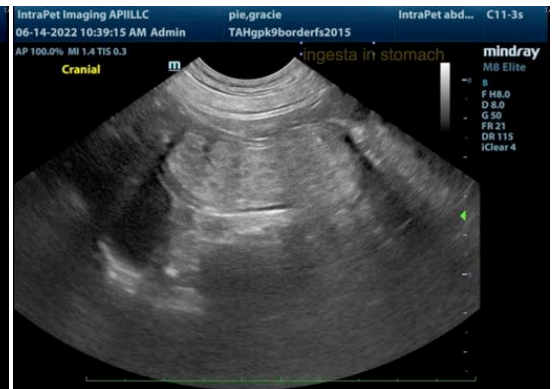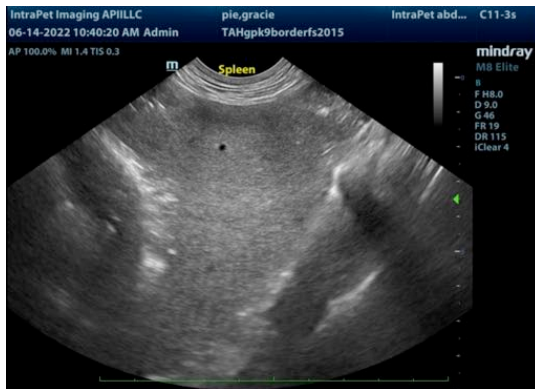
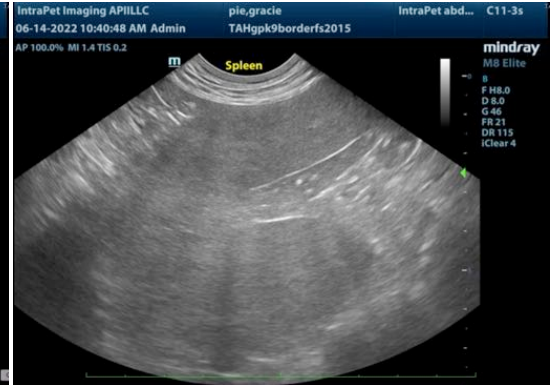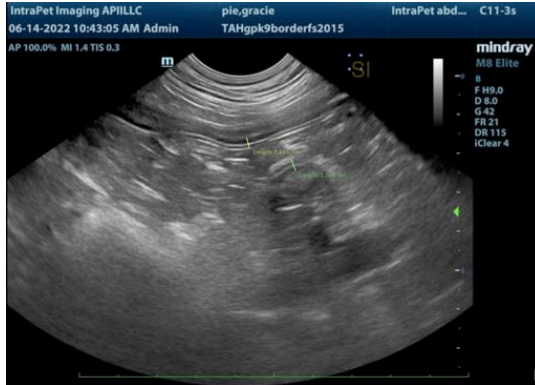
Arterial blood pressure to exclude hypertension

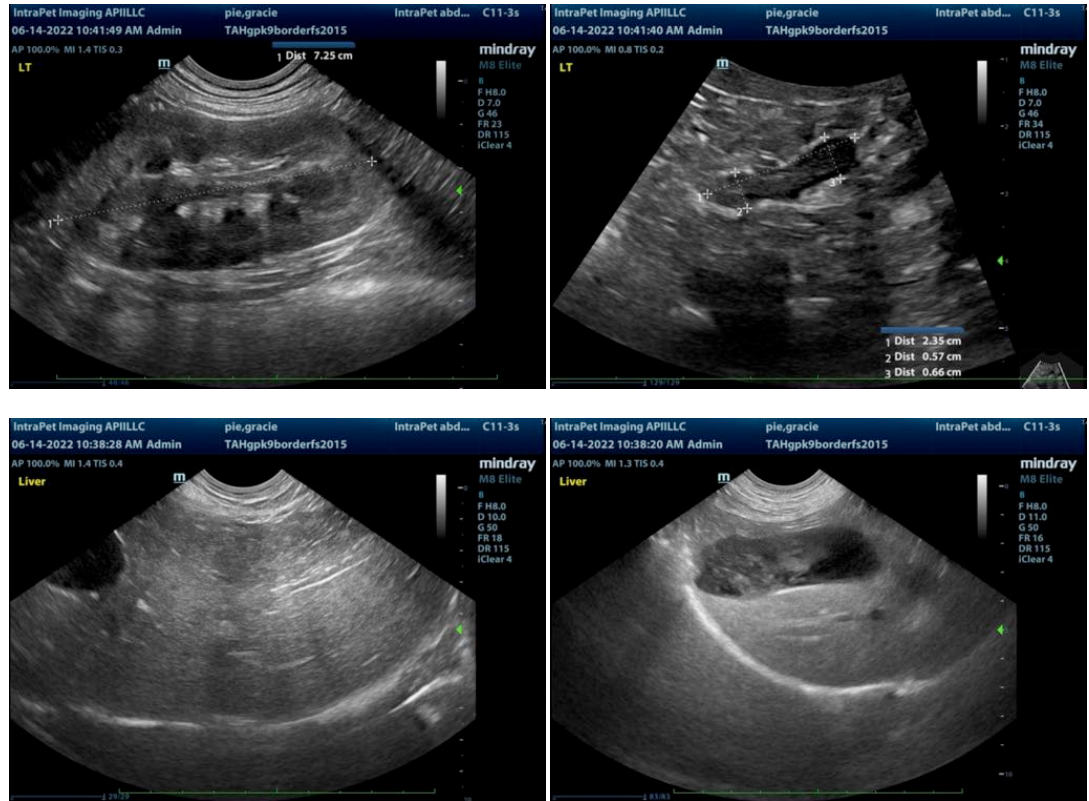
SNAP 4Dx (or equivalent test)

*Leptospira* spp. PCR, providing beta-lactamase and penicillin antibiotics not administered in last 2 months  
+/- PCR for vector borne diseases, including *Bartonella* spp.

If no improvement, a fine needle aspirate of the spleen may be considered (depending on platelet count).  
However, neoplasia is considered highly unlikely based on its current appearance. That is, EMH is the most likely cause.

Although much less likely, it is suggested to put aside serum or, if finances are not a concern, perform a baseline cortisol, to exclude hypoadrenocorticism, as this disease can present in many different ways.





The information and recommendations provided are based on the images presented by the referring veterinarian. No evaluation can be communicated regarding pathology that was not visible in the image/video clips provided.

Thank you for this referral. If the clinical or image interpretation does not parallel your findings or if I can be of any further assistance please contact me.

Lisa Carioto, DVM, DVSc, Diplomate ACVIM  
[Lisa.Carioto@sonopath.com](mailto:Lisa.Carioto@sonopath.com)