

**DATE**

6/13/22

PRESENTING CLINICAL SIGNS

Hx of chronic vomiting since Fall 2020. Was seen at another veterinary hospital that noted some thickening of intestines on ultrasound. Seen at Everhart in Fall 2021 - nsf on labs and started on Hills z/d. Still having episodes of vomiting. Will go 1 week at longest without vomiting. Stools are softer and more malodorous since starting hills z/d.

PATIENT

Buddy Schultz

Current Medications: none but currently on hills z/d.

Lab Results: nsf on labs from Nov 2021.

Date of Previous IntraPet Ultrasound: No previous.

Sedation: Not required to complete full diagnostic ultrasound.

Stat Report: Not requested.

Imaging Performed By: Stephanie Pearce RDCS, RVT.

SPECIES

Feline

BREED

Domestic Shorthair

ULTRASONOGRAPHIC EXAMINATION OF THE ABDOMEN**SEX**

Neutered male

Urinary System

The **urinary bladder** is well distended. The wall is smooth and regular. No abnormalities are present with the trigone or proximal urethra. A large amount of sediment is present, however, there is no evidence of cystoliths, polyps or a mass.

AGE

11/15/14

Kidneys

The **left kidney** measures 3.65 cm (3.80-4.40 cm), decreased in size. The capsule is smooth. The cortex is hyperechoic, i.e. it is hyperechoic to the spleen. The definition of the cortico-medullary junction is preserved. There is no evidence of mineralization, nephroliths or pyelectasia. Blood flow is within normal limits. The surrounding mesentery is not hyperechoic.

WEIGHT

13.6 lbs

The **right kidney** measures 4.85 cm (3.80-4.40 cm). The capsule is smooth. The cortex is hyperechoic, i.e. it is hyperechoic to the liver. The definition of the cortico-medullary junction is preserved. Mild mineralization of the pelvis is present. There is no evidence of nephroliths or pyelectasia. Blood flow is within normal limits. The surrounding mesentery is not hyperechoic.

INTERPRETED BY

Lisa Carioto, DVM,
DVSc, Diplomate
ACVIM

Aortic bifurcation/trifurcation

No abnormalities observed.

HOSPITAL NAME

Everhart Wellpet

Adrenal Glands

The **left adrenal gland** measures 0.45 cm. No abnormalities are noted with the gland's overall architecture, echogenicity or echotexture. The phrenico-abdominal vein and surrounding vasculature and mesentery are unremarkable.

REFERRING VET

Dr. Betta

The **right adrenal gland** measures 0.38 cm. No abnormalities are noted with the gland's overall architecture, echogenicity or echotexture. The phrenico-abdominal vein and surrounding vasculature and mesentery are unremarkable.

INVOICE

30972

Spleen

The spleen is within normal limits in size 6.3 mm (normal = 10 mm), echotexture, and echogenicity. The capsule is smooth. No abnormalities are observed with its vasculature, i.e. congestion and thrombi are not identified.

Liver

There are no obvious signs of hepatomegaly. The liver's borders are smooth and sharp. It is homogeneous and within normal limits in echogenicity for the most part, however it is isoechoic to the falciform fat in other angles. No focal lesions are visualized. The walls of the portal veins are slightly more prominent than usual. The hepatic veins are within normal limits.

The gallbladder (GB) wall is within normal limits in thickness and echogenicity. A moderate amount of inspissated and free floating echogenic material is present within the GB. The portions of the cystic and/or common bile ducts observed are not dilated or tortuous, i.e. there are no signs of an obstruction.

Gastrointestinal

The gastric wall is very mildly thickened focally (0.6 cm), in the area of the pylorus. The area shows moderate to severe fogging of the mucosa and muscularis. All three layers vary in thickness (WNL to thickened, i.e., mucosa, submucosa and muscularis,) depending on the location evaluated. No obvious abnormalities are observed with its peristalsis.

The small intestinal wall thickness is within normal limits and the definition of the wall layers is preserved. However, the mucosa and submucosa are more prominent than normal. Abnormally dilated loops of bowel are not observed. No abnormalities are noted with the ileocecal colic junction. The transverse colon is filled with gas.

The colonic wall is not thickened and mural detail is considered normal, however, the muscularis is more prominent. Formed stools and gas are present in the colon.

Pancreas

The **right limb** is not enlarged, but is hypoechoic. Its contours are smooth. The surrounding mesentery is mildly to moderately hyperechoic. Mild active or a smoldering pancreatitis is suspected.

No obvious abnormalities are observed with the architecture, contours, echogenicity or echotexture of the pancreas. There is no evidence of hyperechogenicity of the surrounding mesentery, i.e., signs of active pancreatitis are not present.

Other

Lymph nodes

Gastric lymph nodes are enlarged at 0.64 cm and 0.91 cm in diameter. They are mildly to moderately hypoechoic and the surrounding mesentery is mildly to moderately hyperechoic.

Abdominal effusion is not visualized.

ULTRASONOGRAPHIC FINDINGS

- **Gastrointestinal (GI) tract and lymphadenomegaly (gastric LNs):** Focal thickening of overall wall thickness and individual wall layers of the stomach may be suggestive of inflammation, secondary to *chronic vomiting*, and *inflammatory bowel disease (IBD)*. However, neoplasia, such as lymphoma, or other differentials causing focal neoplasms may include adenocarcinoma, leiomyosarcoma, or benign leiomyoma, cannot be excluded.

Lymphadenomegaly and *hyperechogenicity of the surrounding mesentery* may be due to either *reactive hyperplasia* due to chronic inflammation (vomiting), IBD or *infiltrative disease*.

- **Liver:** *Hepatic lipidosis* may be developing and causing the mild, yet localized, hyperechogenicity. However, *subclinical cholestasis, cholangitis/cholangiohepatitis* cannot be excluded.
- **Gallbladder:** Gallbladder **sludge** is often clinically insignificant, however, gastroesophageal reflux disease (GERD), can occur in some patients. Furthermore, (*suppurative*) *cholecystitis* cannot be excluded despite the absence of sonographic abnormalities. Obtaining a history regarding signs of GERD from the client is suggested. Treatment with an anti-acid, proton pump inhibitor or ursodeoxycholic acid may be required.
- **Pancreas: Right limb:** Overt signs of pancreatitis are not visualized, however, subtle changes are present that are suggestive of mild inflammation. Therefore, *smoldering pancreatitis or intermittent bouts of pancreatitis* should not be excluded.
- *Underlying, intermittent triaditis* cannot be excluded, due to the chronicity of Buddy's signs.
- **Kidneys:** The hyperechoic cortices may be compatible with *glomerulonephritis (GN) or interstitial nephritis (systemic inflammation)*. *Pyelonephritis* cannot be excluded, despite absence of classical sonographic signs.
- **Urinary bladder:** The debris is likely composed of mucus, crystalline material and exfoliated cells, however, *subclinical bacteriuria and pyelonephritis* cannot be excluded.

INTERPRETATION OF THE FINDINGS & FURTHER RECOMMENDATIONS

The following are suggested/recommended

Endoscopy and biopsies of the stomach, and both the small and large intestines, even if no history of diarrhea.

A urinalysis and urine culture and sensitivity to exclude pyelonephritis.

If negative, consider urine protein: creatinine ratio to exclude proteinuria due to GN.

+/- spec fPL

Analgesia (buprenorphine (0.005-0.01 mg/kg, sublingually, every 8-12 hours) with or without gabapentin.

Continue for 3-4 weeks, or longer, as needed.

Treatment of nausea

Small, frequent meals

+/- Supplementation with cobalamin

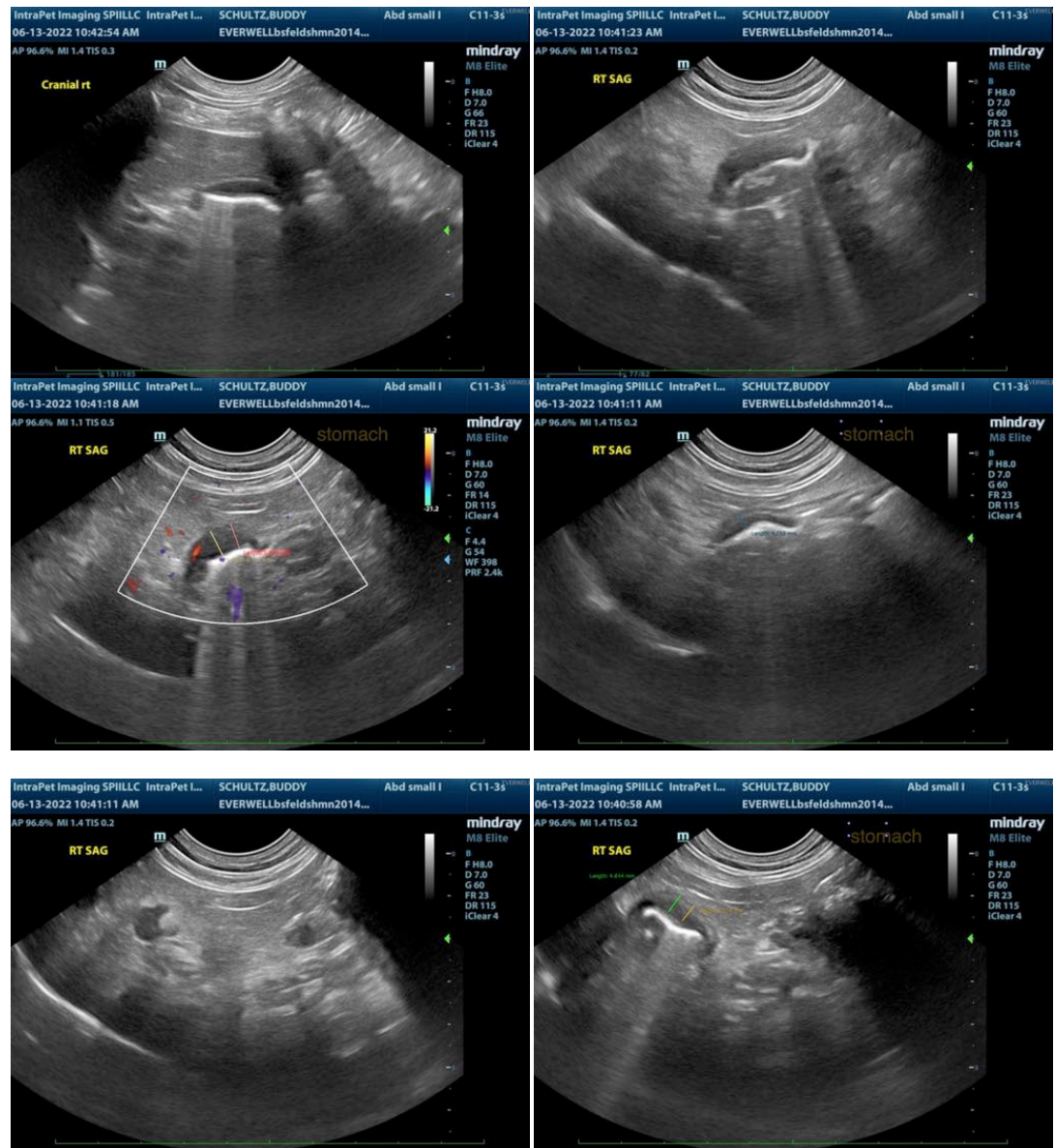
Obtaining a history regarding signs of GERD from the client is suggested. Treatment with an anti-acid or proton pump inhibitor, and possibly ursodeoxycholic acid, may be required depending on the history (famotidine or omeprazole (0.7-1 mg/kg PO q12h)). *Treatment with ursodeoxycholic acid is not recommended while Buddy is hyporexic or nauseous.*

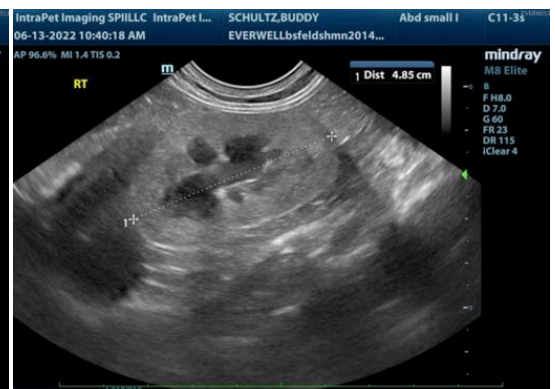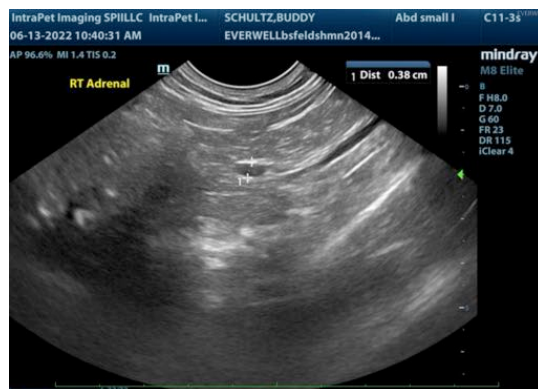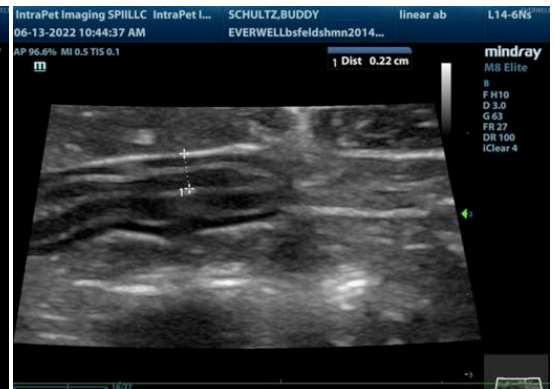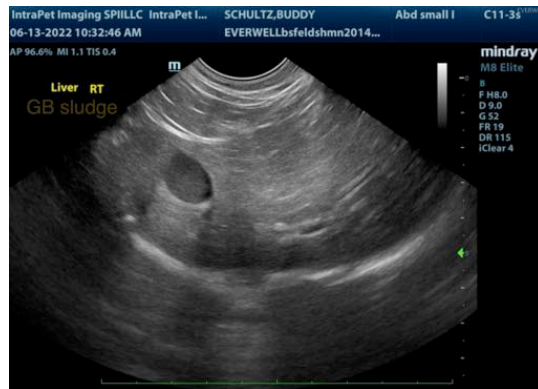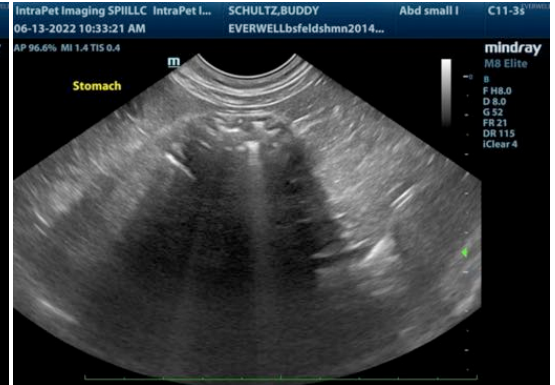
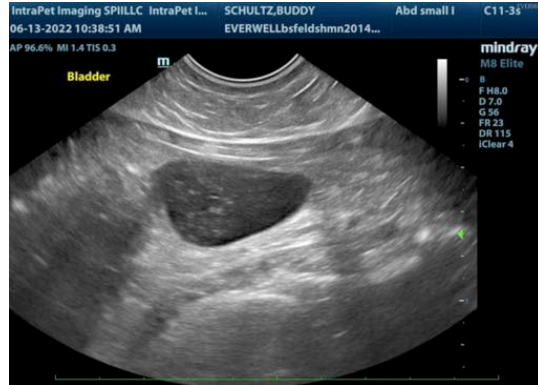Deworm (if he goes outdoors or lives with pets that go outdoors)

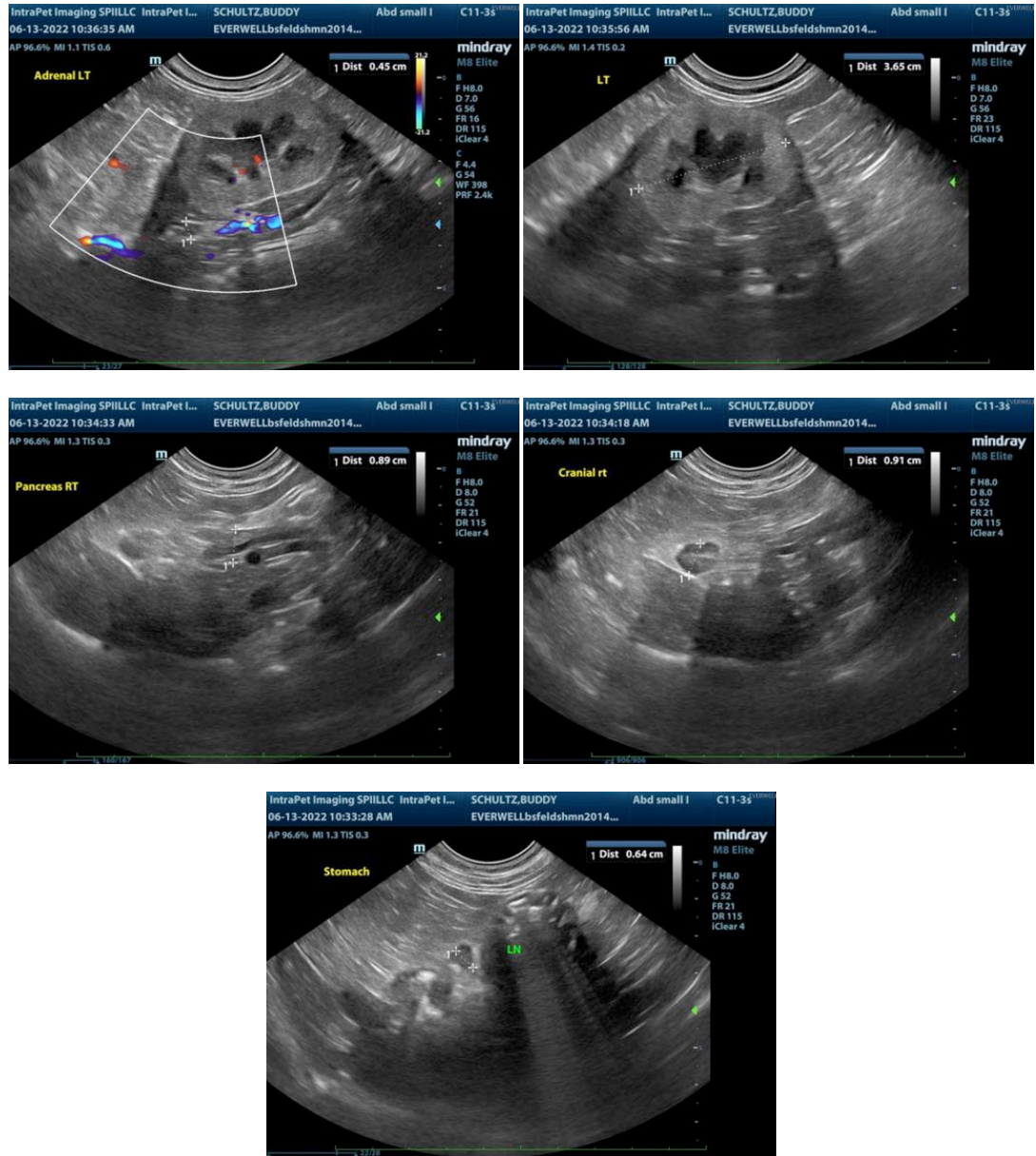
+/- diet change (he may not tolerate the z/d – dysbiosis, cramps, gas, malodorous stools). Monitor weight, body condition and muscle condition scores to avoid cachexia and sarcopenia.

Cholecystitis, including a secondary ascending bacterial infection, cannot be excluded. Although indiscriminate use of antibiotics is not normally recommended, one could start treatment with a broad-spectrum antibiotic if an improvement is not observed with the above therapies.

If further diagnostics are not pursued, although not ideal, empirical treatment for lymphoma or severe inflammatory bowel disease is suggested. For example, prednisolone (1 mg/kg/day), and then tapered to the minimum effective dose.







The information and recommendations provided are based on the images presented by the referring veterinarian. No evaluation can be communicated regarding pathology that was not visible in the image/video clips provided.

Thank you for this referral. If the clinical or image interpretation does not parallel your findings or if I can be of any further assistance please contact me.

Lisa Carioto, DVM, DVSc, Diplomate ACVIM
Lisa.Carioto@sonopath.com