

**PATIENT**

Daisy Gulliford

**SPECIES**

Canine

**BREED**

Shepherd Mix

**SEX**

Spayed Female

**AGE**

12 years

**WEIGHT**

47 Pounds

**INTERPRETED BY**Lisa Carioto, DVM,  
DVSc, Diplomate  
ACVIM**IMAGING PERFORMED BY**

Amy Mayhew LVT

**HOSPITAL NAME**

SVS Imaging Michigan

**REFERRING VET**

Hidden Springs VC

**INVOICE**

30216

**DATE**

5/9/22

**PRESENTING CLINICAL SIGNS**

History: 4-1-22 ER visit pet having episodes of Vomiting and diarrhea Started Denamarin . Elevated ALT and ALKP. 4-19-22 recheck blood values: ALT 640 ALKP: 270 from ER. Started on Clavamox 250mg 1 BID and Metronidazole 250mg 1BID continue denamarin. 5-6-22 BW recheck ALT 1561 and ALKP 610.

**ULTRASONOGRAPHIC EXAMINATION OF THE ABDOMEN****Urinary System**

The urinary bladder is adequately distended with anechoic contents. The wall is smooth and regular. No abnormalities are noted with the trigone or proximal urethra, and there is no evidence of sediment, cystoliths, polyps or a mass.

**Kidneys**

The **left** kidney measures 5.69 cm. The capsule is smooth. The cortex is very mildly hyperechoic and a mild loss of the normal definition of the cortico-medullary junction is present. Mineralizations of the diverticulae and pelvis are present, without evidence of nephroliths or pyelectasia. The surrounding mesentery is not hyperechoic.

The **right** kidney measures 5.68 cm. Findings are similar to the left kidney.

**Aortic bifurcation/trifurcation**

No abnormalities observed.

**Adrenal Glands**

The **left** adrenal gland measures 0.71 cm at the cranial pole and 0.56 cm at the caudal pole. The cranial pole is mildly "plump", however, there is no evidence of a mass or nodule. No abnormalities are noted with the gland's overall architecture, echogenicity or echotexture. The phrenico-abdominal vein and surrounding vasculature and mesentery are unremarkable.

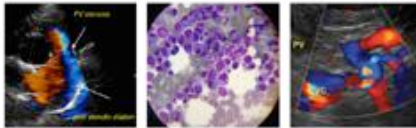
The **right** adrenal gland measures 0.63 cm at the cranial pole and 0.74 cm at the caudal pole (high normal and mildly "plump". No abnormalities are noted with the gland's overall architecture, echogenicity or echotexture. The phrenico-abdominal vein and surrounding vasculature and mesentery are unremarkable.

**Spleen**

The spleen is within normal limits in size, architecture and echogenicity. The capsule is smooth.

It is within normal limits in echotexture except for the following nodules:

1. A hypoechoic nodule is noted mid body at the level of the hilus, but dorsally. It measures 5.9 mm in diameter x 5.6 mm in length.
2. A hypoechoic nodule measuring, 3.5 mm in diameter x 4.6 mm in length, is noted mid-body, near the hilus.

**PATIENT**

Daisy Gulliford

**SPECIES**

Canine

**BREED**

Shepherd Mix

**SEX**

Spayed Female

**AGE**

12 years

**WEIGHT**

47 Pounds

**INTERPRETED BY**Lisa Carioto, DVM,  
DVSc, Diplomate  
ACVIM**IMAGING  
PERFORMED BY**

Amy Mayhew LVT

**HOSPITAL NAME**

SVS Imaging Michigan

**REFERRING VET**

Hidden Springs VC

**INVOICE**

30216

**DATE**

5/9/22

3. A hypoechoic nodule measuring in 5.9 mm in diameter x 8.0 mm in length is visualized at the head of the spleen.
4. A hypoechoic nodule adjacent to the one above is noted. It measures 4.1 mm in diameter x 6.0 mm in length.
5. A hyperechoic focal area is observed mid-body, measuring 6.9 mm in length. It flanks a blood vessel and is consistent with perivascular cuffing, however, it also casts a shadow, therefore, calcification is also present.

Perivascular cuffing, which is attributed to myelolipomas is observed. This is considered clinically insignificant. No abnormalities are observed with its vasculature, i.e. congestion and thrombi are not identified.

**Liver**

There are no obvious signs of hepatomegaly. The liver's borders are smooth and sharp to mildly rounded. A diffuse, mildly coarse or granular echotexture is observed. No obvious abnormalities are noted with the hepatic vessels.

Hypoechoic nodules are observed in the liver

1. 1.47 cm in diameter x 1.17 cm in length
2. 2.31 cm in diameter x 2.14 cm in length
3. 1.31 cm in diameter x 2.14 cm in length
4. 0.51 cm in diameter x 1.00 cm in length (medial to GB)
5. 0.64 cm in diameter x 1.29 cm in length (left transverse)
6. 0.87 cm in diameter x 1.04 cm in length (left transverse)

Target lesions are not observed.

The gallbladder wall is within normal limits in thickness and echogenicity. A small amount of echogenic material is present within the GB. The portions of the cystic and/or common bile ducts observed are not dilated or tortuous, i.e. there are no signs of an obstruction.

**Gastrointestinal**

Gas is present within the lumen of the stomach. The gastric wall is within normal limits in thickness and the wall layers are well defined. Subjectively, the muscularis is more prominent than usual. No obvious abnormalities are observed with its peristalsis.

The duodenum measures 0.55 cm (WNL). Very mild fogging of the mucosa is observed in addition to stippling.

The small intestinal wall thickness is within normal limits and the definition of the wall layers is preserved. Moderate stippling of the mucosa is observed in a few segments of the small intestine. Abnormally dilated loops of bowel are not observed. No abnormalities are observed with the ileocecal colic junction.

The colonic wall is not thickened and mural detail is considered normal. A large amount of gas and fecal matter are present in the colon.

**PATIENT**

Daisy Gulliford

**SPECIES**

Canine

**BREED**

Shepherd Mix

**SEX**

Spayed Female

**AGE**

12 years

**WEIGHT**

47 Pounds

**INTERPRETED BY**Lisa Carioto, DVM,  
DVSc, Diplomate  
ACVIM**IMAGING  
PERFORMED BY**

Amy Mayhew LVT

**HOSPITAL NAME**

SVS Imaging Michigan

**REFERRING VET**

Hidden Springs VC

**INVOICE**

30216

**DATE**

5/9/22

**Pancreas**

No overt abnormalities are observed with the echogenicity or echotexture of the left or right limbs. There is no evidence of hyperechogenicity of the surrounding mesentery, i.e., signs of active pancreatitis are not present.

**Other****Lymph nodes**

No abnormalities are observed

**Abdominal effusion** is not visualized.

**ULTRASONOGRAPHIC FINDINGS**

- The splenic nodules are suggestive of benign processes, such as nodular or lymphoid hyperplasia, as well as extramedullary hematopoiesis. Neoplasia, such as lymphoma, mast cell or other round cell tumour, is considered highly unlikely. However, a sonographic re-evaluation of Daisy's spleen is suggested as shepherds and shepherd crosses are predisposed to hemangiosarcoma and it would be prudent to monitor the evolution of the nodules.
- An obvious cause for the elevated hepatic enzyme activities is not identified on today's abdominal ultrasound. The parenchymal changes observed are suggestive of a reactive hepatopathy and nodular hyperplasia. Target lesions are not identified, i.e. there are no obvious signs of neoplasia. Although less likely, one cannot exclude neoplasia or diseases, such as cholestasis, immune mediated hepatitis, hepatitis due to infectious causes, toxin exposure, medications, etc., as well as cholangitis/cholangiohepatitis and cholecystitis. Evaluation of Daisy's history of natural supplements is suggested.
- The presence of sludge in the gallbladder is often clinically insignificant, however, some dogs may show clinical signs of gastroesophageal reflux disease (GERD), therefore, obtaining a history regarding signs of GERD from the client is suggested. Treatment with an anti-acid, proton pump inhibitor or ursodeoxycholic acid may be required depending on the patient's history.
- Gastrointestinal changes, such as fogging and stippling of the small intestines, are non-specific and somewhat subjective, however, they may also be present in patients suffering from gastrointestinal inflammation, for example, inflammatory bowel disease, food intolerance, dysbiosis, etc. Obtaining a history regarding signs of GERD, as well as pica, frequency of nausea, vomiting, diarrhea, etc. is suggested. The report from the emergency clinic mentioned that she receives the Royal Canin GI diet for due to issues with gas, therefore underlying IBD may be an issue. It is also possible that gastrointestinal abnormalities cause elevated liver enzymes due to bacteria ascending from the GI tract.
- The cranial pole of the left adrenal and the caudal pole of the right gland are "plump" and at the high end of normal reference range. These findings may be due to adrenal hyperplasia secondary to stress, chronic illness, or possibly pituitary dependent hyperadrenocorticism (HAC). There are no clinical signs associated with HAC, therefore, further diagnostics are not

**PATIENT**

Daisy Gulliford

necessary if Daisy is not demonstrating clinical signs of HAC. However, an evaluation of her arterial blood pressure and a urine protein: creatinine ratio are recommended (see below).

**SPECIES**

Canine

**INTERPRETATION OF THE FINDINGS & FURTHER RECOMMENDATIONS**

Evaluation of Daisy's history and exposure to medications and natural supplements is suggested.

**BREED**

Shepherd Mix

Obtaining a history regarding signs of GERD, as well as pica, frequency of nausea, vomiting, diarrhea, etc. is suggested.

**SEX**

Spayed Female

Although Daisy's adrenal glands are plump and at the high end of the normal reference range, she has a history of vomiting and diarrhea, therefore, a baseline (random) cortisol is strongly recommended to exclude hypoadrenocorticism.

**AGE**

12 years

A TLI, serum cobalamin, and folate concentrations may be considered depending on the frequency of pica, and episodes of vomiting and diarrhea. Daisy may also be suffering from dysbiosis.

Deworming with a broad spectrum dewormer is suggested, even if Daisy receives monthly heartworm prevention.

**WEIGHT**

47 Pounds

Small, frequent meals are recommended, including a small snack prior to going to bed, if she has a history of vomiting bile first thing in the morning.

Further diagnostics may be pursued to obtain a more definitive cause of the elevated liver enzyme activities. A fine needle aspirate (FNA) of the liver may be performed, as it is less invasive than a tissue biopsy, however, information regarding the architecture of the liver is only obtained with a tissue biopsy.

**INTERPRETED BY**

Lisa Carioto, DVM,  
DVSc, Diplomate  
ACVIM

Another less invasive option is to pursue a 2 week trial with a veterinary prescription brand hypoallergenic diet, whether hydrolyzed or novel protein, is suggested. Multiple diets may be required. Kibble may be soaked to help digestion. Note, hydrolyzed diets are low in fibre and Daisy's diet may require supplementation with psyllium to increase fibre content and decrease the risk of diarrhea.

**IMAGING PERFORMED BY**

Amy Mayhew LVT

A re-evaluation of Daisy's liver enzymes may be performed a few weeks after having introduced the hypoallergenic diet.

**HOSPITAL NAME**

SVS Imaging Michigan

A sonographic re-evaluation of Daisy's spleen is suggested as shepherds and shepherd crosses are predisposed to hemangiosarcoma and it would be prudent to monitor the evolution of the nodules, for example, in 4- 6 months. An evaluation of her liver may be performed at the same time.

**REFERRING VET**

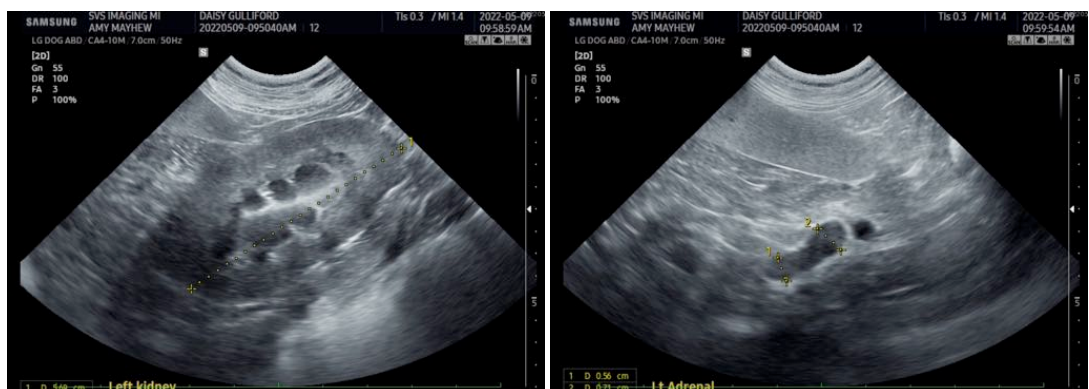
Hidden Springs VC

**INVOICE**

30216

**DATE**

5/9/22



IMAGING PERFORMED BY

SVS Mobile Imaging MI 734-637-7711  
svsimagingmi@gmail.com



PATIENT

Daisy Gullford

SPECIES

Canine

BREED

Shepherd Mix

SEX

Spayed Female

AGE

12 years

WEIGHT

47 Pounds

INTERPRETED BY

Lisa Carioto, DVM,  
DVSc, Diplomate  
ACVIM

IMAGING  
PERFORMED BY

Amy Mayhew LVT

HOSPITAL NAME

SVS Imaging Michigan

REFERRING VET

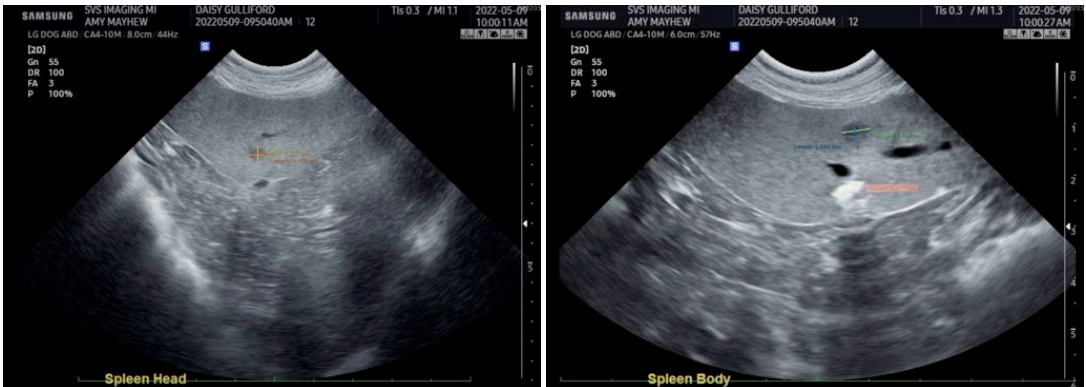
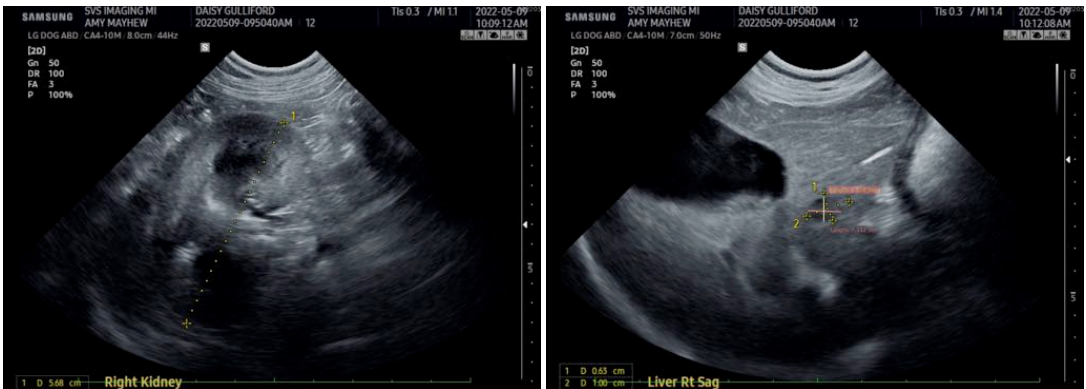
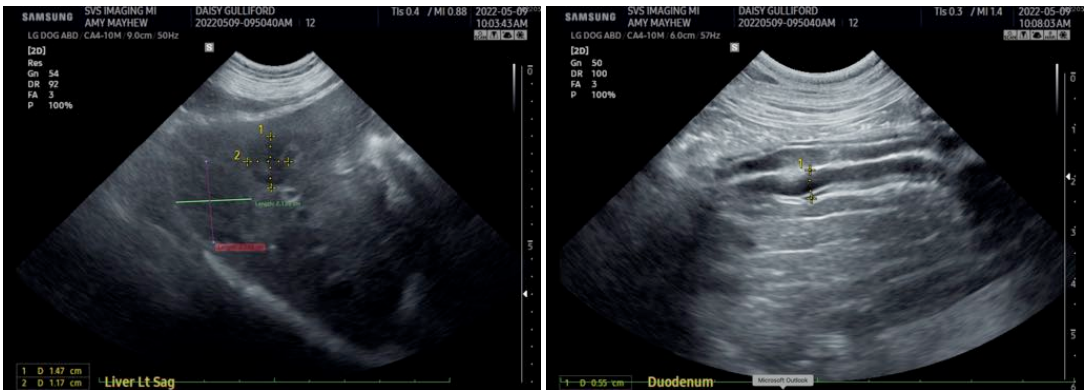
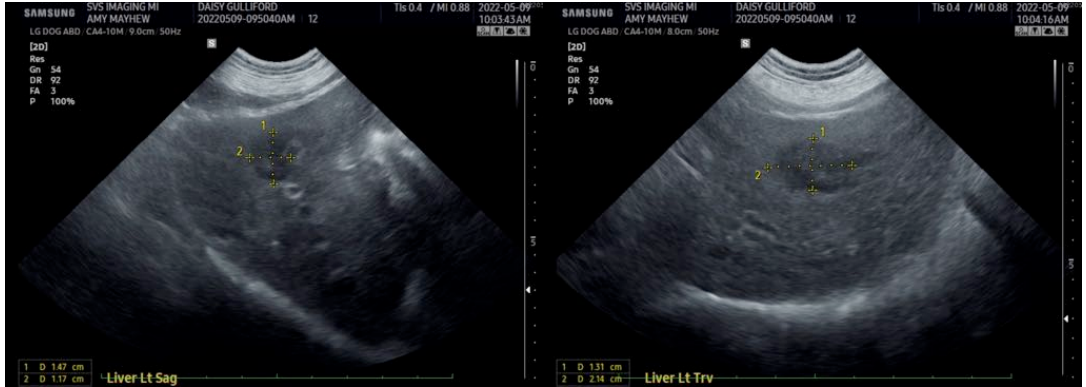
Hidden Springs VC

INVOICE

30216

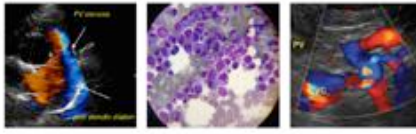
DATE

5/9/22



IMAGING PERFORMED BY

SVS Mobile Imaging MI 734-637-7711  
svsimagingmi@gmail.com



**PATIENT**

Daisy Gulliford

**SPECIES**

Canine

**BREED**

Shepherd Mix

**SEX**

Spayed Female

**AGE**

12 years

**WEIGHT**

47 Pounds

**INTERPRETED BY**

Lisa Carioto, DVM,  
DVSc, Diplomate  
ACVIM

**IMAGING  
PERFORMED BY**

Amy Mayhew LVT

**HOSPITAL NAME**

SVS Imaging Michigan

**REFERRING VET**

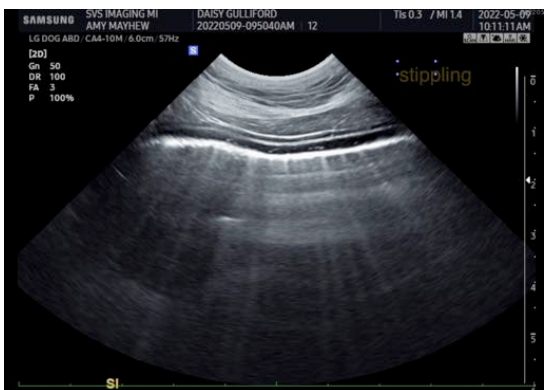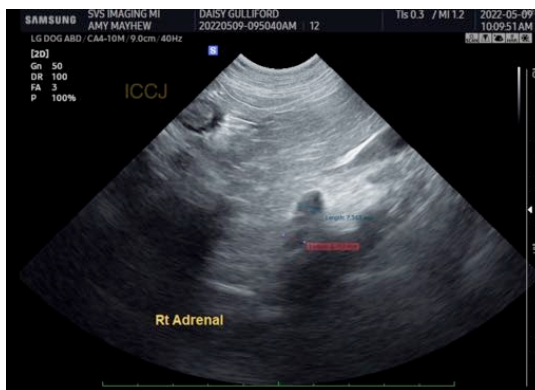
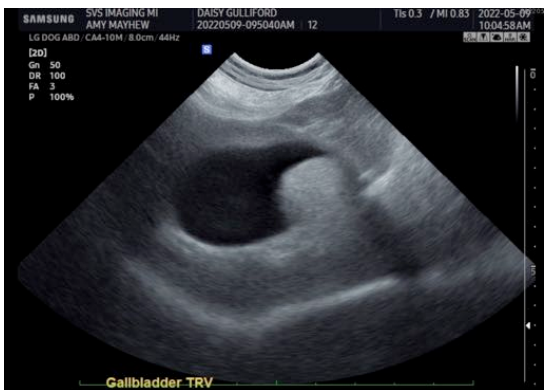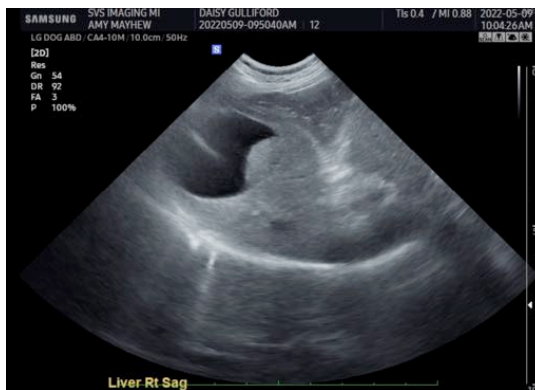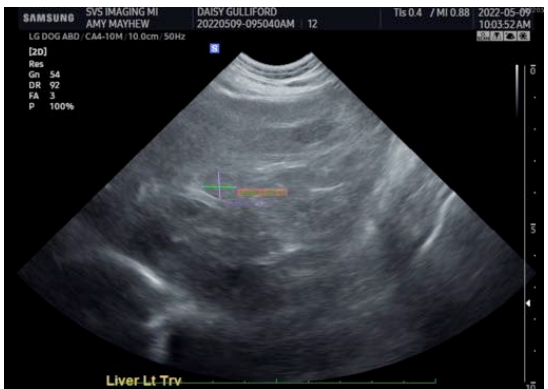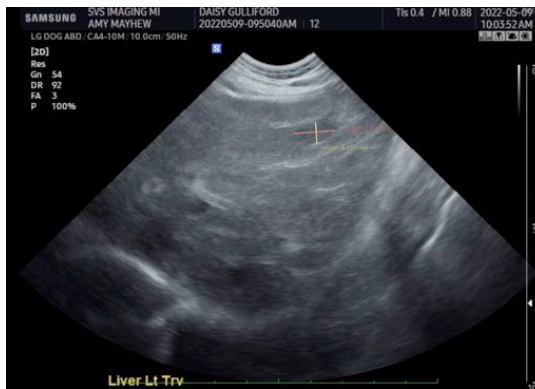
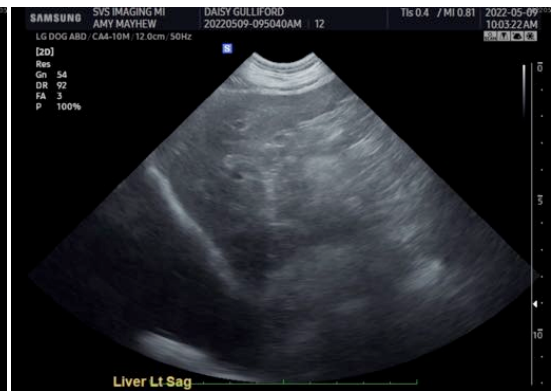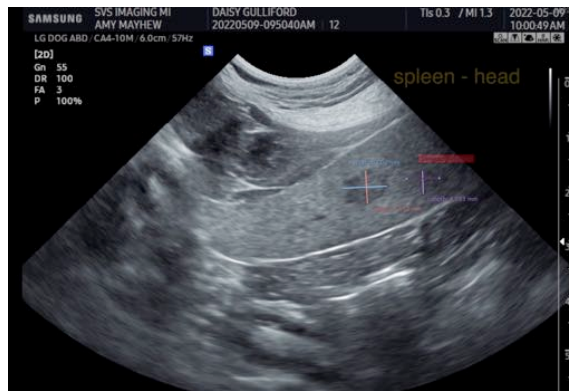Hidden Springs VC

**INVOICE**

30216

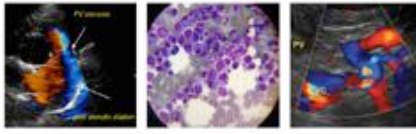
**DATE**

5/9/22



**IMAGING PERFORMED BY**

SVS Mobile Imaging MI 734-637-7711  
svsimagingmi@gmail.com



**PATIENT**

Daisy Gulliford

The information and recommendations provided are based on the images presented by the referring veterinarian/sonographer. No evaluation can be communicated regarding pathology that was not visible in the image/video clips provided.

**SPECIES**

Canine

Thank you for this referral. If the clinical or image interpretation does not parallel your findings or if I can be of any further assistance please contact me.

**BREED**

Shepherd Mix

Lisa Carioto, DVM, DVSc, Diplomate ACVIM

[Lisa.Carioto@sonopath.com](mailto:Lisa.Carioto@sonopath.com)

**SEX**

Spayed Female

**AGE**

12 years

**WEIGHT**

47 Pounds

**INTERPRETED BY**

Lisa Carioto, DVM,  
DVSc, Diplomate  
ACVIM

**IMAGING  
PERFORMED BY**

Amy Mayhew LVT

**HOSPITAL NAME**

SVS Imaging Michigan

**REFERRING VET**

Hidden Springs VC

**INVOICE**

30216

**DATE**

5/9/22