
**PATIENT PRESENTING CLINICAL SIGNS**

Tanya NHS History: 3 year old FS chihuahua with a grade 5/6 systolic heart murmur; on radiographs her heart is significantly enlarged. This was an incidental finding on OHE and no clinical signs reported at this time  
 No sedation needed.

**SPECIES**

Canine

**ULTRASONOGRAPHIC EXAMINATION OF THE HEART**

BREED	CANINE	MR	TR	LA/AO	LA/AO	FS	EF	EPSS
Chihuahua	<b>CARDIAC PARAMETERS</b>	<b>VMAX</b> (m/s)	<b>VMAX</b> (m/s)	(Boon method)	(Heart Base; Swedish)	(%)	(%)	(cm)
SEX	<b>NORMAL PARAMETER</b>	4.5-5.5	<2.7	1.3	<1.6	28-40	40-100	<0.6
Spayed Female	<b>PATIENT</b>	Not present	Not present	N/E	2.0	51	Not measured	0.24
AGE	3 years							
WEIGHT	<b>CANINE CARDIAC PARAMETERS</b>	<b>HR</b> (BPM)	<b>AV VMAX</b> (m/s)	<b>PV MAX</b> (m/s)	<b>BODY WEIGHT</b> kg	<b>LA</b> 2D long axis Base view (cm)	<b>LVIDd</b> Avg; 2D and m-mode short axis (cm)	<b>LVIDs</b> Avg; 2D and m-mode short axis (cm)
7.9 Pounds	<b>NORMAL PARAMETER</b>	50-100	0.7-1.7	0.7-1.6				
INTERPRETED BY	<b>PATIENT</b>	Not measured	2.13	1.21	3.59 kg	2.12 cm LAN = 1.37	2.99 LVIDND = 2.1	1.46
Lisa Carioto, DVM, DVSc, Diplomate ACVIM								

**IMAGING PERFORMED BY**

Loetitia Saint-Jacques, RVT

**HOSPITAL NAME**

Nevada Humane Society

**REFERRING VET**

Dr. Slatin

**INVOICE**

30112

**DATE**

30112

**Thoracic radiographs**
Right lateral view

Cardiomegaly (approximately 10.5 VHS) with left atrial enlargement

Small amount of air in esophagus, with aerophagia in stomach

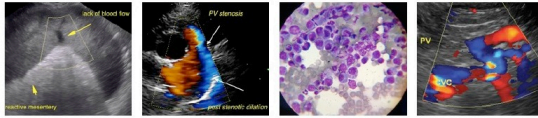
Left pulmonary vein appears mildly enlarged, i.e. mild congestion may be present

A diffuse, mild interstitial, peribronchiolar lung pattern is present

Left lateral view

Cardiomegaly with mild to moderate left atrial enlargement

Small amount of air in esophagus, with aerophagia in stomach



**PATIENT**

Tanya NHS

The pulmonary veins do not appear as distended on this view

Loss of the cranial waist, i.e. right heart enlargement.

The interstitial, peribronchiolar lung pattern appears moderate on this view

**SPECIES**

Canine

Ventro-dorsal view

**BREED**

Chihuahua

Cardiomegaly both right and left

The left atrium is only mildly enlarged

The right pulmonary vein appears “plump” and distended and is equal in diameter to the artery

**SEX**

Spayed Female

A severe aortic bulge is not appreciated, however, it is very mildly tortuous

**AGE**

3 years

ECG

A sinus arrhythmia is observed during the ECG (see echocardiogram, below).

The R wave is too tall (LVE)

**WEIGHT**

7.9 Pounds

Mild prolongation of PR interval, which may be physiological

Echocardiogram

**INTERPRETED BY**

Lisa Carioto, DVM,  
DVSc, Diplomate  
ACVIM

- An arrhythmia is present observed the echocardiogram
- No evidence of a ventricular or an atrial septal defect
- Patent ductus arteriosus (PDA)
- Velocity of PDA approximately 5.5 m/s
- PDA = 0.35 cm
- Increase in the LA: Ao ratio
- E greater than A
- Both leaflets of the mitral valve are thin and smooth.

**IMAGING PERFORMED BY**

Loetitia Saint-Jacques, RVT

**HOSPITAL NAME**

Nevada Humane Society

- Mitral regurgitation absent
- Marked Left ventricular enlargement, with rounding of the interventricular septum; Measurement when normalized for Tanya’s weight LVIDND = 2.1

**REFERRING VET**

Dr. Slatin

- Exuberant and increased contractility
- Left atrium 2.12 cm (long axis).

**INVOICE**

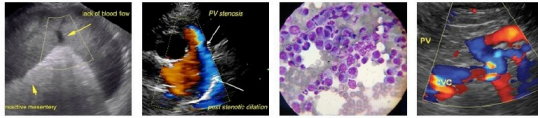
30112

- Left atrial enlargement is present; Measurement when normalized for Tanya’s weight LAN = 1.37
- An in-depth evaluation of the left auricle was not performed.

**DATE**

30112

- Both leaflets of the tricuspid valve are thin and smooth.
- Pulmonic valve, no abnormalities.



**PATIENT**

Tanya NHS

**SPECIES**

Canine

**BREED**

Chihuahua

**SEX**

Spayed Female

**AGE**

3 years

**WEIGHT**

7.9 Pounds

**INTERPRETED BY**

Lisa Carioto, DVM,  
DVSc, Diplomate  
ACVIM

**IMAGING PERFORMED BY**

Loetitia Saint-Jacques, RVT

**HOSPITAL NAME**

Nevada Humane Society

**REFERRING VET**

Dr. Slatin

**INVOICE**

30112

**DATE**

30112

- Trivial and intermittent pulmonic insufficiency
- Pulmonary artery – 0.81 cm
- Aorta -1.30 cm
- Mild acceleration of the aortic velocity
- Trivial aortic insufficiency
- Pulmonary artery: aortic ratio = 0.62
- No signs of pulmonary artery enlargement
- No signs of heart worm.
- No signs of pericardial or pleural effusion
- No evidence of pulmonary edema.
- A thrombus is not visualized.
- No evidence of a mass.

**ULTRASONOGRAPHIC FINDINGS**

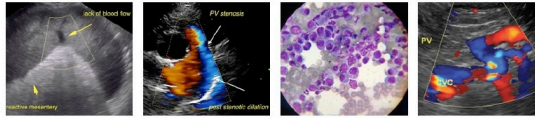
- Patent ductus arteriosus (left to right) with left ventricular and left atrial enlargement. The LA:Ao ratio is also moderately increased.
- There are no signs of congestive heart failure based on today's ultrasound finding, however, left atrial and left ventricular enlargement are present.
- Surgical correction of the PDA is recommended.
- Treatment with pimobendan is indicated pending the decision to pursue surgery.

**INTERPRETATION OF THE FINDINGS & FURTHER RECOMMENDATIONS**

Treatment with pimobendan is indicated and recommended at 0.25-0.30 mg/kg PO every 12 hours

Other suggestions/recommendations include:

- Evaluation of blood pressure
- The foster family should have a few days' worth of furosemide at home in case of an emergency at 1-1.5 mg/kg PO every 12 hours
- Monitoring of the resting (sleeping) respiratory rate (RRR) is highly recommended once a day. The RRR should NOT EXCEED 30 breaths per minute (bpm). If the respiratory rate is greater than 30 bpm, or if there is a gradual increase (over a day or two) toward 30 bpm, the patient should be evaluated immediately for congestive heart failure and the appropriate treatment initiated.



**PATIENT**

Tanya NHS

- If surgery is not pursued, pimobendan, spironolactone (for its antifibrotic effects) should be pursued lifelong and monitoring for progression with a re-evaluation of an echocardiogram is recommended. Echocardiograms may be repeated every 6 months, or sooner if clinical signs develop.

**SPECIES**

Canine

- Omega-3 fatty acids may also be considered

**BREED**

Chihuahua

**SEX**

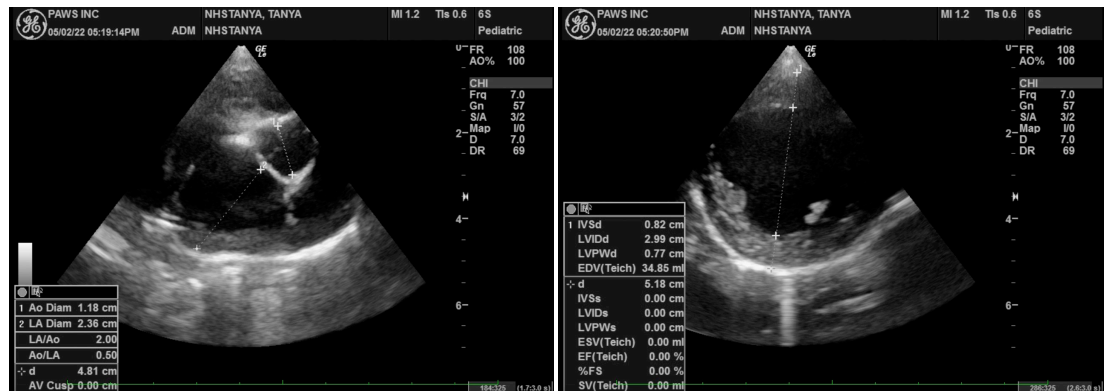
Spayed Female

**AGE**

3 years

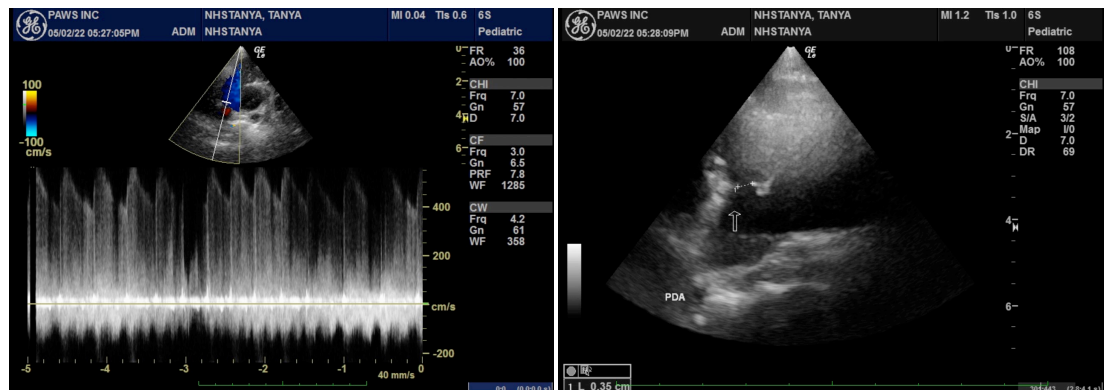
**WEIGHT**

7.9 Pounds



**INTERPRETED BY**

Lisa Carioto, DVM,  
DVSc, Diplomate  
ACVIM



**IMAGING PERFORMED BY**

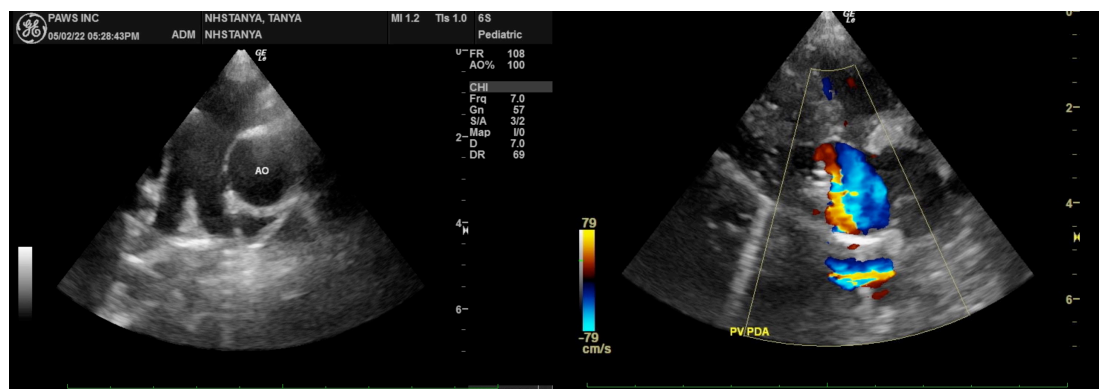
Loetitia Saint-Jacques, RVT

**HOSPITAL NAME**

Nevada Humane Society

**REFERRING VET**

Dr. Slatin

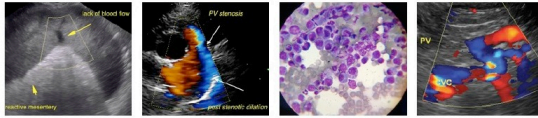


**INVOICE**

30112

**DATE**

30112



**PATIENT**

Tanya NHS

The information and recommendations provided are based on the images presented by the referring veterinarian/sonographer. No evaluation can be communicated regarding pathology that was not visible in the image/video clips provided.

**SPECIES**

Canine

Thank you for this referral. If the clinical or image interpretation does not parallel your findings or if I can be of any further assistance please contact me.

**BREED**

Chihuahua

Lisa Carioto, DVM, DVSc, Diplomate ACVIM

[Lisa.Carioto@sonopath.com](mailto:Lisa.Carioto@sonopath.com)

**SEX**

Spayed Female

**AGE**

3 years

**WEIGHT**

7.9 Pounds

**INTERPRETED BY**

Lisa Carioto, DVM,  
DVSc, Diplomate  
ACVIM

**IMAGING PERFORMED  
BY**

Loetitia Saint-Jacques, RVT

**HOSPITAL NAME**

Nevada Humane Society

**REFERRING VET**

Dr. Slatin

**INVOICE**

30112

**DATE**

30112