



PATIENT

Teddy Petrosino

SPECIES

Feline

BREED

El;-dsh

SEX

Neutered male

AGE

11 years

WEIGHT

10.8 lbs

INTERPRETED BY

Lisa Carioto, DVM,
DVSc, Diplomate
ACVIM

IMAGING PERFORMED BY

Kelly Vazquez, CVT

HOSPITAL NAME

Animal Paradise
Hospital

REFERRING VET

Dr. Hellworth

INVOICE

30470

DATE

5/17/22

PRESENTING CLINICAL SIGNS

History: Patient recently had a heart attack per the owner. History of grade 5/6 heart murmur.
Current meds: Vetmedin 1.25, Clavamox 125 mgs.
Abnormal PE/Chem/CBC/UA Results: WBCs 26.29, neuts. 16.63, EOS 16.1. U/A: trace protein.

ULTRASONOGRAPHIC EXAMINATION OF THE ABDOMEN

| FELINE CARDIAC PARAMETERS | BODY WEIGHT (kg) | HR (BPM) | IVSd (cm) | LVIDd (cm) | LVWd (cm) | FS (%) | EF (%) |
|--|------------------------|------------------------------------|---|--------------------|--------------------|--------------|-----------|
| NORMAL PARAMETER | ----- | 150-240 | 0.3-0.6 | 1.0-2.1 | 0.25-0.6 | 35-67 | 80-100 |
| PATIENT | 4.91 | NM | 0.29 | 1.72 | 0.35 | 50 | NM |
| FELINE CARDIAC PARAMETERS | LA/AO (Boon) | LA/AO HEART BASE (Sisson) | LA 2D 4-chamber long axis AS to FW (Sisson) (cm) | LVOT VEL. (m/s) | RVOT VEL. (m/s) | IVRT (m/) | |
| NORMAL PARAMETER | <1.5 | 0.88-1.79 | 0.7-1.7 | <1.6 | <1.3 | 40-60 | |
| PATIENT | 1.69 | 1.58 | 1.72 | 1.50 | 0.92 | NM | |
| Adapted from June Boon, Veterinary Echocardiography, 1998 Sisson D et al. JVIM 1991; 5: 232, Jacobs et al. Am J Vet Res 1985; 46:1705 | | | | | | | |

Electrocardiogram

Not performed, however, an arrhythmia is noted during initial portion of the echocardiogram; premature beats that are occurring in doublets

Cardiac Presentation

- *Mitral valve*: Very mild myxomatous degeneration of the septal leaflet
- Mild mitral regurgitation (1.6 m/s)
- Mild left atrial enlargement
- Mild left auricular enlargement
- Very mild increase in LA: Ao ratio depending on method of measurement
- Hypertrophy of apical papillary muscle
- Mild to moderate turbulent blood flow in the LVOT
- No systolic anterior motion of the mitral valve ("SAM")
- No evidence of "smoke" in the LA
- Hyperechogenicity of the region of the atrioventricular node
- *Tricuspid valve*: No abnormalities
- Trivial tricuspid regurgitation (1.2 m/s)



PATIENT

Teddy Petrosino

SPECIES

Feline

BREED

El;-dsh

SEX

Neutered male

AGE

11 years

WEIGHT

10.8 lbs

INTERPRETED BY

Lisa Carioto, DVM,
DVSc, Diplomate
ACVIM

**IMAGING
PERFORMED BY**

Kelly Vazquez, CVT

HOSPITAL NAME

Animal Paradise
Hospital

REFERRING VET

Dr. Hellworth

INVOICE

30470

DATE

5/17/22

- No right ventricular or atrial enlargement
- *Aortic valve*: No abnormalities
- Very mild turbulent blood flow in the left ventricular outflow tract
- *Pulmonic valve*: No abnormalities.
- No pulmonary insufficiency
- Pulmonary artery: no abnormalities
- No evidence of pulmonary edema
- No signs of pericardial, pleural effusion
- No obvious signs of an intracardiac mass
- EPSS = 0.29 cm

ULTRASONOGRAPHIC FINDINGS

Cardiac

Restrictive cardiomyopathy, ACVIM stage B2. There is no evidence of prethrombic “smoke”.

Teddy’s “heart attack” may have been a syncopal episode due to an intermittent arrhythmia, which is most likely due to premature ventricular contractions. However, an ECG is required to confirm the type of arrhythmia.

INTERPRETATION OF THE FINDINGS & FURTHER RECOMMENDATIONS

The source of leukocytosis, neutrophilia and eosinophilia should be identified, if possible.

Recommendations include the following

- Deworming with fenbendazole is suggested; 50 mg/kg PO once a day for 3 days and repeat treatment 3 weeks later
- An ECG
- An arterial blood pressure
- A urine culture to exclude pyelonephritis (more common in older cats)
- A urine protein: creatinine ratio
- +/- thoracic radiographs
- +/- abdominal ultrasound

Treatment with benazepril is suggested to treat restrictive cardiomyopathy. However, if hypertension and/or proteinuria is/are present, telmisartan should be used instead of benazepril. Both medications should be uptitrated slowly, for example, 0.10 mg/kg/day for 3 days, then 0.25 mg/kg/day for 3 days, then 0.25 mg/kg PO BID thereafter. If twice a day dosing is difficult, then once a day may be administered.



PATIENT

Teddy Petrosino

SPECIES

Feline

BREED

El;-dsh

SEX

Neutered male

AGE

11 years

WEIGHT

10.8 lbs

INTERPRETED BY

Lisa Carioto, DVM,
DVSc, Diplomate
ACVIM

**IMAGING
PERFORMED BY**

Kelly Vazquez, CVT

HOSPITAL NAME

Animal Paradise
Hospital

REFERRING VET

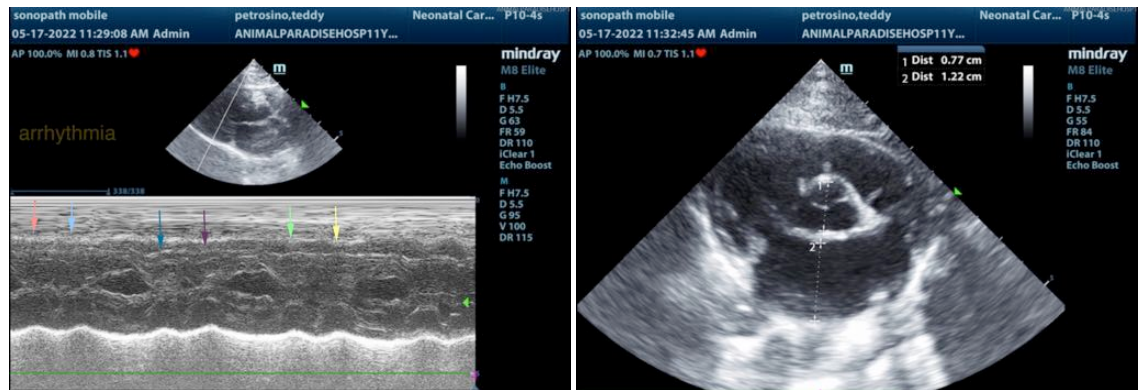
Dr. Hellworth

INVOICE

30470

DATE

5/17/22



The information and recommendations provided are based on the images presented by the referring veterinarian/sonographer. No evaluation can be communicated regarding pathology that was not visible in the image/video clips provided.

Thank you for this referral. If the clinical or image interpretation does not parallel your findings or if I can be of any further assistance please contact me.

Lisa Carioto, DVM, DVSc, Diplomate ACVIM

Lisa.Carioto@sonopath.com