



**PATIENT**

Hank Meyers

**SPECIES**

Feline

**BREED**

DSH

**SEX**

Neutered Male

**AGE**

14 Years

**WEIGHT**

6.8 Pounds

**PRESENTING CLINICAL SIGNS**

anorexia, diarrhea then constipation, wt loss, heart murmur  
 Abnormal PE/Chem/CBC/UA Results: 5/4/22: Ca 11.4, amylase 1500, T4 normal, elevated neuts, low lymphocytes

**ULTRASONOGRAPHIC EXAMINATION OF THE HEART & ABDOMEN**

FELINE CARDIAC PARAMETERS	BODY WEIGHT (kg)	HR (BPM)	IVSd (cm)	LVIDd (cm)	LVWd (cm)	FS (%)	EF (%)
NORMAL PARAMETER	-----	150-240	0.3-0.6	1.0-2.1	0.25-0.6	35-67	80-100
PATIENT	3.1	216	0.31	1.01	0.25	45	81
FELINE CARDIAC PARAMETERS	LA/AO (Boon)	LA/AO HEART BASE (Sisson)	LA 2D 4-chamber long axis AS to FW (Sisson) (cm)	LVOT VEL. (m/s)	RVOT VEL. (m/s)	IVRT (m/)	
NORMAL PARAMETER	<1.5	0.88-1.79	0.7-1.7	<1.6	<1.3	40-60	
PATIENT	1.13	0.76	0.99	0.64	NM	NM	
Adapted from June Boon, Veterinary Echocardiography, 1998 Sisson D et al. JVIM 1991; 5: 232, Jacobs et al. Am J Vet Res 1985; 46:1705							

**INTERPRETED BY**

Lisa Carioto, DVM,  
 DVSc, Diplomate  
 ACVIM

**IMAGING PERFORMED BY**

Diane McFadden

**HOSPITAL NAME**

Newton Vet Hospital

**REFERRING VET**

Dr. Kim

**INVOICE**

37647

**DATE**

5/13/22

- Severe hypertrophy of the papillary muscles
- Hypertrophy of the apical papillary muscle
- Interventricular septum (diastole): Low end of the normal reference range
- Left ventricular free wall (diastole): Low end of the normal reference range
- Left ventricular internal dimension (diastole): decreased due to hypertrophy of papillary muscles
- Presence of systolic anterior motion of the mitral valve
- Very mild mitral regurgitation.
- Redundant aorta which is not uncommon in older cats; false decrease in the LA: Ao ratio due to enlargement of aorta
- No evidence of left atrial enlargement
- No evidence of "smoke"
- Mildly turbulent blood flow in the left ventricular outflow tract
- Tricuspid valve: Incidental finding; septal leaflet longer and forms a "backward hook", no abnormalities noted with posterior leaflet
- Mild to moderate tricuspid regurgitation.
- No right ventricular or atrial enlargement.
- Pulmonic valve: no abnormalities.
- Pulmonary artery: no abnormalities.
- No evidence of pulmonary edema
- No signs of pericardial, pleural effusion
- No obvious signs of an intracardiac mass.
- Endocardium and myocardium: no obvious abnormalities



**PATIENT**

**Urinary System**

Hank Meyers

The urinary bladder is well distended. The wall is smooth and regular. No abnormalities are present with the trigone or proximal urethra. A moderate amount of free floating sediment is present, however, there is no evidence of cystoliths, polyps or a mass.

**SPECIES**

Feline

**Kidneys**

The **left** kidney measures 4.04 cm (3.80-4.40 cm). The capsule is smooth. The cortex is moderately hyperechoic and a mild to moderate loss of the normal definition of the cortico-medullary junction is present. Hyperechoic regions within the cortex suggestive of inflammation, ischemia or fibrosis are also observed. A thick hyperechoic ill-defined band is observed along the medulla, traversing parallel to the corticomedullary junction. There is no evidence of nephroliths or pyelectasia. Blood flow is not normal, but "adequate". The surrounding mesentery is not hyperechoic.

**BREED**

DSH

**SEX**

Neutered Male

The **right** kidney measures 4.50 cm (3.80-4.40 cm); mildly enlarged. The cortex is moderately hyperechoic and a mild to moderate loss of the normal definition of the cortico-medullary junction is present. Hyperechoic regions within the cortex suggestive of inflammation, ischemia or fibrosis are also observed. A thick hyperechoic ill-defined band is observed along the medulla, traversing parallel to the corticomedullary junction. There is no evidence of nephroliths or pyelectasia. Blood flow is decreased. The surrounding mesentery is not hyperechoic.

**AGE**

14 Years

**Aortic bifurcation/trifurcation**

No abnormalities observed.

**WEIGHT**

6.8 Pounds

**Adrenal Glands**

The **left** adrenal gland measures 0.67 cm in diameter x 1.02 cm in length. It is oval in shape and "plump", however, an obvious mass is not identified. The phrenico-abdominal vein and surrounding vasculature are unremarkable. The mesentery is hyperechoic throughout the entire cranial abdomen.

**INTERPRETED BY**

Lisa Carioto, DVM,  
DVSc, Diplomate  
ACVIM

The **right** adrenal gland measures 0.38 cm in diameter x 1.13 cm in length. No abnormalities are noted with the gland's overall architecture, echogenicity or echotexture. No abnormalities are observed with the phrenico-abdominal vein or surrounding vasculature. The mesentery surrounding the gland is hyperechoic.

**IMAGING PERFORMED BY**

Diane McFadden

**Spleen**

The spleen is within normal limits in echotexture and echogenicity, and the capsule is smooth. However, its diameter is size 4.8 mm (normal = 10 mm). This is suggestive of hypovolemia. No abnormalities are observed with its vasculature, i.e. congestion and thrombi are not identified.

**HOSPITAL NAME**

Newton Vet Hospital

**Liver**

**REFERRING VET**

Dr. Kim

There are no obvious signs of hepatomegaly and its borders are smooth and relatively sharp, to mildly rounded. A diffuse, mildly coarse or granular echotexture is observed. It is also diffusely hyperechoic. Focal lesions are not observed. Multiple hyperechoic choleliths (acoustic shadowing) and mineralizations are present within the intrahepatic bile ducts. No obvious abnormalities are noted with the hepatic vessels.

**INVOICE**

37647

The gallbladder (GB) is severely distended with a moderate amount of free floating echogenic material. The GB wall is within normal limits in thickness and echogenicity. The cystic duct is markedly dilated and severely tortuous. The common bile duct is dilated, measuring 6.4 mm. No abnormalities are observed with the duodenal papilla. Multiple hyperechoic choleliths (acoustic shadowing) and mineralizations are present within the intrahepatic bile ducts.

**DATE**

5/13/22



**PATIENT**

**Gastrointestinal**

Hank Meyers

A very large amount of fluid and gas are present within the lumen of the stomach. Decreased peristalsis is also observed, i.e., a significant ileus is present. The gastric wall is within normal limits in thickness and the wall layers are well defined.

**SPECIES**

Feline

The duodenum is also affected by a mild ileus. It is within normal limits in thickness and the definition of wall layers is preserved, however, subjectively, the mucosa and muscularis layers prominent.

**BREED**

DSH

The thickness of the small intestines is within normal limits and the definition of the wall layers is preserved. However, the submucosa and muscularis of multiple segments of jejunum are more prominent than usual, and the mesentery surrounding these loops of bowel is hyperechoic. Abnormally dilated loops of bowel are not observed.

**SEX**

Neutered Male

Gas and ingesta are present within the transverse colon.

The colonic wall is not thickened and mural detail is considered normal.

**Pancreas**

**AGE**

14 Years

The **right limb** is enlarged, diffusely hypoechoic and has irregular contours. The surrounding mesenteric fat is severely hyperechoic, suggestive of saponification. These findings are highly suggestive of active pancreatitis. Overt signs of neoplasia are not noted.

**WEIGHT**

6.8 Pounds

The **left limb** is diffusely hypoechoic, but not as enlarged compared to the right limb. The mesentery surrounding is mildly hyperechoic. These findings are suggestive of active pancreatitis. Overt signs of neoplasia are not noted.

**Other**

**INTERPRETED BY**

**Lymph nodes**

Lisa Carioto, DVM,  
DVSc, Diplomate  
ACVIM

Lymphadenomegaly in the region of the right limb of the pancreas. The lymph node is severely hypoechoic and measures 1.5 cm in diameter x 2.04 cm in length. The mesentery surrounding the lymph node is severely hyperechoic.

**IMAGING PERFORMED BY**

**Abdominal effusion** is not visualized.

Diane McFadden

**ULTRASONOGRAPHIC FINDINGS**

**HOSPITAL NAME**

Newton Vet Hospital

- Papillary muscles are hypertrophied, however, the interventricular septum and left ventricular free walls are within the normal reference ranges, albeit at the low end. There is no evidence of left atrial enlargement. Rather, his left atrium appears mildly decreased in size, as does the left ventricular internal dimension, i.e. hypovolemia is suspected. This was confirmed on the abdominal ultrasound based on the size of the spleen.

**REFERRING VET**

Dr. Kim

- The changes noted with the tricuspid valve is an incidental finding.
- Active **pancreatitis** is suspected.

**INVOICE**

37647

- Choleliths are present within the intrahepatic bile ducts, and a severe dilation and tortuosity of the cystic and common bile ducts are noted. The gall bladder is also moderately dilated. However, an obvious obstruction is not evident. Therefore, the changes observed may be due to suppurative cholangitis/cholangiohepatitis, and cholecystitis, as well as ascending inflammation from pancreatitis.

**DATE**

5/13/22



**PATIENT**

Hank Meyers

- A reactive hepatopathy may be the cause of the mildly granular, coarse echotexture. The diffuse hyperechogenicity of the liver may be due to cholangitis/cholangiohepatitis, and cholecystitis. A suppurative component to the latter disease processes is possible. Hepatic lipidosis secondary to hyporexia and pancreatitis may be contributing to the hyperechogenicity.

**SPECIES**

Feline

- A moderate **ileus** of the stomach and mild ileus of the duodenum are present. The **intestinal abnormalities** are subtle. Inflammation secondary to the suspected suppurative cholangitis/cholangiohepatitis, cholecystitis, and pancreatitis is possible. However, underlying inflammatory bowel disease cannot be excluded, i.e. "triaditis".

**BREED**

DSH

- Lymphadenomegaly may be due to reactive hyperplasia, however, or severe inflammation. Although overt signs of neoplasia are not visualized on the ultrasound, neoplasia in its early stages cannot be excluded.

**SEX**

Neutered Male

- **Renal** changes are suggestive of age-related degeneration, however, signs of chronic renal disease and previous episodes of ischemia and fibrosis are evident. The right kidney is mildly enlarged and also shows decreased blood flow. Pyelonephritis cannot be excluded.

**AGE**

14 Years

- The **left adrenal gland** is "plump", however, an obvious mass is not identified. Adrenal hyperplasia due to stress, chronic illness or development of a benign adenoma are possible differential diagnoses.

**WEIGHT**

6.8 Pounds

- **Hypovolemia** appears to be present based on the size of the **spleen**.
- The free floating sediment within the lumen of the **urinary bladder** is most likely composed of mucus, crystalline material and exfoliated cells. The debris is likely clinically insignificant given the lack of inflammatory changes to the bladder wall, however, findings should be correlated with clinical signs and a urinalysis.
- The constipation is likely due to **dehydration**.

**INTERPRETED BY**

Lisa Carioto, DVM,  
DVSc, Diplomate  
ACVIM

**IMAGING**

**PERFORMED BY**

Diane McFadden

**HOSPITAL NAME**

Newton Vet Hospital

**REFERRING VET**

Dr. Kim

**INVOICE**

37647

**DATE**

5/13/22

**INTERPRETATION OF THE FINDINGS & FURTHER RECOMMENDATIONS**

An arterial blood pressure is suggested *after having treated Hank with analgesics*.

Cardiac medication is not necessary at the moment, however, a re-evaluation of an echocardiogram is suggested in 4-6 months to monitor the hypertrophy of the papillary muscles.

An evaluation of his heart rate at home is suggested once he has recovered from his concurrent illness.

Monitoring of the resting (sleeping) respiratory rate (RRR) is recommended once a week. The RRR should NOT EXCEED 30 breaths per minute (bpm). If the respiratory rate is greater than 30 bpm, or if there is a gradual increase (over a day or two) toward 30 bpm, the patient should be evaluated immediately for congestive heart failure and the appropriate treatment initiated.

If Hank has sustained tachycardia at home or if he is hypertensive (on multiple occasions), benazepril or telmisartan is suggested at 0.1 mg/kg PO q24h for 3 days, then 0.25 mg/kg PO q24h for 3 days, then 0.25 mg/kg PO q12h thereafter. An evaluation of his renal parameters and blood pressure is recommended 5 to 7 days after having achieved the maximum dose of medication.



**PATIENT**

A urinalysis and urine culture and sensitivity are suggested to exclude possible pyelonephritis.

Hank Meyers

Additional suggestions include the following

**SPECIES**

Feline

- Intravenous fluids – monitor for signs of volume overload
- Intravenous analgesia, such as buprenorphine every 6 to 8 hours, however, it is likely that the latter will be insufficient. Therefore, consider constant rate infusions, for example, lidocaine and ketamine CRIs, as well as buprenorphine every 6-8 hours or butorphanol CRI or fentanyl CRIs to control his discomfort.

**BREED**

DSH

- Administration of vitamin K due to high index of suspicion of cholestasis (0.5 mg/kg SQ q8-12h for 1-3 doses)
- maropitant (Cerenia) if nauseous or vomiting at 1 mg/kg IV or SQ every 24 hours
- vitamin B12 250 ug/injection – one dose to start and to re-assess depending on clinical status
- nasoesophageal tube to remove gastric fluid and then consider “trickle feeding” to decrease risk of developing hepatic lipidosis

**SEX**

Neutered Male

- arterial blood pressure
- ampicillin and enrofloxacin intravenously

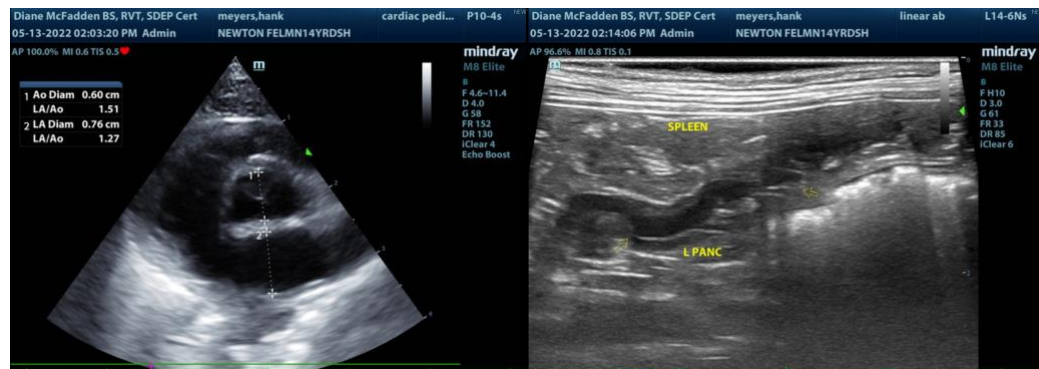
**AGE**

14 Years

- although an obvious obstruction is not evident, a cholecystectomy or surgical passing of a catheter may be required if there is no improvement within 42-72 hours.

**WEIGHT**

6.8 Pounds

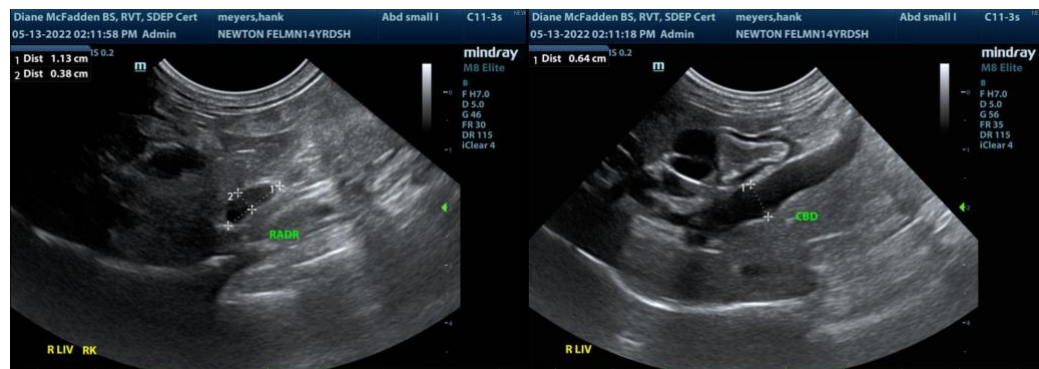


**INTERPRETED BY**

Lisa Carioto, DVM,  
DVSc, Diplomate  
ACVIM

**IMAGING PERFORMED BY**

Diane McFadden



**HOSPITAL NAME**

Newton Vet Hospital

**REFERRING VET**

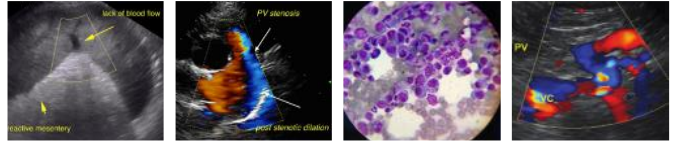
Dr. Kim

**INVOICE**

37647

**DATE**

5/13/22



**PATIENT**

Hank Meyers

**SPECIES**

Feline

**BREED**

DSH

**SEX**

Neutered Male

**AGE**

14 Years

**WEIGHT**

6.8 Pounds

**INTERPRETED BY**

Lisa Carioto, DVM,  
DVSc, Diplomate  
ACVIM

**IMAGING  
PERFORMED BY**

Diane McFadden

**HOSPITAL NAME**

Newton Vet Hospital

**REFERRING VET**

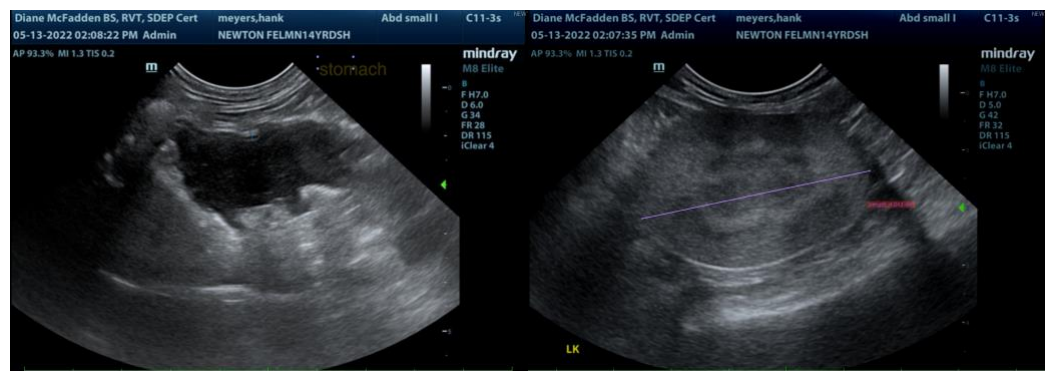
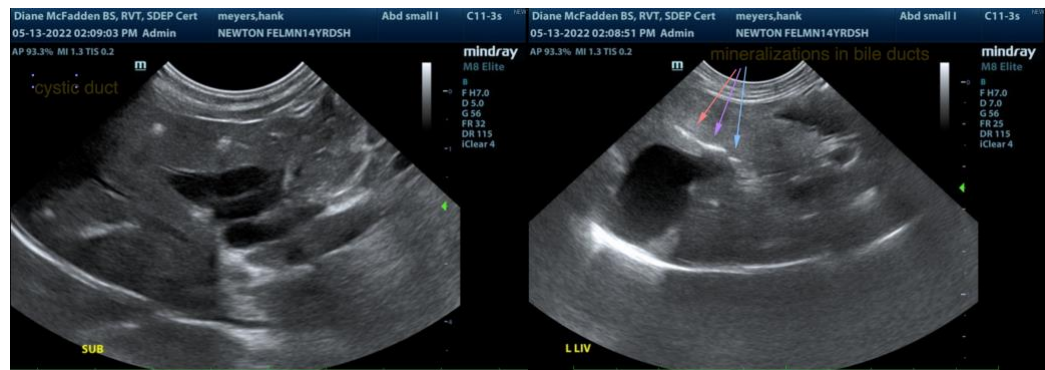
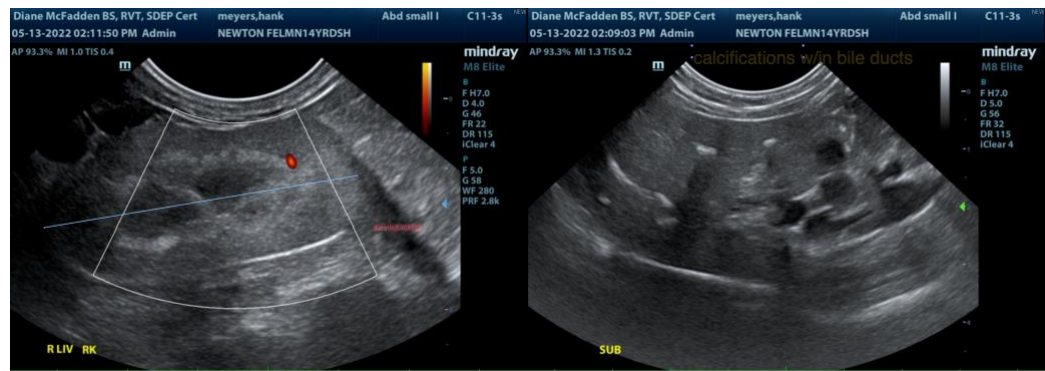
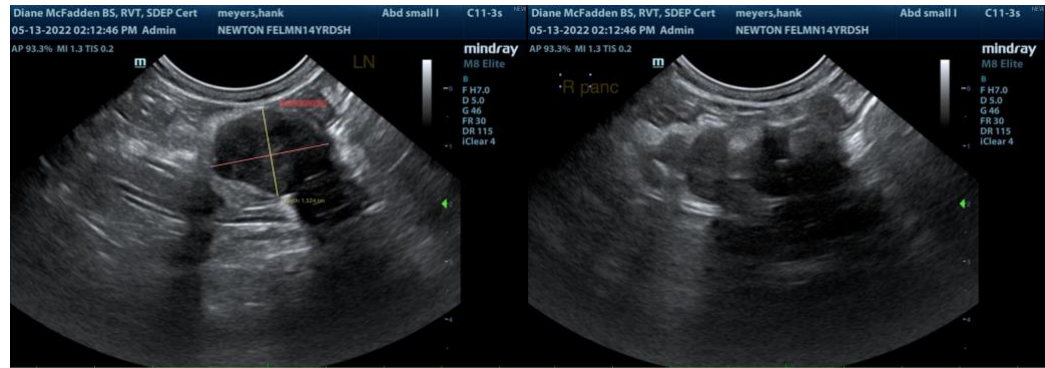
Dr. Kim

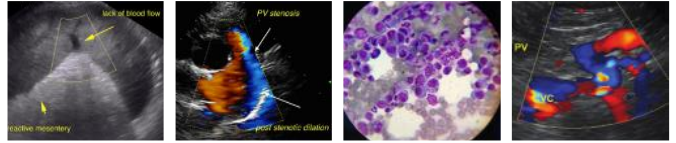
**INVOICE**

37647

**DATE**

5/13/22





**PATIENT**

Hank Meyers

**SPECIES**

Feline

**BREED**

DSH

**SEX**

Neutered Male

**AGE**

14 Years

**WEIGHT**

6.8 Pounds

**INTERPRETED BY**

Lisa Carioto, DVM,  
DVSc, Diplomate  
ACVIM

**IMAGING  
PERFORMED BY**

Diane McFadden

**HOSPITAL NAME**

Newton Vet Hospital

**REFERRING VET**

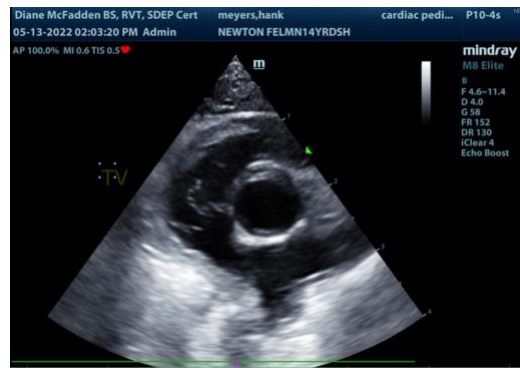Dr. Kim

**INVOICE**

37647

**DATE**

5/13/22



The information and recommendations provided are based on the images presented by the referring veterinarian/sonographer. No evaluation can be communicated regarding pathology that was not visible in the image/video clips provided.

Thank you for this referral. If the clinical or image interpretation does not parallel your findings or if I can be of any further assistance please contact me.

Lisa Carioto, DVM, DVSc, Diplomate ACVIM

[Lisa.Carioto@sonopath.com](mailto:Lisa.Carioto@sonopath.com)