

**DATE**

4/18/22

PRESENTING CLINICAL SIGNS

Presented for cough initially on 4/9. Treated supportively with doxy and hydrocodone. Cough improved but increased respiratory rate noted 4/14. Chest xrays show mild to mod pleural effusion and normal sized heart. Gr 2/6 heart murmur noted but otherwise stable on presentation. Too little fluid to be able to tap on 4/16.

PATIENT

Vera Collins

Rec bicavitary u/s

Current Medications: doxycycline 100mg/ml 0.1ml PO q12hr x 10d

hydrocodone 5mg 1/4 tab PO q6-12 hr #5, one dose of lasix given on 4/15 - lasix 50mg/ml 0.15ml IM.

Lab Results: (4/15)- alb 1.4, glob 1.5, ca 6.8

SPECIES

Canine

Radiographs show both pleural effusion and ascites. The pulmonary vein is not enlarged.

Date of Previous IntraPet Ultrasound: No previous.

Sedation: Not required to complete full diagnostic ultrasound.

Stat Report: Not requested.

BREED

Maltese

Imaging Performed By: Stephanie Pearce RDCS, RVT.

ULTRASONOGRAPHIC EXAMINATION OF THE ABDOMEN**SEX**

Spayed Female

Urinary System

The urinary bladder is well distended with anechoic contents. The wall is smooth and regular. No abnormalities are noted with the trigone or proximal urethra, and there is no evidence of sediment, cystoliths, polyps or a mass.

AGE

2/11/10

Kidneys

The **left** kidney measures 2.85 cm. The capsule is smooth, however, the cortex is mildly hyperechoic and a mild loss of the normal definition of the cortico-medullary junction is present. Very mild mineralization of the diverticulae and pelvis are noted, without signs of nephroliths or pyelectasia. The surrounding mesentery is severely hyperechoic. Blood flow is considered very good.

WEIGHT

5.59 lbs

The **right** kidney measures 3.27 cm. Findings are similar to the left kidney.

INTERPRETED BY

Lisa Carioto, DVM,
DVSc, Diplomate
ACVIM

Adrenal Glands

The **left** adrenal gland measures 0.63 cm at the cranial pole, 0.43 cm at the caudal pole and 1.73 cm in length. The cranial pole is enlarged, "plump" and rounder than normal. However, a mass effect is not noted. No abnormalities are noted with the gland's overall echogenicity or echotexture. The phrenico-abdominal vein and surrounding vasculature and mesentery are unremarkable.

HOSPITAL NAME

Everhart VH

The **right** adrenal gland measures 0.50 cm at the cranial pole, 0.42 cm at the caudal pole and 1.28 cm in length. No abnormalities are noted with the gland's overall architecture, echogenicity or echotexture. The phrenico-abdominal vein and surrounding vasculature and mesentery are unremarkable.

REFERRING VET

Dr. Betta

Spleen

The spleen is within normal limits in size, architecture, echotexture, and echogenicity. The capsule is smooth. No abnormalities are observed with its vasculature, i.e. congestion and thrombi are not identified.

INVOICE

99362

Liver

There are no obvious signs of hepatomegaly and its borders are smooth and sharp. The liver's echotexture is homogeneous. Pinpoint hyperechoic foci are dispersed haphazardly throughout the parenchyma. The latter may be due to mineralizations. Perivascular cuffing is observed, which may be due to deposition of fat, mineralization and/or mild inflammation. No abnormalities are observed with the hepatic vessels visualized.

The gallbladder wall is within normal limits in thickness and echogenicity. There is no evidence of echogenic material within the GB. No obvious signs of an obstruction are appreciated based on the intrahepatic bile ducts.

Gastrointestinal

A large amount of fluid and gas are present within the lumen of the stomach. The gastric wall is at the high end of the normal reference range with regard to thickness, but remains within normal limits. Loss of the definition of the wall layers is observed in many regions of the stomach, with severe fogging of the mucosa. No obvious abnormalities are observed with its peristalsis.

Diffuse striations and fogging of the mucosa are observed in the duodenum. The wall thickness of the duodenum is within normal limits (0.39 cm). The small intestines are not thickened, and they also show diffuse striations and fogging of the mucosa. A number of loops of jejunum are dilated with fluid. Decreased peristalsis is noted throughout the entire GI tract, i.e., a “to and fro” motion is observed, consistent with a mild to moderate ileus.

Granular, echogenic ingesta is present within the lumen of the small intestine and transverse colon. A moderate amount of soft fecal matter is noted within the colon. The colonic wall is not thickened and mural detail is considered normal.

The mesentery surrounding the GI tract is severely hyperechoic and the anechoic fluid is present in between the loops of bowel.

Pancreas

The right limb of the pancreas is very prominent, with pinpoint and very small punctate hyperechoic foci dispersed haphazardly throughout the parenchyma. The parenchyma is otherwise homogeneous. The pancreas is considered within normal limits, i.e. its prominent appearance is attributed to the severe hyperechogenicity of the omentum and not due to inflammation or pathology. The hyperechoic foci are likely due to fibrosis, fat and possibly mineralization.

The left limb of the pancreas is difficult to evaluate to the gas and fluid in the surrounding GI tract, as well as the severely hyperechoic mesentery, however, the changes are observed in the small portion visualized are similar to those in the right limb.

Other

Lymph nodes

No abnormalities are observed

Abdominal effusion

A mild amount of anechoic fluid is present in between bowel loops, surrounding the spleen, liver lobes, etc., throughout the abdomen, as well as in the pleural cavity.

Mesentery

The mesentery is diffusely hyperechoic throughout the abdomen.

ULTRASONOGRAPHIC FINDINGS

- The striations and other abnormalities observed on Vera’s abdominal ultrasound are most consistent with lymphangiectasia, however, underlying IBD cannot be excluded. The presence of pleural effusion, cough, laboratory results and clinical signs are also typical of lymphangiectasia. Obvious signs of neoplasia are not appreciated. Biopsies of the GI tract are necessary to confirm a

diagnosis of lymphangiectasia, however, patients are not always good candidates for general anesthesia. Biopsies may be obtained by endoscopy, however, they must be as deep as possible, laparoscopy or full thickness biopsies via exploratory laparotomy may also be performed. The mesentery surrounding certain bowel loops is hyperechoic; also suggestive of inflammation.

- The pancreas is considered within normal limits, i.e. its prominent appearance is attributed to the severe hyperechogenicity of the omentum and not due to inflammation or pathology. The hyperechoic foci are likely due to fibrosis, fat and possibly mineralization.
- The mildly enlarged, rounded, “plump” appearance of the cranial pole of the left adrenal gland may be due to adrenal hyperplasia secondary to stress (chronic illness) or development of a benign adenoma. Hyperadrenocorticism (HAC) is considered less likely based on the absence of clinical signs. Sonographic results should be correlated with clinical signs, i.e., further diagnostics are not necessary as Vera is not demonstrating clinical signs of HAC. There is no evidence of a mass.
- The pinpoint hyperechoic foci dispersed throughout the hepatic parenchyma may be due to mineralizations. The perivascular cuffing may be due to deposition of fat, mineralization and/or mild inflammation. There are no signs of neoplasia.
- Very mild degenerative changes of both kidneys, which are suggestive of age related degeneration.

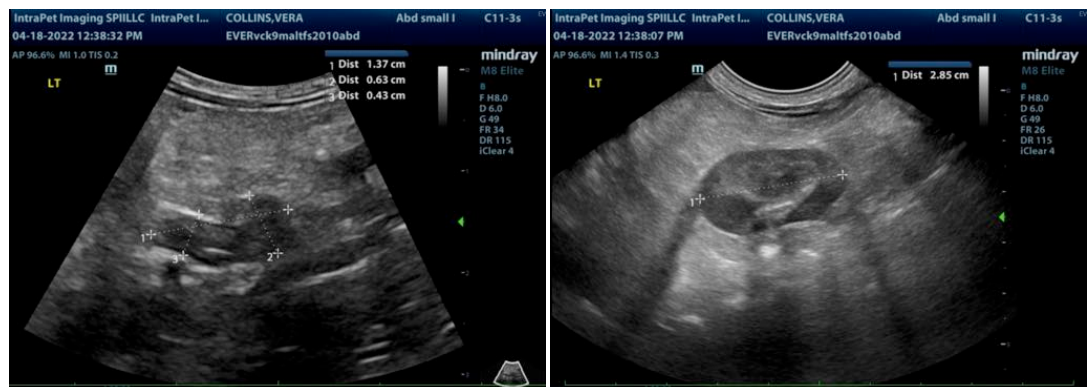
INTERPRETATION OF THE FINDINGS & FURTHER RECOMMENDATIONS

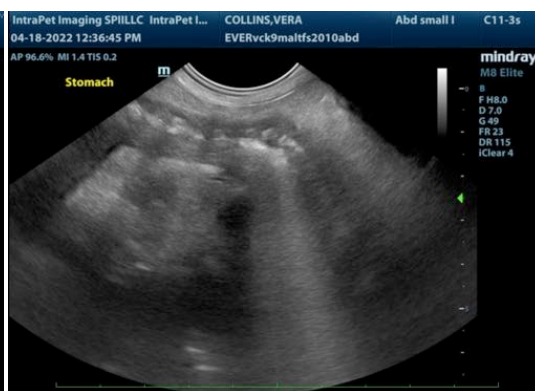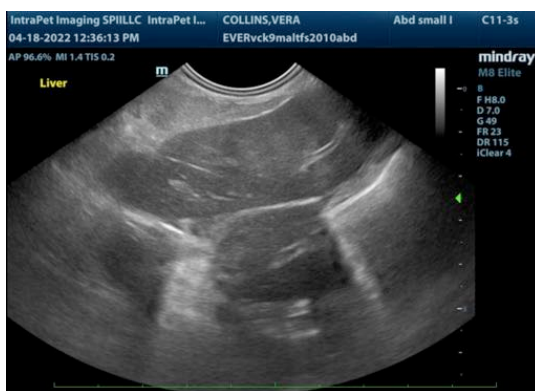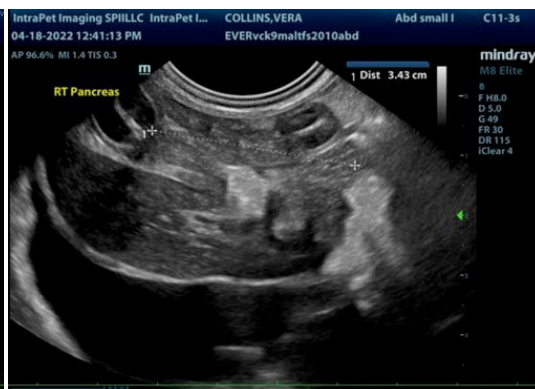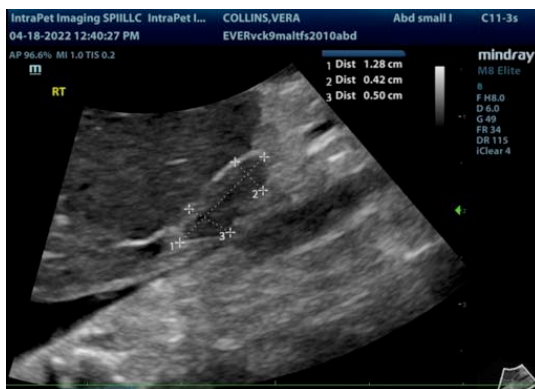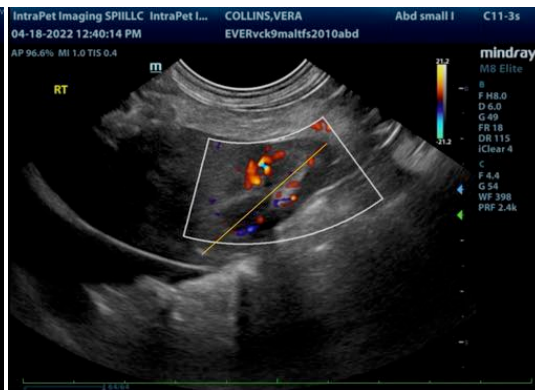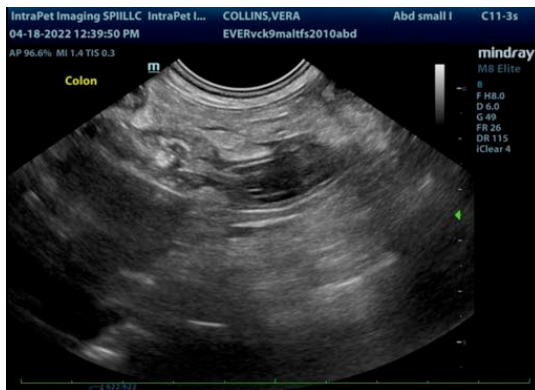A low fat easily digestible diet is recommended, while some patients also require a hypoallergenic diet (+/- hydrolyzed diet).

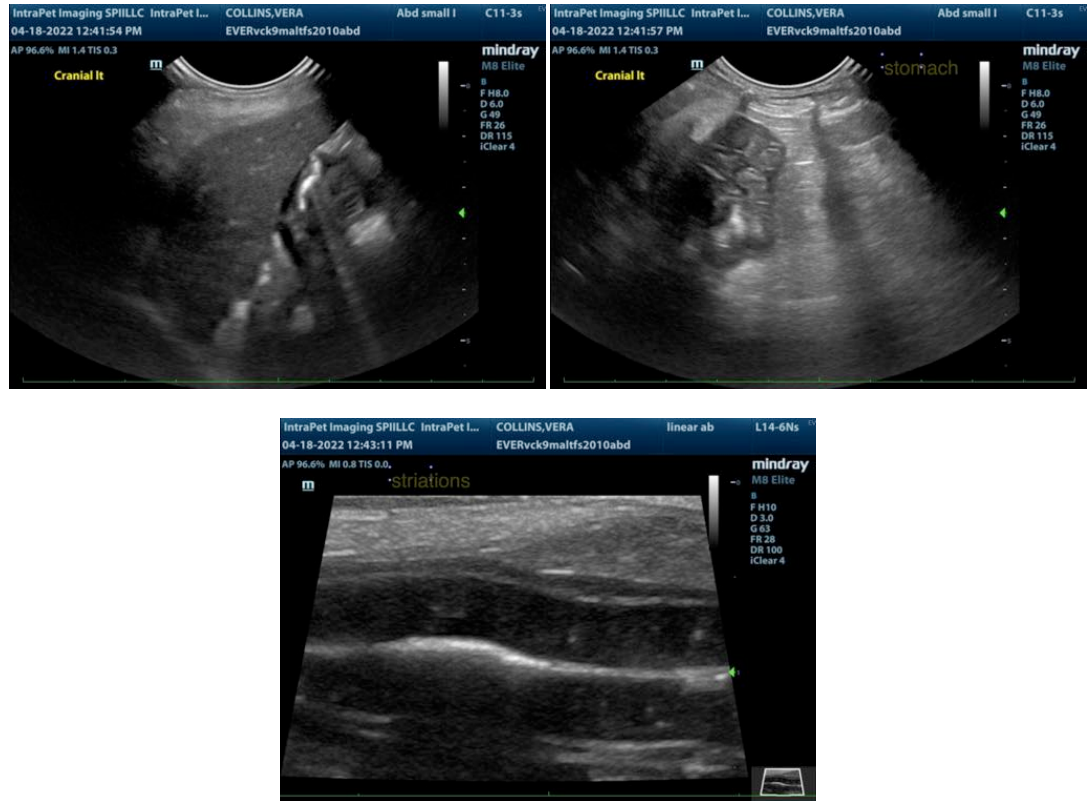
A urinalysis and urine protein: creatinine ratio are recommended as some patients may suffer from concurrent protein losing nephropathies.

If further diagnostics, such as endoscopy and biopsies, are not pursued, empirical treatment for inflammatory bowel disease with corticosteroids are recommended (0.5 - 1 mg/kg/day). Some dogs also benefit from additional psyllium fibre.

The administration of clopidogrel may be considered to help decrease the risk of thromboembolic disease. If an improvement is not observed with the above recommendations, a TLI, serum cobalamin, and folate, are recommended to assess for underlying maldigestion and malabsorption disease.







The information and recommendations provided are based on the images presented by the referring veterinarian. No evaluation can be communicated regarding pathology that was not visible in the image/video clips provided.

Thank you for this referral. If the clinical or image interpretation does not parallel your findings or if I can be of any further assistance please contact me.

Lisa Carioto, DVM, DVSc, Diplomate ACVIM
Lisa.Carioto@sonopath.com